

**Review Article**

# Parkinson's Disease Treatment Using Cell Transplantation

**Sana Khalid**

University of Sargodha, Sargodha, Pakistan

**Email address:**

Sameen.khalid94@gmail.com

**To cite this article:**Sana Khalid. Parkinson's Disease Treatment Using Cell Transplantation. *Rehabilitation Science*. Vol. 5, No. 3, 2020, pp. 24-30.

doi: 10.11648/j.rs.20200503.12

**Received:** April 22, 2020; **Accepted:** May 14, 2020; **Published:** October 27, 2020

---

**Abstract:** The testing of human fetus mesencephalic tissue with intrastriatal transplantation clinically that are rich in dopamine producing neurons. Parkinson's disease patient showed cell transplantation works and in many cases produces impervious improvements. Due to the poor availability of tissues, this method could only be administered in fewer number of patients, and acclimatization was very difficult, leads to immense deflection in operative outcomes. For transplantation, undifferentiated (stem) cells and special (reprogrammed) cells could be availed potentially to emolument dopamine producing neurons. From human embryonic stem cells dopamine producing neurons that will be of the appropriate substantia nigra phenotype can be emolumented in larger numbers and soon will be ready for application in patients. Dopamine producing neurons obtained from pluripotent stem cells of human are supposed to be used for clinical transplantation. In a controlled clinical studies, the present data justifies leading in away with these dopamine producing neurons, that should be tested by choosing desirable patients, anticipation of cells and methods of transplantation.

**Keywords:** Human Fetus Mesencephalic Tissue, Dopamine Producing Neurons, Human Pluripotent Stem Cells, Stem Cells Transplantation, Human Embryonic Stem Cells, Reinnervation, Denervated Striatum

---

## 1. Introduction

Till 1970s, it was believed that the repairing of central nervous system in human beings which was not possible in past, would never possible in future. Two articles with accessible implications had been published in 1979 [1, 2], showed that the intrastriatal grafts of fetal mesencephalic dopamine rich tissues in rats could improve signs of experimental Parkinson's disease [1]. This chronic neurodegenerative disorder, in humans, is characterized by impairment of movement, malfunction and death of vital nerve cells in the brain, called neurons. Motor symptoms can be treated successfully by dopamine producing drugs for many years but as the time passes, these drugs become less effective and could show involuntary movements as side effects. Through transplantation, the animals model raised the possibility of a novel therapeutic approach for Parkinson's disease patients that is based upon replacing the dead dopaminergic neurons by healthy ones.

The first clinical transplantation in parkinson's disease patients was not performed with human fetal mesencephalic

tissue. Autologous adrenal medulla cells were implanted into striatum of four Parkinson's disease patients to provide a local catecholamine source, in the early work that was performed by Olsson, Seiger and Backlund and their co-workers [3, 4], but the beneficial effects were very low. The first intrastriatal implantations of human fetal mesencephalic tissue were performed, in the Parkinson's disease patient, rich in dopaminergic neuroblasts, in 1987. Until late 1990s, clinical studies were continued. In open-label studies and improvements were reported, but there were two double-blind trials demonstrated no significant changes as compare to sham-operated controls [5-8].

Now the clinical cell therapy research for Parkinson's disease has entered into a new, exciting phase and current developments in this field give reason for optimism. There are three main sources of dopaminergic neurons that are being planned for clinical applications.

- 1) Human fetal mesencephalic tissue
- 2) Human embryonic stem cells
- 3) Human induced pluripotent stem cells

How far the clinical trials has reached for these different

types of sources and what are the main challenges, what type of stem cells that are being used for transplantation in animal models of parkinson's disease will be described here.

## 2. Human Fetal Mesencephalic Tissue Transplantation

Transplantation of human mesencephalic tissue had not been developed into a clinical competitive treatment for the Parkinson's disease patients, but the studies had provided us with a valuable acumen for the basic principle of cell therapy in Parkinson's disease patients. The dopaminergic neurons derived from the human fetal dopamine-rich mesencephalic tissue are considered as a gold standard as compared with those dopaminergic neurons which are derived from the other sources towards clinical applications.

The fetal dopaminergic neurons, from a large number of studies, could survive and grow after intrastriatal transplantation into the parkinson's disease patient's brains. F-DOPA uptake in the grafted putamen and histopathological studies had shown the survival of implanted dopaminergic neurons and reinnervation of the striatum had demonstrated with the help of positron emission tomography [9-17]. Four patients were observed with major clinical improvements at 7-10 years after transplantation, in whom F-DOPA uptake was normalized in the grafted putamen from 10-16 years post-surgery showed the normal release of dopamine that was assessed by C-raclopride binding. The fetal mesencephalic grafts reversed the deficiencies in the movement-related cortical activation with a time course parallel that of the clinical improvements, providing the evidences for the functional integration of dopamine into the host neuronal circuitry [20].

In several open-lab trials, the clinical benefits had been observed and for many years the most successful cases with L-DOPA treatment withdrawn [18, 19, 21]. Two patients were subjected to bilateral intrastriatal transplantation of human fetal mesencephalic tissue showed that the human fetal dopaminergic grafts could give rise to clinically comprtitive improvements. After grafting, upto 18 years the motor improvements in these two patients were continued [19, 21]. Due to the restoration of the striatal dopaminergic functions, the improvements in these two patients are evidenced with the help of normalization of putaminal F-DOPA uptake and C-raclopride binding.

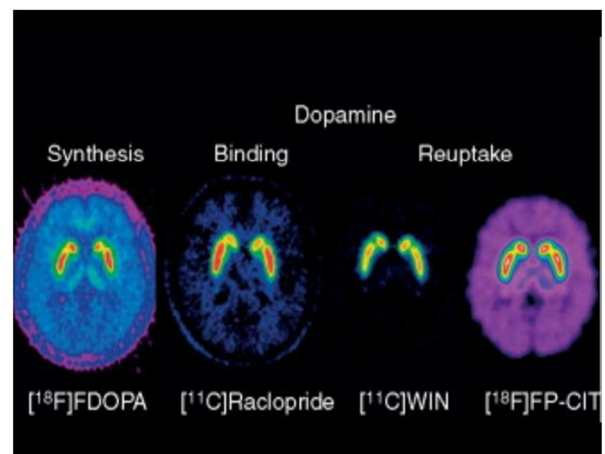
When two sham surgery controlled clinical studies with the bilateral intraputaminial grafts had not confirmed the positive findings in the open-label trials, meanwhile a major problem for the field emerged. But the modest improvements of motor functions at 12 months were demonstrated by Freed et al.[7]. in the first trial. Ma et al. [22] observed clinical benefits and surviving grafts upto four years after transplantation in the open-label follow up of these two patients. At 24 months, parkinson's disease symptoms were not different between the grafted and sham groups in the second trials. During the first 6 to 9 months after transplantations, improvements were

observed [8]. As suggested by the deterioration after withdrawal of immunosuppression at the six months, the function of the graft had been impaired in response to the immune reaction. However, it is unlikely that the advanced parkinson's disease patients with the wide-spread denervation will show successful outcome by intraputaminial transplantation. In less severely disabled patients improvements were seen according to Olanow et al [8].

In humans, the long term survived grafts had been reported to show the minimize expression of the dopamine transporter (DAT) [9, 10, 27], which showed that alpha-synuclein pathology is associated with the synaptic dysfunction. DAT binding, in one such case, incresed after grafting and remained unchanged at fourteen years of post-transplantation. at 4-14 years after transplantation, Hallet et al. narrated the robust DAT expression and normal mitochondrial localization in the grafted dopaminergic neurons in 5 parkinson's disease patients and the degree of graft pathology varied between the patients. Dopaminergic cell therapy is applicable therapeutic option because of;

- 1) Slowness of disease propagation
- 2) Majority of the grafted neurons didn't have effect after a decade
- 3) Improvement is long-term which patients experience

Through the deep-brain stimulation (DBS) of the globus pallidus, dyskinesias which had developed in a subgroup of the grafted patient was treated. Several mechanism in the animal models had been identified which were underlie the grafted-induced dyskinesias, such as post-synaptic supersensitivity that was established by the chronic L-DOPA treatment before the transplantation. Dyskinesias caused by the graft-derived serotonergic hyperinnervation of the striatum after transplantation provided strong evidence during the clinical observations. Three patients who developed moderately severe graft- induced dyskinesias with major clinical improvement, showed that excessive serotonergic innervation in the grafted striatum. Through the administration of 5-HT1A receptor agonist, which dampens transmitter release from serotonergic neurons dyskinesia were abrogated.



**Figure 1.** Human fetal mesencephalic tissue.

Human fetal mesencephalic tissue will be implanted into striatum with the optimized patient selection and tissue preparation procedures, in the ongoing EU-sponsored TRANSEURO clinical trial ([www.transeuro.org.uk](http://www.transeuro.org.uk)). As compared with the previous trials the patients were younger and earlier in their disease and they had not developed any significant L-DOPA induced dyskinesias. Human fetal mesencephalic tissue, however, could be obtained solely in a limited amount and it is difficult to standardize, but it would become very useful in a larger numbers of patients for transplantation. So, new sources of dopaminergic neurons are needed. Dopaminergic neurons' generation from the stem cells or progenitor cells or by reprogramming of somatic cells.

### 3. Stem Cells or Somatic Cells-derived Transplantation of Dopaminergic Neurons

#### 3.1. Conventional Aspects

There are some general aspects that are very important.

- 1) For the generation of transplantable dopaminergic neurons in the parkinson's disease, many potential sources of cells had been proposed, including the pluripotent cells such as embryonic stem cells (ES), neural stem cells, induced pluripotent cells (IPS) and somatic cells which directly convert into the dopaminergic neurons.
- 2) A clinical candidate cell should be of human origin and should have the properties of substantia nigra neurons to be produced and able to perform maximum function [36]. Other types of cells generated from the stem cells or reprogrammed cells need to be known that is serotonin neurons, the number of non-nigral dopaminergic neurons, other non-dopaminergic neurons, undifferentiated precursors/stem cells, glial elements and non-neural cells.
- 3) Methods for cell sorting would most probably be of major importance. Such methods would allow;
  - i. The removal of unwanted cells
  - ii. The enrichment of dopaminergic neurons of the correct mesencephalic phenotype and the optimum stage of differentiation
- 4) The requirements for efficacy should be emphasized for a cell based therapy for parkinson's disease.
- 5) A cell-based therapy to be clinically competitive might give rise to, long lasting major improvement >60-70% of mobility and suppression of dyskinesias and the improvement of symptoms resistant to other modifications and treatments of disease progression.

Dopaminergic neurons derived from stem cells and reprogrammed cells haven't been performed scientifically based clinical studies with transplantation.

#### 3.2. Properties of Candidate Cells

The candidate cells that is used for the transplantation must

have following properties so that the graft might survive

- i. Clinical candidate cell must be of human origin
- ii. Clinical candidate cell must have the properties of a substantia nigra neurons to be able to induce maximum functional recovery
- iii. Clinical candidate cell must be able to survive long term
- iv. Clinical candidate cell must be differentiated into the appropriate neuronal phenotype, that is, nigral dopaminergic neurons after transplantation into parkinson's disease model [37-40].
- v. Ongoing cell division must not be present beyond 1-2 months following transplantation.

### 4. Human Embryonic Stem Cells-derived Dopaminergic Grafts

Graft survival and behavioural improvements were first reported a decade ago, followed the intrastriatal transplantation of human embryonic stem cells derived dopaminergic neurons in a rat parkinson's disease model [41]. Large numbers of dopaminergic neurons of substantia nigra phenotype were shown by the grafts but there were potentially tumorigenic and mitotic undifferentiated neuro-epithelial cells too. In 2011, Kriks and coworkers [42] described a novel protocol, in which human embryonic stem cells were converted efficiently into dopaminergic neurons. Floor plate cells were derived using inhibition of SMAD signalling and the high level of sonic hedgehog in vitro. By the activation of the Wnt signalling, a midbrain floor plate identity was induced, and the cells were differentiated into the dopaminergic precursors. High number of substantia nigra dopaminergic neurons were survived long lasting in rodents after the transplantation of intrastriatal and surprisingly there was no formation of tumors. In larger non-human primate brain, a major portion of striatum could reinnervate. Steinbeck and coworkers [44] demonstrated the motor recovery which is induced by the human embryonic stem cell-derived dopaminergic neurons which was implanted into the dopamine-denervated mouse striatum with the help of electro-physiological, pharmacological and optogenetics approaches. That graft modulated glutamatergic transmission similar to endogenous substantia nigra neurons in the host striatum. Graft of human embryonic stem cell-derived dopaminergic neurons that were implanted into the rat model of parkinson's disease had the capability for axonal growth and long term survival and the functional efficacy as that of the human mesencephalic dopaminergic neurons reported by Grealish and coworkers [45].

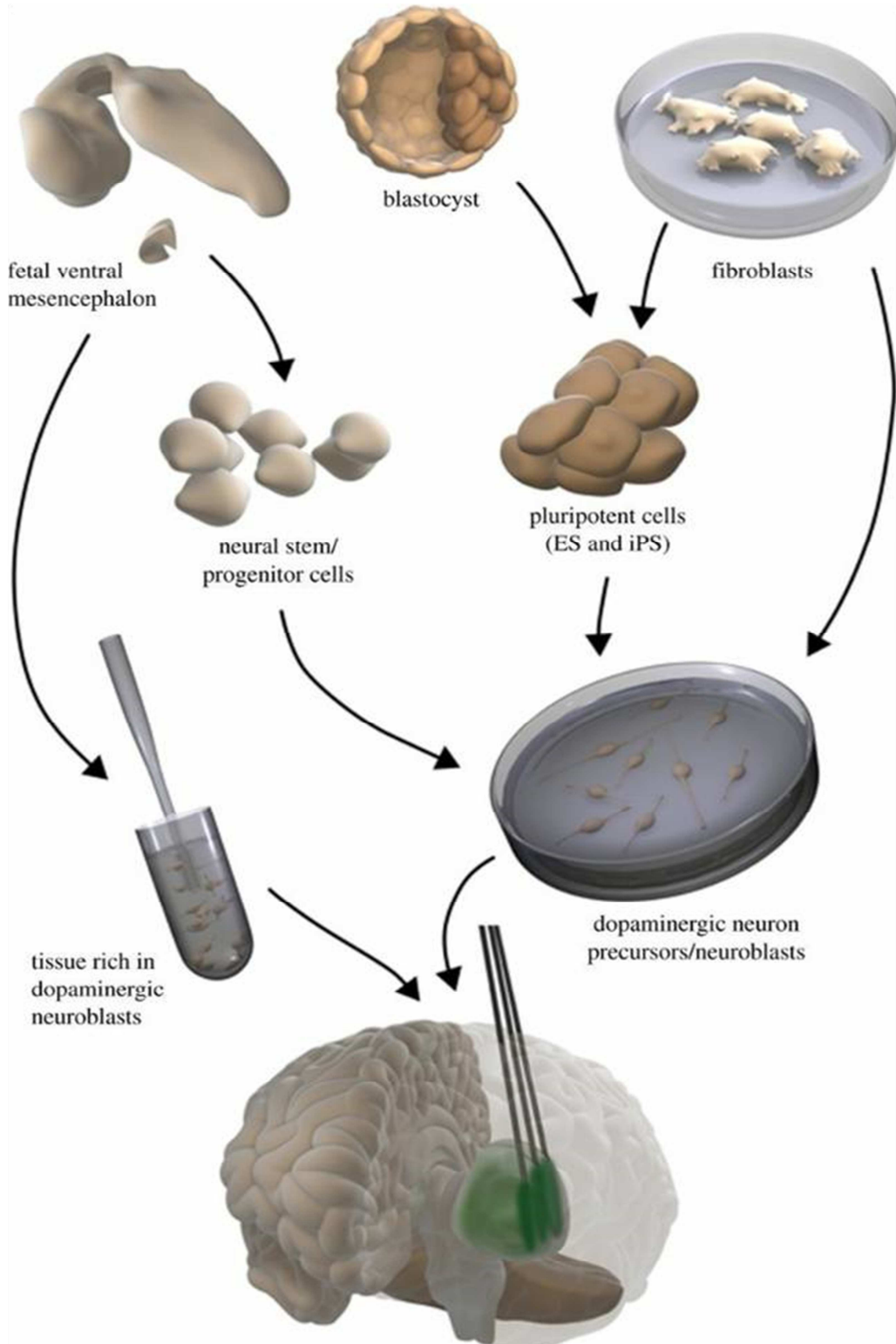
### 5. Advantages

By using the novel protocol, which were developed by Kriks and coworkers, there are many advantages of dopaminergic neurons generation from human embryonic stem cells.

- 1) High numbers of human-derived dopaminergic neurons were produced and the cells survive transplantation.

- 2) Reinnervate the denervate striatum and these neurons were of the correct phenotype that means correct substantia nigra.
- 3) These cells improved the clinically relevant behavioural deficiencies.
- 4) The potency of the human embryonic stem cell-derived

- was comparable with the potency of fetal dopaminergic neurons that had induced major long term symptomatic relief in parkinson's disease patients.
- 5) Human embryonic stem cell-derived dopaminergic neurons has the capacity for axonal growth and long-term survival.



**Figure 2.** Human Somatic Cells-derived Dopaminergic Grafts.

## 6. Human Somatic Cells-derived Dopaminergic Grafts

By the reprogramming of fibroblast through pluripotent stage, called induced pluripotent stem cells (IPS) [38, 46-50], Human dopaminergic neurons are generated. the patients' specific tissues and cells can be produced and used for the transplantation with the help of this technology. Furthermore, the immune reactions and the ethical issues that were associated with human embryonic stem cells can be avoided. There are some potential problems like tumourgenesis and variability of reprogramming. The risk of increased susceptibility in the patient's specific cells of parkinson's disease also existed.

The outgrowth of the extensive axons that were derived from the human induced pluripotent stem cells implanted into the striatum of the denervated rodents had not been convincingly reported and the capability to improve the behavioural deficiencies were incompletely known [38, 46-50]. After implantation of induced pluripotent stem cells derived dopaminergic neurons, the functional recovery had been reported in the striatum of rodents. The density of fibres which were extending from the grafts was low, it was reported that dopamine had not acted through synaptic release but via diffuse volume transmission. There was a question that if it could work in a smaller rodents then would it work in a larger human brain [52]? So the answer is here, recently Hallet et al. [53] described that the autologous induced pluripotent stem cells derived dopaminergic neurons could survive in larger number in non-human primate for 2 years after implantation into striatum and gave rise to reinnervation and improvement in motor functions. Out of three grafted monkeys, the findings were observed only in one and these findings provided preclinical evidences followed by clinical translation of induced pluripotent stem cells derived dopaminergic neurons in parkinson's disease for transplantation.

The generation of functional dopaminergic neurons could also be done by the direct conversion of human fibroblast [54, 55] that was of potential interest in the clinical perspective. Fibroblasts that were obtained from mouse, directly converted into dopaminergic neurons showed survival in transplantation. More extensive axonal outgrowth of dopaminergic neurons derived from mouse fibroblast was implanted into striatum of denervated rat was recently reported [57]. Improvements in stepping and deficiency in apomorphine-induced rotational asymmetry were shown. By pharmacological activation of dopaminergic neurons performance was enhanced. Before clinical application of dopaminergic neurons much work is needed to be done by direct conversion can be considered. Such cells of human origin could survive in larger numbers, give rise to substantial improvement related to behavioural deficiencies in animal parkinson's disease model and show the reinnervation should be demonstrated as a first step.

## 7. Challenges

For successful clinical application of stem cells, there are following three major challenges.

### 7.1. Potency

In an animal parkinson's disease model, the first challenge is the demonstration of potency of the generated dopaminergic neurons after transplantation. In order to induce clinically competitive improvement, the new cells have to be worked efficiently as human fetal dopaminergic neurons. In order to determine the number of cells for transplantation and implants' number in patients, the potency should be known which is including growth capability, axonal growth and dopamine release.

### 7.2. Safety

It is the second major challenge to demonstrate safety in parkinson's disease patients for transplantation. Tumour formation and graft-induced dyskinesias' risk should be minimized that had been observed for fetal mesencephalic tissue implantation. The identity of all cell types in the implants is very important to be determined. For the elimination of tumour forming cells, cell sorting is used.

### 7.3. Selection

The third major challenge in the clinical trial is the selection of most suitable patient. Patient must have in a relatively advance stage of disease but there are chances of therapeutic benefits too.

## 8. Clinical Trials

For treatment of parkinson's disease stem cell-based therapies are moving towards the clinical trials. In October 2016 [59], using pluripotent stem cells to treat parkinson's disease was approved. In many centres, clinical trials of stem cell-based therapies are approaching. In this clinical trials which was done in 2014, implantation of human fetal mesencephalic tissue showed proof-of-principle for cell replacement strategy. now in clinical application, human embryonic stem cells and induced pluripotent stem cells are being used. Using optimal patient selection, transplantation methods and cell preparation, development of useful treatment for parkinson's disease are done in a well controlled clinical studies.

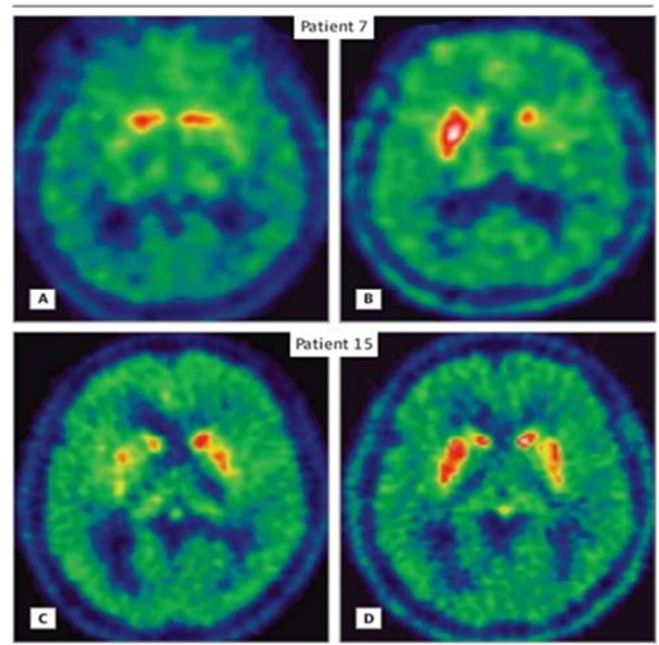
Two patients (patients 7 and 15) were taken that received intrastriatal transplantation of human fetal ventral mesencephalic tissue that were rich in dopaminergic neuroblasts as experimental treatment for parkinson's disease [60, 61]. Both of them, throughout their disease course experienced excellent responses to levodopa treatment. For treating putamen of patient 7 and putamen and caudate nucleus of patient 15, a magnetic resonance imaging guided



stereotactic method was used, at the age of 49 and 54. By using unified parkinson's disease rating scale (UPDRS),

	Patient 7	Patient 15
Sex/handedness	Male/right-handed	Male/right-handed
Age at onset, y/disease duration, y	39/10	42/12
Disease phenotype	Akinetic rigid	Akinetic rigid
Mean UPDRS part III score in "practically defined off" /best "on" conditions (range, 0-108) <sup>a</sup>	38/11	23/3.4
PD-related medication	Levodopa, 300 mg/d; pergolide, 1.5 mg/d; selegiline, 10 mg/d; amantadine, 300 mg/d	Levodopa, 900 mg/d; pergolide, 1.5 mg/d; amantadine, 200 mg/d; 2-3 apomorphine injections (5 mg/0.5 mL)/d
Date/location of transplantation/No. of trajectories	Apr 1993/left putamen/5; Sep 1994 /right putamen/5	Nov 1996/left putamen + caudate/5 + 2; Nov 1996/right putamen + caudate/5 + 2
No. per side/age of donors, wk postconception (embryos)	5/6-8	4/6-9
Transplantation preparation	Fresh tissue; cell suspension	Fresh tissue; cell suspension
Immunosuppression	Cyclosporin, azathioprine, prednisolone (2 d before to 48 mo after grafting)	Cyclosporin, azathioprine, prednisolone (2 d before to 20 mo after grafting)

motor function was evaluated. Preoperative and postoperative clinical scores were compared with current scoring as shown.



**Figure 3.** intraoperative images of human fetal ventral mesencephalic tissue transplantation.

## 9. Results

Following transplantation patient no. 7 experienced motor improvements, which emerged over the course of four years. After first transplantation, 26 months later the patient stopped levodopa treatment. All dopaminergic agents had been withdrawn while the patient's motor status continued to improve by the fifth postoperative year. The patient demonstrated sustained motor improvement at the last assessment of 18 years postgrafting. No fluctuation in motor examination and free of any pharmacological dopamine replacement therapy was reported. Patient's swallowing was normal and falls and freeze had not emerged as a problem and all the activities of daily living was continued as independently.

In patient no. 15, there was no improvement shown during first two years after transplantation. However, motor function became evident from the fourth year after grafting, at the end of which the patient was able to stop all dopaminergic medications. Motor improvements were preserved after transplantation of 15 years of assessment. The patient had minor rigidity, bradykinesia, normal gait and intact postural reflexes during motor examination. The patient was free of any dopaminergic medications [62].

In the basal ganglia, dopaminergic reinnervation was normal. Anyhow non-motor symptoms such as fatigue, anxiety, mood swings and sleep problems were developed in patients. There are several therapeutic options for parkinson's disease patients which are in advance stage. In the field of cell therapy for parkinson's disease, there has been a steady scientific progress.

## References

- [1] Brkud A, Stenevi U. 1979 Reconstructyion of the nigrostriatal dopamine pathway by intracerebral nigral transplants. *Brain Res* 177, 55-560.
- [2] Perlow MJ, Freed WJ, Hoffer BJ, Seiger A, Olson L, Wyatt RJ. 1979 Brain grafts reduce motor abnormalities produced by destruction of nigrostriatal dopamine system. *Science* 204, 643-647.
- [3] Backlund EO, Granberg PO, Hamberger B, Knutsson E, Martensson A, Swdval G, Geiger A, Olson L 1985 transplantation of adrenal medullary tissue to striatum in parkinsonism. First clinical trials. *J. Neurosurg.* 62, 169-173.
- [4] Lindvall O, Backlund EO, Frade L, Sedvall G, Freedman R, Hoffer B, Nobin a, seiger a, olson l.1987 Transplantation in parkinson's disease: two major cases of adrenal medullary grafts to the putamen. *Ann. neurol.* 22, 457-468.
- [5] Lindvall o.2013 developing dopaminergic cell therapy for parkinson's disease-give up or move forward? *Mov. Disord.* 28, 268-273.
- [6] (2015) Press Release International Stem Cell Corporation Receives Authorization to Initiate Phase I/IIa Clinical Trial of ISC-hpNSC for the Treatment of Parkinson's Disease: <http://www.internationalstemcell.com/profiles/investor/ResLibraryView.asp?ResLibraryID=80072&GoTopage=1&Category=958&BzID=1468&G=583>
- [7] (2015) Press release, International Stem Cell Corporation- on. <http://www.internationalstemcell.com/profiles/investor/NewsPrint.asp?b=1468&ID=80129&m=r1&pop=1&Nav=0&g=583&t=1983>.

- [8] Brundin P, Strecker R. E., Clarke D. J., Widner H., Nilsson O. G., Astedt B, Lindvall O., & Bjorklund A (1988) Can human fetal dopamine neuron grafts provide a therapy for Parkinson's disease? *Prog Brain Res*, 78, 441-448.
- [9] Brundin P, Barker RA, & Parmar M (2010) Neural grafting in Parkinson's disease Problems and possibilities. *Prog Brain Res*, 184, 265-294. [5] Thompson L, & Bjorklund A (2012) Survival, differentiation, and connectivity of ventral mesencephalic dopamine neurons following transplantation. *Prog Brain Res*, 200, 61-95.
- [10] Barker RA, Drouin-Ouellet J, & Parmar M (2015) Cell-based therapies for Parkinson disease-past insights and future potential. *Nat Rev Neurol*, 11, 492-503.
- [11] Freed CR, Greene PE, Breeze RE, Tsai WY, DuMouchel W, KaoR, Dillon S., Winfield H., Culver S., Trojanowski J. Q., Eidelberg D., & FahnS (2001) Transplantation of embryonic dopamine neurons for severe Parkinson's disease. *N Engl J Med*, 344, 710-719.
- [12] Olanow CW, Goetz CG, Kordower JH, Stoessl AJ, Sossi V, Brin MF, Shannon KM, Nauert GM, Perl DP, Godbold J, & Freeman TB (2003) A double-blind controlled trial of bilateral fetal nigral transplantation in Parkinson's disease. *Ann Neurol*, 54, 403-414.