

# Laparoscopy in Simple and Complicated Appendicitis: How Does It Differ

Abdelnaser Zaid<sup>1,2</sup>, Mohammed Kottb<sup>2</sup>, Emad Hokkam<sup>1,3,\*</sup>, Aly Saber<sup>4</sup>

<sup>1</sup>Department of Surgery, Faculty of Medicine, Jazan University, Jazan, KSA

<sup>2</sup>Department of Surgery, Faculty of Medicine, Assiut University, Assiut, Egypt

<sup>3</sup>Department of Surgery, Faculty of Medicine, Suez Canal University, Ismailia, Egypt

<sup>4</sup>Department of Surgery, Port-Fouad General Hospital, Port-Said, Egypt

## Email address:

ehokkam@gmail.com (E. Hokkam), aly Saber54@gmail.com (A. Saber)

\*Corresponding author

## To cite this article:

Abdelnaser Zaid, Mohammed Kottb, Emad Hokkam, Aly Saber. Laparoscopy in Simple and Complicated Appendicitis: How Does It Differ *Journal of Surgery*. Special Issue: Minimally Invasive and Minimally Access Surgery. Vol. 5, No. 3-1, 2017, pp. 23-27.

doi: 10.11648/j.js.s.2017050301.15

**Received:** January 20, 2017; **Accepted:** January 21, 2017; **Published:** February 18, 2017

---

**Abstract:** *Introduction:* laparoscopic appendectomy (LA) has been established as a surgical technique in the management of acute appendicitis in several studies. Although LA is considered safe and effective in acute non-complicated cases, the technique is not gaining the same widespread acceptance in the complicated cases. The considerable high rate of conversion into open surgery and safety of the procedure in complicated cases makes the outcome somewhat different from that of the non-complicated cases. This study was designed to compare the outcome of the LA in both simple and complicated acute appendicitis. *Methods:* The study included ninety patients who were above 18 years of age with either acute simple or acute complicated appendicitis. There are divided into two groups (G1 & G2). G1 included complicated cases while G2 included simple cases. LA was performed to all patients. The outcome of the procedure in terms of rate of conversion to open surgery, operation time, hospital stay, time of return to work and the complications rate was compared between both groups. *Results:* G1 included 40 patients (44%) while G2 included 50 patients (56%). The operative time was significantly longer in G1 than G2 ( $115 \pm 18.6$  vs  $65 \pm 10.4$ ) ( $P=0.02$ ). Conversion to open surgery occurred in 11 patients (27.5%) of G1 and in 4 patients (8%) of G2 ( $P=0.01$ ). The main causes of conversion were difficult skeletonization of the appendix and inability to control bleeding from non-visualized source. The overall length of hospital stay was significantly higher in G1 patients ( $P=0.02$ ) while the time needed to return to work was statistically insignificant between both groups ( $P=0.12$ ). The incidence of complications was greater in G1 (8/40) as compared to G2 (2/50) ( $P=0.001$ ). There were no mortalities and no patients required re-operation in either group. *Conclusion:* LA is feasible and advantageous in both simple and complicated appendicitis. However; great caution and high level of experience are need in complicated cases because of its relatively high rates of complication and conversion to open procedure.

**Keywords:** Laparoscopy, Complicated Appendicitis, Appendectomy

---

## 1. Introduction

Senn was the first to report appendectomy for acute appendicitis in 1889. Since that time; conventional surgical appendectomy is considered the standard management for acute appendicitis. It is highly effective procedure with low mortality and mortality rates [1]. The first LA was performed by Kurt Semm, a German gynecologist, in 1983. The

indications for LA follow the same principles that are followed for open surgery. LA is a useful technique to reduce the hospital stay, and to minimize the complication rate. It enables patients to return to their normal activity as early as possible [2, 3]. The efficacy and safety of LA have been proved and established; it is neither experimental nor investigational. Most cases of acute appendicitis can be managed laparoscopically. LA is more advantageous in certain

circumstances; in young women with lower abdominal pain of uncertain etiology, in obese patients, or in young athletic individuals. However, the role of laparoscopy in complicated cases is more debatable; more controversial and has not yet gain the universal acceptance [4, 5].

Surgeons who prefer the conventional surgery in complicated appendicitis claim that gangrene and perforation of the appendix are associated with high rate of postoperative complications and this is sufficient to consider it a relative contraindication to LA [6-8] while surgeons who advocate the LA in complicated appendicitis claim that it is a feasible procedure with accepted rate of complications and results in better outcome than the open method [9-11]. Nowadays; the choice of operative technique depends mainly on the discretion of the operating surgeon [6].

The aim of this study is to compare the feasibility, safety and role of LA in both simple and complicated cases of acute appendicitis as represented by the rate of conversion to the open procedure, the operative time, the length of hospital stay, time of return to work and the complications rate.

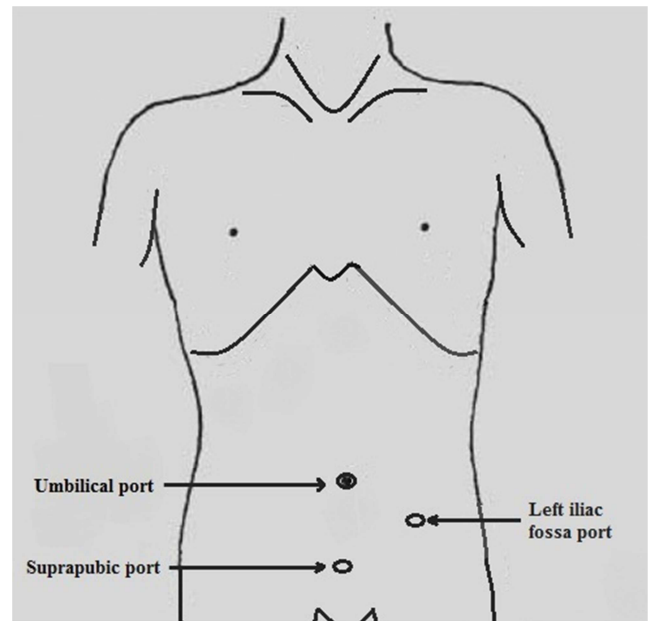
## 2. Patients and Methods

Patients admitted to surgery department at Assiut University Hospital, Egypt and King Fahd Central Hospital, Jazan, Saudia Arabia with a decision to operate for suspected acute appendicitis during the period from November 2015 to October 2016 were enrolled in the study. Inclusion criteria were patients diagnosed with acute appendicitis either simple or complicated, age above 18 years, patients admitted for interval appendectomy 3 to 6 months after their conservative treatment, and medical fitness for general anesthesia and LA. Patients underwent previous abdominal surgeries, bleeding diathesis, patients with renal or hepatic impairment, patients with cardiopulmonary or cerebrovascular disorders and pregnant females were excluded from the study.

Simple acute appendicitis is defined as an inflamed appendix that is apparently intact, without gangrene, suppuration, or abscess formation [12] while complicated acute appendicitis is considered when there is perforated appendix, gangrenous appendix, empyema, appendicular mass, abscess formation, or peritonitis [13]. Clinical, laboratory, and radiological evaluation were performed to all included patients. An informed written consent was obtained from each patient stressing that a decision to convert to open surgery may be taken. Preoperative third generation cephalosporin was given intravenously one hour before operation for prophylaxis.

The technique of LA was unified for both simple and complicated appendicitis. General anesthesia with endotracheal intubation was used in all cases. LA was performed using a modified three-port technique (figure 1). A 10 mm port was created at the umbilicus for a 30° camera. One 5 mm port was created at the suprapubic area and another 10 mm port was created at the left iliac fossa. After induction of pneumo-peritoneum, laparoscopic exploration of the

abdomen and confirmation of the diagnosis was achieved.



*Figure 1. Modified three-port technique for laparoscopic appendectomy.*

Patients were positioned in Trendelenburg position with left lateral tilt to allow better visualization of the operative field. The cecum was pulled upward toward the liver and the appendix was grasped at its tip and held in an upward position. The surrounding bowel loops and omentum were gently moved away. A mesenteric window very close to the base of the appendix was created. The appendicular artery and its fine branches were controlled using electrocautery. The appendix was gently skeletonized with Maryland forceps or atraumatic graspers.

Two endoloops were placed around the appendicular base and another extracorporeal knot ligature of 2-0 Vicryl was placed 1 cm away. The appendix was then cut with a scissor between the 2 distal ligatures and removed through the 10 mm port after being placed inside a sterilized bag. After suction & irrigation, the area of the cecum was checked for hemostasis and any possible bowel injury. Drains were left beside the caecum and pelvis in cases of perforated appendicitis. The fascia of the 10 mm trocar sites were closed using 2/0 Vicryl sutures and the skin of all sites were then closed. Postoperatively, early ambulation and early enteral feeding were encouraged. Opiate analgesia was given once. Non steroidal anti-inflammatory injections were given as needed. Follow up of patients in the outpatient's clinic was made for average two weeks.

Evaluated variables were preoperative as age and sex, intraoperative as operating time, intraoperative diagnosis, intraoperative complications and the rate of conversion to open surgery and postoperative as length of hospital stay, postoperative complications and the time needed to return to work. Data analysis was performed using SPSS software (version 22). Quantitative data were expressed as mean and standard deviation, and qualitative data were expressed as number & percentage of the total. Student t test was used to

test the significance of the difference between quantitative variable while chi square test was used for qualitative variables.

### 3. Results

Ninety patients were included in the study. They were 49 females and 41 males with a mean age of  $26 \pm 8.8$  years. Seventy-nine patients were between 20-49 years old while 11 patients were  $\geq 50$  years old (Table 1 & 2). Intraoperatively; the patients were classified into two groups. The first group (G1) included 40 patients (44%) with complicated acute appendicitis while the second group (G2) included 50 patients (56%) with simple non complicated acute appendicitis.

Age distribution was comparable between both groups with no significant differences ( $P=0.1$ ), however, males was significantly higher in G1 ( $P=0.03$ ). The operative time in G1 ranged from 70-220 minutes ( $115 \pm 18.6$ ) while in G2 it ranged from 45-120 min ( $65 \pm 10.4$ ). This difference was statistically significant ( $P=0.02$ ). LA was successfully completed in 75 patients (83.3%) in both groups. The conversion to open procedure occurred in 15 patients (16.7%). It was performed in 11 patients (27.5%) of G1 and in 4 patients (8%) of G2. The conversion rate was significantly higher in G1 ( $P=0.01$ ) (Table 2).

**Table 1.** Distribution of the patients in both groups according to their age.

Age group (years)	G1	G2	Total
20-29	19 (47.5%)	21 (42%)	40 (44.4%)
30-39	9 (22.5%)	17 (34%)	26 (28.8%)
40-49	5 (12.5%)	8 (16%)	13 (14.4%)
$\geq 50$	7 (17.5%)	4 (8%)	11 (12.2%)
Total	40 (100%)	50 (100%)	90 (100%)

**Table 2.** Perioperative data of the patients in both groups.

		(G1) n= 40	(G2) n= 50	P value
Sex	Males	25 (60.9 %)	16 (39%)	0.03*
	Females	9 (18.3%)	40 (81.6%)	
	Range	20-66	22-48	
Age	Mean	28	22	0.1 (NS)
	SD	+ 8.2	+ 6.8	
	Range	70-220	45-120	
Operation time (minutes)	Mean	115	65	0.02*
	SD	+ 18.6	+ 10.4	
	Range	70-220	45-120	
Converted cases	Total	11 (27.5%)	4 (8%)	0.01*
	Range	3-17	2-7	
Length of hospital stay (days)	Mean	6.8	2.8	0.02*
	SD	+ 3.7	+ 2.6	
	Range	16-30	14-28	
Time to return to work (days)	Mean	24	19	0.12 (NS)
	SD	+ 5.3	+ 3.8	

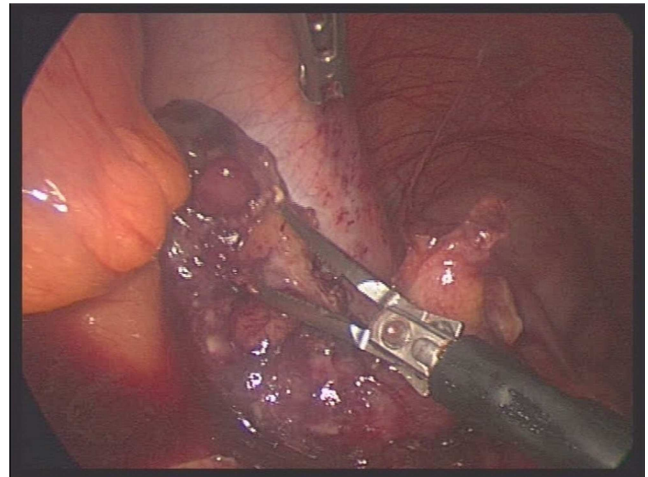
SD: Standard deviation

\* Statistically significant difference (p-value  $< 0.05$ ).

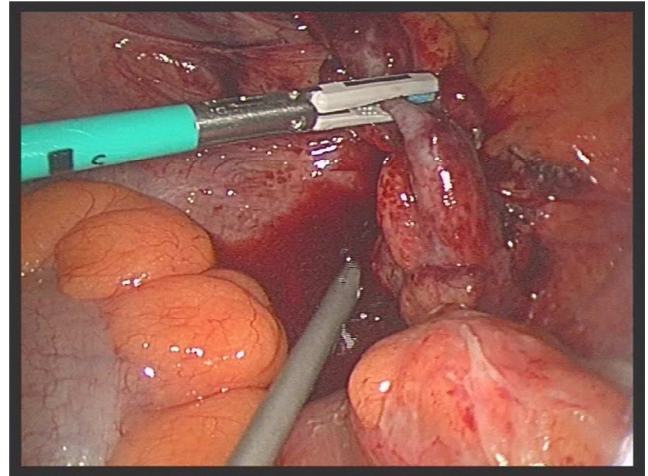
NS: No statistically significant difference (p-value  $> 0.05$ ).

In G1; the causes of conversion included inability to mobilize the appendix from the colon with high retrocolic appendicular mass (2 patients), a gangrenous perforated

appendix at the base very close to the cecal wall making it difficult to close the base securely (3 patients) (Figure 2), difficult dissection of a small fibrotic or porcelain like appendix that is adherent to the medial cecal wall behind the terminal ileum mesentery (2 patients), severely inflamed terminal ileum adherent to appendix and liable for perforation (2 patients), inability to control bleeding from the operative field with non-visualized source (2 patients) (Figure 3). In G2; the causes of conversion included suspected cecal mass (2 patients), difficult dissection of retroileal appendix (1 patient) and a high subserous retrocolic appendix (1 patient).



**Figure 2.** Acute gangrenous appendicitis.



**Figure 3.** Bleeding from non-visualized source.

Drains were inserted in 11 patients in G1. They were removed after a mean period of  $4.5 \pm 2.6$  days (range 3-7 days) after cessation of discharge. No drains were needed in G2 patients. The overall length of hospital stay was significantly higher in G1 ( $P=0.02$ ) while the time needed to return to work was statistically insignificant between both groups ( $P=0.12$ ) (Table 2). The incidence of complications was 10/90 (11.1%). It was greater in G1 (8/40) as compared to G2 (2/50). The difference was statistically significant ( $P = 0.001$ ). Table 3 summarizes the types of complications and the incidence of each one among G1 & G2.

**Table 3.** Rate of complications in G1 & G2.

Complication	G1 (n=40)	G2 (n=50)
Bleeding from operative field	2	1
Postoperative ileus	2	-
Trocar site infections	3	1
Deep venous thrombosis	1	-
Total	8/40 (20%)	2/50 (4%)

Intraoperative complications were managed successfully after conversion into open surgery with no adverse consequences in both groups. Trocar site infections were treated conservatively with broad spectrum antibiotics in both groups. Patients with ileus and DVT were also treated conservatively with bed rest and medical remedies. There were no mortalities and no patients required re-exploration or further surgical interventions in either group.

## 4. Discussion

Although appendectomy is the gold standard management for acute appendicitis, the relative advantages of laparoscopic and open procedures continue to engage in a dynamic argument. Many randomized trials and meta-analysis studies have confirmed the advantages of LA in acute simple appendicitis [14, 15]. However; in complicated cases, controversy still exists as to whether its advantages justify its priority over the traditional open procedure, which historically has had relatively low morbidity and mortality rates [16].

The operating time of LA has always been a major interest in many studies. Varlet *et al.* [17], reported an average of 40 minutes; however, he excluded patients of complicated appendicitis. Hellberg *et al.* [15] reported an average of 60 minutes in acute simple appendicitis. Other researchers reported figures ranging from 71 minutes in older studies to 55 minutes in more recent ones [3, 4, 16]. In the current study, the mean operation time in G2 was 65 min which was comparable to reported literature [15, 17]. However, the mean operation time in G1 was significantly longer than that of G2. Meguerditchian *et al.* [1], and Lintula *et al.* [18], reported operation times of 45.7 and 63 mins respectively in complicated appendicitis which is shorter than reported by us. The differences in the operating time throughout the literature may be attributed to the varieties in the different laparoscopic approaches as well as familiarity of the surgeons and operation room staff with the minimally invasive techniques [6, 13].

In the present study, conversion into open procedure was mainly due to difficult dissection rather than occurrence of intraoperative complications. The conversion rate was significantly higher in patients with complicated appendicitis. However; Meguerditchian *et al.* [1], reported the same conversion rate in both simple and complicated cases while Lintula *et al.* [18], didn't perform any conversions in his complicated cases. On the other hand, Hellberg *et al.* [15], reported a 12% conversion rate with simple appendicitis. The discrepancy of conversion rate in complicated appendicitis among many researches may be due to absence of unified definition of the complicated cases and each researcher

depends on its own selection criteria [19].

The advantages of LA in patients of G1 were less apparent than in patients of G2 as they had a significantly longer operation time, longer duration of hospital stay and higher rate of conversion although the time of return to work activities was comparable in both groups. This was consistent with Tang *et al.* [20] and Pirro & Berdah [21] who reported that the advantages of LA are lost in complicated appendicitis while Ali *et al.* [2] and Thomson *et al.* [22] found no difference between the two groups.

When reviewing the literature, we found that complications associated with LA are ranging from simple wound infection to uncontrollable bleeding and visceral injury [23]. There is no clear consensus as regarding the safety of LA in cases of complicated appendicitis [24]. In our study, the incidence of complications was significantly higher in G1 (complicated cases) as compared to G2 (simple cases). In the same context, Horwitz *et al.* [25] has reported a 3-fold increase in the risk for postoperative intraabdominal abscesses after LA for complicated appendicitis. On the other hand, other studies have shown that LA is safe and advantageous even in complicated cases. It seems that with progression of the learning curve, the complications rates tend to decline [4, 19, 22].

Strangely, in our study, we didn't encounter the complication of intraabdominal abscesses as found in most of studies [26-28], probably because we had a relatively high rate of conversion in addition to the liberal use of peritoneal drains in complicated cases. In the current study; placement of the drains in complicated cases has proved its efficacy in decreasing the complications rate. However, Schlottmann *et al.* [29] didn't agree with us in the necessity of abdominal drainage in such cases.

We recorded 3 cases of intraoperative bleeding. We might agree with Horvath *et al.* [16], in that loss of the tactile sensation resulted in bleeding from friable tissues. The rest of complications in this study including trocar site infections, postoperative ileus and DVT could be regarded as general surgical complications not specific to the laparoscopic procedure. Markides and his colleagues [19] conducted a large systematic review and meta-analysis for LA in adults with complicated appendicitis. They reviewed twelve researches and included that morbidity rates have varied from 10% to 45%; thus, our complication rate was well in the range of previous studies.

## 5. Conclusion

LA is a feasible, effective and minimally invasive therapeutic technique for both simple and complicated appendicitis. However, dissection of severely inflamed appendix is somewhat difficult with the laparoscopic instrumentation leading to slightly higher rate of complications when compared with non-complicated cases. Therefore, surgeon's experience, meticulous dissection and good surgical judgment are advised, especially when dealing with complicated cases.



## References

- [1] Meguerditchian AN, Prasil P, Cloutier R, Leclerc S, Péloquin J, Roy G. Laparoscopic appendectomy in children: A favorable alternative in simple and complicated appendicitis. *J Pediatr Surg.* 2002 May; 37 (5): 695-8.
- [2] Ali DN, Ali QL, Hussain LZ. Laparoscopic and open appendectomy. *Professional Med J.* 2016; 23 (11): 1305-10.
- [3] Mendoza-Sagaon M, Hamitaga F, Hurni Y, Voumard N. Appendix extraction after laparoscopic appendectomy in children: An easy, safe, and inexpensive technique. *J Pediatr Surg.* 2016 Feb; 51 (2): 341-3.
- [4] Werkgartner G, Cerwenka H, El Shabrawi A, Bacher H, Hauser H, Mischinger HJ, Wagner M, Wagner D. Laparoscopic versus open appendectomy for complicated appendicitis in high risk patients. *Int J Colorectal Dis.* 2015 Mar; 30 (3): 397-401.
- [5] Agresta F, De Simone P, Michelet I and Bedin N. Laparoscopic appendectomy: why it should be done. *JSLs.* 2003; 7 (4): 347-52.
- [6] Golub, R., Siddiqui, F., and Pohl, D. Laparoscopic versus open appendectomy: a metaanalysis. *J Am Coll Surg.* 1998; 186: 545-53.
- [7] Sauerland S, Jaschinski T, Neugebauer EA. Laparoscopic versus open surgery for suspected appendicitis. *Cochrane Database Syst Rev.* 2010 Oct 6; (10): CD001546.
- [8] Pokala, N., Sadhasivam, S., Kiran, R. P., and Parithivel, V. Complicated appendicitis-is the laparoscopic approach appropriate? A comparative study with the open approach: outcome in a community hospital setting. *Am Surg.* 2007 Aug; 73 (8): 737-41.
- [9] Cueto J, D'Allemagne B, Vázquez-Frias JA, Gomez S, Delgado F, Trullenque L, et al. Morbidity of laparoscopic surgery for complicated appendicitis: an international study. *Surg Endosc.* 2006 May; 20 (5): 717-20.
- [10] Novitsky, Y. W., Litwin, D. E. M., and Callery, M. P. The net immunologic advantage of laparoscopic surgery. *Surg Endosc.* 2004; 18: 1411-19.
- [11] Garg CP, Vaidya BB, Chengalath MM. Efficacy of laparoscopy in complicated appendicitis. *Int J Surg.* 2009 Jun; 7 (3): 250-2.
- [12] Hirano ES, Pereira BM, Bustorff-Silva JM, Rizoli S, Nascimento B Jr, Fraga GP. Not complicated acute appendicitis in adults: clinical or surgical treatment? *Rev Col Bras Cir.* 2012 Apr; 39 (2): 159-64.
- [13] Pittman-Waller VA, Myers JG, Stewart RM, Dent DL, Page CP, Gray GA, Pruitt BA Jr, Root HD. Appendicitis: why so complicated? Analysis of 5755 consecutive appendectomies. *Am Surg.* 2000 Jun; 66 (6): 548-54.
- [14] Pedersen AG, Petersen OB and Wara P. Randomised clinical trial of laparoscopic versus open appendectomy. *Br J Surg* 2001; 88: 200-5.
- [15] Hellberg A, Rudberg C, Kullman E, Enochsson L, Fenyo G, Graffner H, et al. prospective randomized multicenter study of laparoscopic versus open appendectomy. *Br J Surg.* 1999 Jan; 86 (1): 48-53.
- [16] Horvath P, Lange J, Bachmann R, Struller F, Königsrainer A, Zdichavsky M. Comparison of clinical outcome of laparoscopic versus open appendectomy for complicated appendicitis. *Surg Endosc.* 2017 Jan; 31 (1): 199-205.
- [17] Varlet F, Tardieu D, Limonne B, Metafiot H, Chavrier Y. Laparoscopic versus open appendectomy in children-comparative study of 403 cases. *Eur J Pediatr Surg.* 1994 Dec; 4 (6): 333-7.
- [18] Lintula H, Kokki H, Vanamo K, Antila P, Eskelinen M. Laparoscopy in children with complicated appendicitis. *J Pediatr Surg.* 2002 Sep; 37 (9): 1317-20.
- [19] Markides G, Subar D, Riyad K. Laparoscopic versus open appendectomy in adults with complicated appendicitis: systematic review and meta-analysis. *World J Surg.* 2010 Sep; 34 (9): 2026-40.
- [20] Tang E, Ortega AE, Anthone GJ, Beart RW Jr. Intraabdominal abscesses following laparoscopic and open appendectomies. *Surg Endosc.* 1996 Mar; 10 (3): 327-8.
- [21] Pirro N, Berdah SV. Appendicitis: yes or no to laparoscopic approach? *J Chir (Paris).* 2006 May-Jun; 143 (3): 155-9.
- [22] Thomson JE, Kruger D, Jann-Kruger C, Kiss A, Omoshoro-Jones JA, Luvhengo T, Brand M. Laparoscopic versus open surgery for complicated appendicitis: a randomized controlled trial to prove safety. *Surg Endosc.* 2015 Jul; 29 (7): 2027-32.
- [23] Perugini RA, Callery MP. Complications of laparoscopic surgery. In: Holzheimer RG, Mannick JA, editors. *Surgical Treatment: Evidence-Based and Problem-Oriented.* Munich: Zuckschwerdt; 2001.
- [24] Mohamed AA, Mahran KM. Laparoscopic appendectomy in complicated appendicitis: Is it safe? *J Minim Access Surg.* 2013 Apr; 9 (2): 55-8.
- [25] Horwitz JR, Custer MD, May BH, Mehall JR, Lally KP. Should laparoscopic appendectomy be avoided for complicated appendicitis in children? *J Pediatr Surg.* 1997 Nov; 32 (11): 1601-3.
- [26] Krisher SL, Browne A, Dibbins A, Tkacz N, Curci M. Intra-abdominal abscess after laparoscopic appendectomy for perforated appendicitis. *Arch Surg.* 2001 Apr; 136 (4): 438-41.
- [27] Nataraja RM, Loukogeorgakis SP, Sherwood WJ, Clarke SA, Haddad MJ. The Incidence of intraabdominal abscess formation following laparoscopic appendectomy in children: A systematic review and meta-analysis. *J Laparoendosc Adv Surg Tech A.* 2013 Sep; 23 (9): 795-802.
- [28] Cho J, Park I, Lee D, Sung K, Baek J, Lee J. Risk factors for postoperative intra-abdominal abscess after laparoscopic appendectomy: Analysis for consecutive 1,817 experiences. *Dig Surg.* 2015; 32 (5): 375-81.
- [29] Schlottmann F, Reino R, Sadava EE, Campos Arbulú A, Rotholtz NA. Could an abdominal drainage be avoided in complicated acute appendicitis? Lessons learned after 1300 laparoscopic appendectomies. *Int J Surg.* 2016 Dec; 36 (Pt A): 40-43.