



Safety and Efficacy of Oblique Lateral Interbody Fusion (OLIF) in the Treatment of Degenerative Lumbar Spinal Stenosis

Qiang He^{1,†}, Jie Mei^{2,†}, Nianwei Yao¹, Weiqing Qian¹, Hong Yin^{1,*}, Xin Sun^{1,*}

¹Department of Orthopedics, Nanjing TCM Hospital Affiliated to Nanjing University of Traditional Chinese Medicine, Nanjing, China

²Department of Pentatology, Shandong Police General Hospital, Jinan, China

Email address:

2205687986@qq.com (Xin Sun), hongy@163.com (Hong Yin)

*Corresponding author

† Qiang He and Jie Mei are co-first authors.

To cite this article:

Qiang He, Jie Mei, Nianwei Yao, Weiqing Qian, Hong Yin, Xin Sun. Safety and Efficacy of Oblique Lateral Interbody Fusion (OLIF) in the Treatment of Degenerative Lumbar Spinal Stenosis. *Journal of Surgery*. Vol. 10, No. 2, 2022, pp. 95-100. doi: 10.11648/j.js.20221002.19

Received: April 10, 2022; Accepted: April 22, 2022; Published: April 28, 2022

Abstract: Background: Lumbar spinal stenosis is a common degenerative disease of the elderly and adequate decompression is the most critical determinant for the surgical management of degenerative DLCS. Objective: To compare and analyse the safety and effectiveness of the oblique lateral interbody fusion (OLIF) technique and conventional lumbar posterior laminar decompression for lumbar spinal stenosis (DLCS). Methods: Sixty-eight patients over 60 years of age with lumbar spinal stenosis were included from October 2019 to November 2021, and were divided into the OLIF group and the conventional decompression group (conventional posterior laminar decompression and internal fixation) according to their treatment methods. The general data, operation time, intraoperative bleeding, hospital stay, surgical complications, clinical efficacy evaluated by modified MacNab criteria, and the patients' preoperative and final postoperative pain visual analogue scale scores (VAS) and Oswestry dysfunction index (ODI) were statistically analysed in the two groups. Results: There was no statistically significant difference in age, gender, BMI, duration of disease, lesion segment, VAS score and ODI index between the two groups of patients before treatment ($p > 0.05$). After treatment, the OLIF group had a greater advantage in terms of operative time, intraoperative bleeding, length of hospital stay and operative complications than the conventional decompression group, with statistical significance between the groups ($P < 0.05$). Compared with the pre-treatment period, the VAS scores and ODI scores of patients in both groups showed significant improvement ($P < 0.05$). A comparison between the two groups revealed a statistically significant difference ($P < 0.05$) in the improvement of VSA and ODI scores at the end of the postoperative period in the OLIF group compared with the conventional decompression group. The clinical efficacy of the two groups evaluated by the modified MacNab criteria at the final follow-up was 90.625% in the OLIF group and 80.55% in the conventional decompression group, respectively, with a statistical difference ($P < 0.05$). Conclusion: Compared with traditional decompression fusion, the use of OLIF technique can safely and effectively decompress DLCS, and also has many advantages such as less trauma, less bleeding, shorter operation time and hospital stay, and lower postoperative complications, which is worthy of clinical preference.

Keywords: Lumbar Spinal Stenosis, Advanced Age, Spinal Decompression, OLIF Endoscopy

1. Introduction

Lumbar spinal stenosis is a common degenerative disease of the elderly, characterised by pathological spinal stenosis and compression of the spinal capsule together with nerve roots [1]. Clinical symptoms are usually low back pain,

neurogenic claudication, lower limb pain and reduced walking ability. DLCS currently relies initially on conservative measures such as physiotherapy, steroid injections and oral medication [2-3]. However, in patients with painful weakness, progressive reduction in walking distance, progression of neurological deficits and failure of conservative treatment, surgery is often recommended [3]. Numerous studies have

shown that the clinical outcome of surgical treatment is superior to that of conservative treatment [3-4]. Oblique lateral interbody fusion (OLIF) reduces the risk of injury to the psoas major and lumbar plexus nerve roots when the natural gap between the retroperitoneal psoas major muscle and the abdominal aorta is used as a reference to create a surgical approach. Unlike paravertebral muscle and posterior lumbar spine surgery, OLIF does not damage the small joints [5].

2. Materials and Methods

2.1. General Information

Sixty-eight patients with DLCS aged 60 years or older from October 2019 to November 2021 were included and divided into OLIF and conventional decompression groups according to their treatment. There were 32 patients (14 males and 18 females) in the OLIF group with a mean age of (69.56 ± 4.18) years, and 36 patients (15 males and 21 females) in the conventional decompression group, with an age distribution of 60 years or more and a mean of (70.32 ± 4.82) years. The general data, operation time, intraoperative bleeding, hospital stay, surgical complications, clinical efficacy evaluated by modified MacNab criteria, patients' preoperative and final postoperative pain visual analogue scale scores (VAS) and Oswestry dysfunction index (ODI) were statistically analysed in both groups.

2.2. Inclusion Criteria

(1) age ≥ 60 years; (2) clinical signs of neurogenic intermittent claudication with or without radiculopathy and imaging of lumbar spinal stenosis; (3) unsatisfactory relief of clinical symptoms after conservative treatment for ≥ 3 months; (4) all patients voluntarily underwent surgical treatment and

regular postoperative review. Exclusion criteria: Lateral radiographs of lumbar hyperextension and hyperflexion showing lumbar instability, Cobb angle difference $>15^\circ$ in hyperextension and hyperflexion or displacement of more than 3 mm, requiring fusion surgery; clear-cut cases of intermittent vascular claudication, obvious lumbar disc herniation, vertebral slippage of II° or more, lumbar infection or stenosis combined with malignant tumour.

2.3. Surgical Options

2.3.1. OLIF Group

The patient is placed prone on the operating table after satisfactory general anaesthesia, in the right lateral position, and the operative segment is fluoroscopically positioned and marked before surgery. The skin and deep fascia are incised sequentially with the aid of fluoroscopy, and the retroperitoneal space is reached by bluntly separating the external and internal oblique abdominal muscles and the transversus abdominis fibres, and the abdominal organs are moderately pushed forward. The target disc is exposed through the natural space between the retroperitoneal psoas major muscle and the abdominal aorta, and fluoroscopic fixation of the intervertebral space, canal dilation and removal of excess tissue is completed. The intervertebral space and intervertebral foramen are propped open to the desired height under the appropriate components, and the fusion device places the bone particles into the intervertebral space; after satisfactory results, the incision is closed layer by layer. See Figure 1. ventricular drain is inserted via the operating channel to the appropriate depth. The incision is closed with sutures. One preoperative and one postoperative dose of antibiotics were applied and bed rest was followed by bed exercise under the protection of a lumbar girth after 3 d.

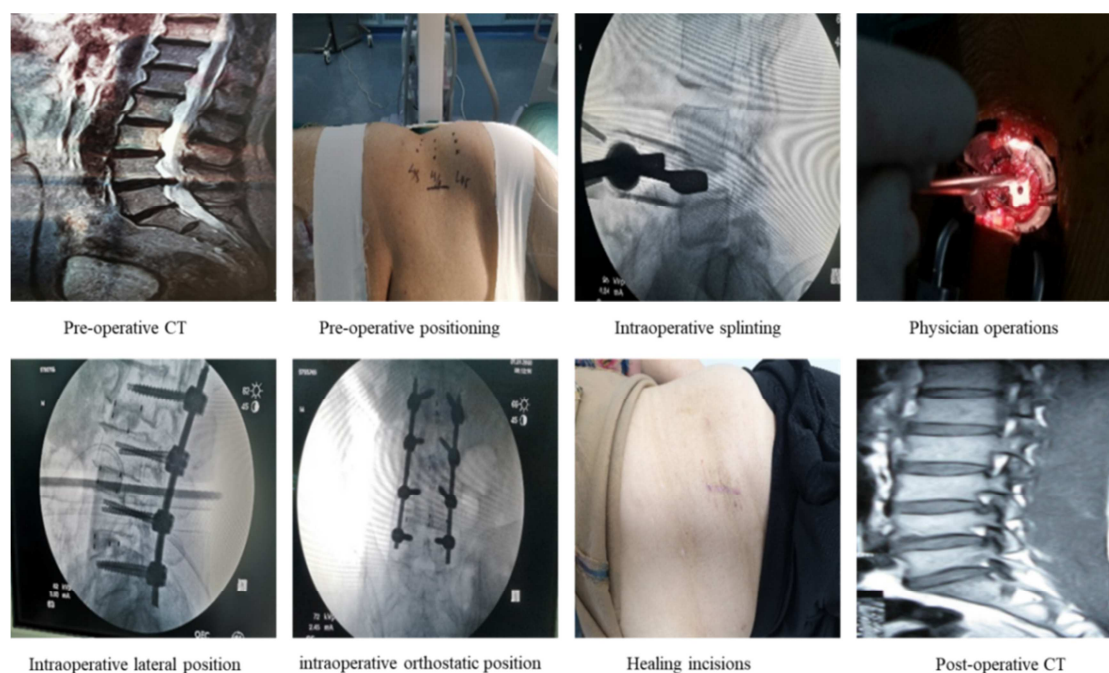


Figure 1. OLIF group surgical procedure.

2.3.2. Traditional Decompression Group

Patients in the traditional decompression group were treated with traditional laminectomy for decompression and internal fixation. The procedure was as follows: after satisfactory general anaesthesia, a posterior median incision was made with the patient's diseased segment as the centre, the skin, subcutaneous tissue and fascia at the edge of the supraspinous ligament were incised in turn, and the sacrospinous muscles on both sides of the spinous process were separated to fully expose the decompression and fixation segment; pedicle screws were placed, the inferior edge of the superior lamina and the entire superior edge of the inferior lamina were excised, and the nerve roots were exposed and released. The nerve roots were exposed and released by subtle enlargement of the lateral saphenous fossa, after which the nerve roots and dura were pulled medially, the intervertebral disc and cartilage endplates were completely removed, an appropriate intervertebral fusion device was selected for intervertebral implant fusion, and the nail rods were linked and fixed with pressure; the incision was closed layer by layer, a wound drainage tube was placed, and the wound was dressed after surgery. The open group in this study all underwent interbody fusion to avoid postoperative instability.

2.4. Postoperative Management

A drainage tube was routinely placed in the incision. Two patients with cerebrospinal fluid leakage were placed intraoperatively and connected to a drainage bag, and the drainage tube was removed 24 hours after surgery as appropriate. Post-operative antibiotics were routinely administered to prevent infection. Patients were instructed

to move their lower limbs as soon as possible to prevent deep vein thrombosis in the lower limbs and to reduce bed-ridden complications. Monitor the patient's inflammatory and biochemical indexes postoperatively. Actively control blood pressure, blood glucose and other coexisting conditions.

2.5. Statistical Indicators

Patients' age, gender, BMI, duration of disease, lesion segment, duration of surgery, intraoperative bleeding, length of hospital stay, surgical complications, modified MacNab criteria to evaluate clinical efficacy, patients' preoperative and final postoperative pain visual analogue scale scores (VAS), and Oswestry dysfunction index (ODI) were counted.

2.6. Statistical Methods

SPSS 26.0 software was used for statistical analysis. X2 test was used for counting data (gender, modified MacNab evaluation results) and independent t-test was used to compare the measurement data (operation time, intraoperative bleeding, hospital stay, operation complications, VAS score, ODI score), with $P < 0.05$ being considered a statistically significant difference.

3. Results

3.1. Analysis of Baseline Information for Both Groups

There was no statistical difference between the two groups in terms of gender, age, BMI and lesion segment ($P > 0.05$), and they were comparable. See Table 1.

Table 1. Statistical analysis of baseline information for both groups ($\bar{X} \pm S$; cases).

Group	Gender (m/f)	Age (years)	BMI (kg/m ²)	Lesion segments (L3-4/L4-5/L5-S1)
OLIF Group	14/18	69.56±4.18	23.13±1.91	6/15/14
Traditional decompression group	15/21	70.32±4.82	23.64±2.71	6/16/16
F	0.003	0.314	0.169	1.648
P	0.955	0.577	0.621	0.203

3.2. Analysis of Perioperative Data and Postoperative Complications in Both Groups

In the OLIF group, 32 patients had only one postoperative wound infection and no other complications; in the traditional decompression group, 36 patients had three postoperative wound infections, one cerebrospinal fluid leak and one nerve strain. Injury.

Table 2. Analysis of perioperative data in both groups ($\bar{X} \pm S$).

Group	n	Surgery time (min)	Intraoperative bleeding (ml)	Length of stay in hospital (day)
OLIF Group	32	120.78±11.25	282.50±64.21	12.97±1.29
Traditional decompression group	36	152.17±10.51	451.11±38.34	21.34±1.90
F		5.342	18.298	7.066
P		0.045	0.000	0.010

3.3. Analysis of Preoperative and Postoperative Final ODI and VSA in the Two Groups

There was no statistical difference in the preoperative VSA and ODI scores between the two groups ($P > 0.05$); the VSA and ODI

scores at the last postoperative follow-up in both groups were significantly improved compared with the preoperative scores, and there was a statistical difference in the intra-group comparison ($P < 0.05$); the comparison between the two groups revealed that the improvement in VSA and ODI scores at the end of the postoperative period was more obvious in the OLIF group

than in the conventional decompression group, and there was a statistical difference ($P < 0.05$). See Table 3 and Figure 2.

Table 3. Comparative analysis of preoperative and final postoperative VSA and DOI scores between the two groups ($\bar{X} \pm S$).

Group	n	Waist VSA		Leg VSA		ODI	
OLIF Group	32	7.59±0.95	1.47±0.94	7.63±0.94	1.47±1.01	0.85±0.07	0.17±0.08
Traditional decompression group	36	7.64±0.99	2.31±0.79	7.67±0.96	2.33±0.83	0.84±0.07	0.24±0.06
F		0.037	15.783	0.033	14.933	0.117	19.701
P		0.849	0.000	0.857	0.000	0.734	0.000

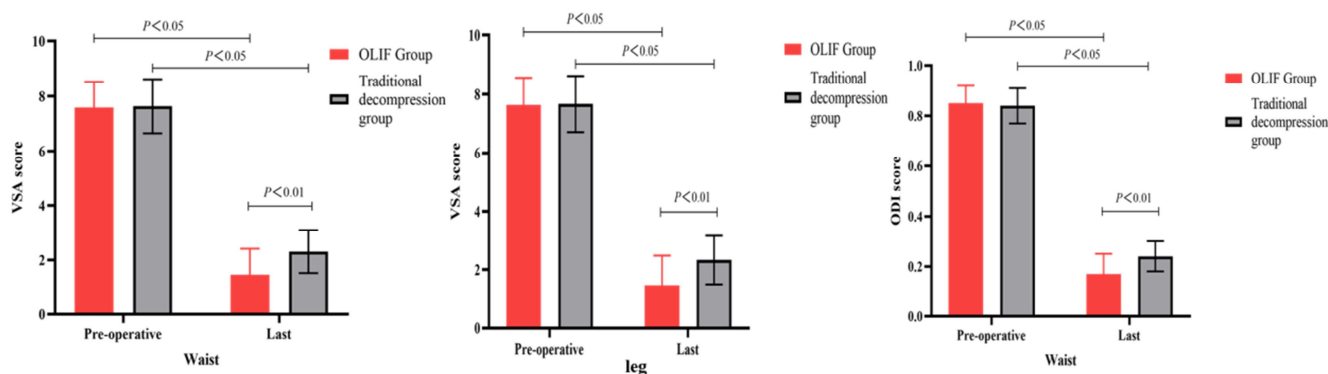


Figure 2. Comparison of VSA and ODI scores for low back and legs between the two groups.

3.4. Analysis of the Results of the Evaluation of the Modified MacNab Criteria in the Two Groups

The excellent rate of the two groups was 82.85% in the UBE group and 78.94% in the conventional decompression

group when the modified MacNab criteria were evaluated at the 12-month postoperative follow-up, and the UBE group was significantly better than the conventional decompression group, with statistical differences ($P < 0.05$).

Table 4. MacNab scores at the final postoperative follow-up in both groups (cases, %).

Group	n	Excellent	Favorable	General	Poor	Excellent rate
OLIF Group	32	19 (59.375)	10 (31.25)	3 (9.375)	0 (0.00)	29 (90.625)
Traditional decompression group	36	16 (44.44)	13 (36.11)	5 (13.89)	2 (5.56)	29 (80.55)
χ^2						17.210
P						0.009

4. Discussion

DLCS is the most common indication for spinal surgery in the elderly [6]. For decades, wide laminectomy with or without concomitant fusion procedures was considered the conventional surgical procedure [7-8]. This classic approach usually involves extensive soft tissue dissection, but can lead to fatty degeneration, atrophy and paravertebral muscle weakness and result in a failed low back surgery syndrome [9-10]. Randomised controlled trials have shown that fusion is not effective in decompression of degenerative DLCS [11-12]. Considering the risks of spinal fusion and internal fixation, simple but adequate decompression is a better option for patients who do not have an absolute need for additional stabilisation surgery [13].

The most important factor in the surgical therapy of degenerative DLCS is sufficient decompression of the neural structures [14]. Traditional open surgery, on the other hand, necessitates considerable dissection and tension on the paravertebral muscles, which can result in muscular ischaemia and nerve injury, resulting in atrophy, postoperative low back

discomfort, and low postoperative patient satisfaction [15]. To circumvent these restrictions, minimally invasive procedures have been created. For more than two decades, minimally invasive (MI) spine surgery has effectively treated patients with a wide range of lumbar spine diseases [16-19]. With advances in surgical instrumentation and endoscopic techniques, MI spine surgery has gradually and rapidly evolved from a miniature open to a tubular or percutaneous endoscopic approach. In addition to the potential benefits of the MI spinal surgical approach (smaller wounds, reduced local pain, less blood loss, less postoperative wound pain and shorter hospital stays), numerous biomechanical studies have demonstrated the importance of the posterior column, including the interspinous ligaments and small joints, in maintaining spinal stability [20-21]. Minimising disruption to the paravertebral muscles and posterior stabilising structures is therefore the most critical issue in the long-term developmental progress of MI spine surgery [22]. In the last decade, due to advances in minimally invasive spinal fusion techniques, OLIF surgery has emerged and is increasingly being used by spine surgeons. The benefits of the OLIF technique include preservation of the posterior lumbar

structures, reduced blood loss and shorter hospital stays [23].

OLIF increases the height of the intervertebral space and enhances interbody stability [24]. OLIF neither invades the spinal canal nor requires crossing the psoas major muscle. In contrast to posterior lumbar interbody fusion, the surgical approach to OLIF is to expose and distract the psoas major muscle by bluntly separating the internal oblique, transversus abdominis and transverse fascia through the natural gap between the psoas major muscle and the retroperitoneal vessels, i.e. revealing the guide needle for insertion into the target vertebral space and then gradually expanding to allow access to the target area [25-26]. Preoperative preparation includes adequate knowledge of the width of the gap between the psoas major muscle and the large abdominal vessels to estimate the actual size of the surgical window [27]. The psoas major muscle should not be overstretched, as this may damage the lumbar plexus nerve roots. OLIF should be performed with caution in patients with large-vessel malformations or particularly narrow gaps between the psoas major muscle and the large abdominal vessels. If the assessment indicates that the surgical window is not suitable for OLIF, other treatment options such as posterolateral interbody fusion or conventional posterior decompressive fixation may be considered.

5. Conclusion

In the current study, there was a significant improvement in clinical symptoms of degenerative DLCS treated by the OLIF technique in the postoperative period. The improvement in pain symptoms was significantly demonstrated by the leg VAS score (from 7.63 to only 1.47). Neurological and functional symptoms were also significantly improved by the ODI score results. Thus, the OLIF technique can be a safe and effective treatment for degenerative DLCS.

References

- [1] Hall S, Bartleson J D, Onofrio B M, et al. Lumbar spinal stenosis. Clinical features, diagnostic procedures, and results of surgical treatment in 68 patients [J]. *Annals of Internal Medicine*, 1985, 103 (2): 271-5.
- [2] Parker S L, Godil S S, Mendenhall S K, et al. Two-year comprehensive medical management of degenerative lumbar spine disease (lumbar spondylolisthesis, stenosis, or disc herniation): a value analysis of cost, pain, disability, and quality of life: clinical article. [J]. *Journal of Neurosurgery Spine*, 2014, 21 (2): 143.
- [3] Katz J N, Harris M B. Surgical versus nonsurgical therapy for lumbar spinal stenosis [J]. *New England Journal of Medicine*, 2008, 358 (8): 2647; author reply 2647-8.
- [4] Malmivaara A, Si Tis P, Heli Vaara M, et al. Surgical or nonoperative treatment for lumbar spinal stenosis? A randomized controlled trial. [J]. *Spine*, 2007, 32 (1): 1-8.
- [5] Britt J, Jain R, Li R. Robotic radical nephroureterectomy in a patient with situs inversus totalis [J]. *Urology Case Reports*, 2021, 37 (6): 101688.
- [6] He J L, Xiao S W, Wu Z J, et al. Microendoscopic discectomy versus open discectomy for lumbar disc herniation: a meta-analysis [J]. *European spine journal: official publication of the European Spine Society, the European Spinal Deformity Society, and the European Section of the Cervical Spine Research Society*, 2016, 25 (5): 1373.
- [7] Clark A J, Safaee M M, Khan N R, et al. Tubular microdiscectomy: techniques, complication avoidance, and review of the literature [J]. *Neurosurgical Focus*, 2017, 43 (2): E7.
- [8] Ding Y, Zhang J J, Lu Z C, et al. Study on the strategy of posterior endoscopic decompression surgery for lumbar spinal stenosis [J]. *Chinese Journal of Bone and Joint Surgery*, 2021, 4 (14): 285-291.
- [9] Kyung-Chul, Choi, June-Ho, et al. Unsuccessful percutaneous endoscopic lumbar discectomy: a single-center experience of 10, 228 cases. [J]. *Neurosurgery*, 2015, 76 (4): 372-80.
- [10] Wang Z P, Zhang X G, Li Y Z, et al. Meta-analysis of percutaneous endoscopic lumbar discectomy for the treatment of recurrent lumbar disc herniation complications [J]. *Chinese Journal of Spinal Cord*, 2020, 274 (01): 60-68.
- [11] Chen H-L. Comparison of the efficacy and safety of microendoscopic and microscopic lumbar discectomy for lumbar disc herniation [J]. *Journal of Neck and Back Pain*, 2019, 40 (01): 76-78.
- [12] Cao Y W, Liu Y J, Yuan J, et al. Anatomical study and clinical significance of posterior percutaneous endoscopic cervical discectomy [J]. *Chinese Journal of Clinical Anatomy*, 2020, 38 (03): 9-12.
- [13] Eum J H, Heo D H, Son S K, et al. Percutaneous biportal endoscopic decompression for lumbar spinal stenosis: a technical note and preliminary clinical results [J]. *Journal of neurosurgery. Spine*, 2016: 1-6.
- [14] Bebbington M. Surgical complications of microendoscopic procedures for lumbar spinal stenosis. [J]. *Minim Invasive Neurosurg*, 2007, 50 (03): 145-149.
- [15] Overdevest G M, Moojen W A, Arts M P, et al. Management of lumbar spinal stenosis: a survey among Dutch spine surgeons [J]. *Acta Neurochirurgica*, 2014, 156 (11): 2139-2145.
- [16] Kim H S, Paudel B, Jang J S, et al. Percutaneous Full Endoscopic Bilateral Lumbar Decompression of Spinal Stenosis Through Uniportal-Contralateral Approach: Techniques and Preliminary Results [J]. *World Neurosurgery*, 2017: S1878875017304539.
- [17] Ding Y, Hai C, Yang J C, et al. Effect of percutaneous endoscope-assisted transvertebral foraminal lumbar decompression and fusion for single-segment lumbar spinal stenosis on the multifidus muscle [J]. *Chinese Journal of Spinal Cord*, 2019, 27 (09): 60-65.
- [18] Pao J L, Chen W C, Chen P Q. Clinical outcomes of microendoscopic decompressive laminotomy for degenerative lumbar spinal stenosis [J]. *European Spine Journal*, 2009, 18 (5): 672-678.
- [19] Minamide A, Yoshida M, Yamada H, et al. Clinical outcomes after microendoscopic laminotomy for lumbar spinal stenosis: a 5-year follow-up study [J]. *European Spine Journal*, 2015, 24 (2): 396-403.

- [20] Xu Baoshan, He Jian, Ma Xinlong, et al. Anatomical study and clinical application of the translumbar foraminal approach [J]. Chinese Journal of Orthopaedics, 2013, 33 (006): 593-600.
- [21] Li X R, Yu J, Zhang W, et al. Biomechanical Model Study of the Effect of Partial Facetectomy on Lumbar Stability Under Percutaneous Endoscopy – Science Direct [J]. World Neurosurgery, 2020, 139.
- [22] Bresnahan L E, Smith J S, Ogden A T, et al. Assessment of Paraspinal Muscle Cross-sectional Area After Lumbar Decompression Minimally Invasive Versus Open Approaches [J]. Clinical Spine Surgery, 2017, 30 (3): E162-E168.
- [23] Hao B C, Li L Y, Sun R S, et al. Logistic regression analysis of postoperative coronal imbalance in microendoscope-assisted OLIF surgery for lumbar degenerative disease [J]. Journal of Neck and Back Pain, 2021, 42 (4): 4.
- [24] Vit K, Weerasak S, Chindarat R, et al. Neutral hip position for the oblique lumbar interbody fusion (OLIF) approach increases the retroperitoneal oblique corridor [J]. BMC musculoskeletal disorders, 2021, 21 (4): 583.
- [25] Zhang X, H Wu, Chen Y, et al. Importance of the epiphyseal ring in OLIF stand-alone surgery: a biomechanical study on cadaveric spines [J]. European Spine Journal, 2020 (Suppl 3): 1-9.
- [26] Yang C, Zeng C, Li T, et al. Accelerated rehabilitation surgery in OLIF combined with anterior internal fixation for lumbar spinal stenosis with degenerative instability [J]. Chinese Journal of Bone and Joint, 2020, 9 (1): 6.
- [27] Liu J, Feng H. Oblique Lateral Interbody Fusion (OLIF) with Supplemental Anterolateral Screw and Rod Instrumentation: A Preliminary Clinical Study - ScienceDirect [J]. World Neurosurgery, 2020, 134.