

**Review Article**

Immediate Management of Pelvic Fractures Resulting from Blunt Trauma - A Concise Update

Seneviratne R. W.¹, Kumara M. M. A. J.¹, De Silva P. V.²

¹Department of Surgery, Faculty of Medicine, University of Ruhuna, Galle, Sri Lanka

²Department of Community Medicine, Faculty of Medicine, University of Ruhuna, Galle, Sri Lanka

Email address:

ranjanams@yahoo.com (R. W. Seneviratne)

To cite this article:

Seneviratne R. W., Kumara M. M. A. J., De Silva P. V. Immediate Management of Pelvic Fractures Resulting from Blunt Trauma - A Concise Update. *Journal of Surgery*. Vol. 3, No. 6, 2016, pp. 77-82. doi: 10.11648/j.js.20150306.15

Abstract: Pelvic trauma is considered as a management challenge even in the best trauma centres in the world. A patient can bleed to death from injuries of this highly vascular territory. Objective of this review paper is to describe the classification of pelvic trauma and to summarize the current management process of this controversial and complex condition.

Keywords: Major Trauma, Pelvic Fractures, Stabilization of Pelvis, Pelvic Slings, Pelvic Instability

1. Introduction

Pelvic trauma is a management challenge for even the best trauma centres. A patient can bleed to death from injuries of this highly vascular territory. Furthermore pelvic fracture is a reliable marker of life threatening high energy injury. Significant trauma and associated injuries are common with in pelvis and in other parts of body. Overall assessment is difficult as pelvic part of the trunk is thick and bone and blood vessels are situated in depth. Management is complex, controversial and demand a multidisciplinary approach [1].

Classification is important to relate to mechanism of injury, assess the risk of bleeding and make decisions to achieve haemostasis and stabilization of pelvis. Isolated or non-ring fractures have little systemic effect. Those who suffer ring fractures of pelvis can be subdivided in to two broad groups. The first group include Young and middle aged, usually men, who sustain high energy induced fractures from mechanisms such as road traffic accidents, falls from heights and crush injuries. Other group include elderly, usually females, who sustain isolated ring fractures from minimal trauma such as simple falls for which osteoporosis make a significant contribution [2]. As the latter group has little if any associated injuries and their management involves early mobilization in order to avoid complication of prolonged recumbence attention is focused

on management challenges of the former group. However, significant haemorrhage is not unheard of in elderly and they should be kept under observation for few days with serial haemoglobin measurements and CT and angioembolization (AED) should be considered if haemorrhage becomes significant [3].

Among Factors considered in classification of pelvic fractures in addition to direction and magnitude of force the anatomical sites of damage particularly the involvement of posterior elements i.e. posterior ileum, sacroiliac joint, sacrum, 5th lumbar vertebra and their associated ligaments are important [4]. Sacroiliac joint disruption on X-ray and CT appears to be a good indicator of the need for intervention [5]. Many classification systems are around but most widely in the recent literature are Tiles classification and young and burgess classification. Classification is mainly based on X-rays in the acute setting although CT-scan and less frequently MRI is brought in to use for accuracy [6]. However multi-detector CT scans with their high spatial resolution, sensitivity and short acquisition time are becoming rapidly popular in modern trauma centres. Manson et al emphasises the use of young and burgess system in predicting transfusion requirements and also mortality and association with non orthopaedic injuries provided components of the system are grouped in to stable and unstable [7].

Table 1. Young-Burgess classification of pelvic fractures.

Type	Anterior Posterior Compression	Lateral Compression	Vertical Shear
	APC I - Symphysis widening < 2.5cm	LC I - Pubic ramus fracture and ipsilateral anterior sacral ala compression fracture	VS - Posterior and superior directed force
	APC II - Symphysis widening > 2.5 cm. Anterior SI joint diastasis. Disruption of sacrospinous and sacrotuberous ligaments	LC II - Rami fracture and ipsilateral posterior ilium fracture dislocation	
	APC III - SI dislocation with associated vascular injury	LC III - Ipsilateral lateral compression and contralateral APC	

[8].

Table 2. Tile Classification of pelvic fractures.

Tile Classification	1	2	3
A - stable	Innominate bone avulsion or wing fracture	Stable ring fracture with intact posterior arch	Denis III transverse sacral fracture
B - rotationally unstable/vertically stable	Open-book external rotation injury	Young-Burgess lateral compression type internal rotation injury	Bilateral
C - rotationally and vertically unstable	Unilateral with intact contralateral side	Unilateral with incomplete contralateral side	Bilateral

[9].

2. Management

2.1. General

Pelvic fractures are associated with high energy trauma and injuries involving other areas. Approximately half of them have head injury and a long bone injury while 20% have chest injuries [10]. Although trauma patients are initially managed with ATLS protocol, detection of pelvic fractures should immediately shift the patient to a special category with special management algorithm involving specific transfusion protocols and interventions such as pelvic packing [11]. Attention should stay at achieving haemostasis from pelvic fracture until the objective is accomplished. Burkhard et al suggest future trauma algorithms to include unstable pelvic ring fractures Tiles B and C routinely [12]. Damage control resuscitation (DCR), the current trouble-shooter in facing challenges of haemostasis is called in to play along with attempts at tamponading the pelvic bleeding. The damage control resuscitation include permissive hypotension of keeping systolic blood pressure around 90 mmhg, avoiding colloids, limiting crystalloids usually to 1.5 litres, warming all fluids, early use of tranexemic acid as well as early use of blood and blood products [13]. Damage control interventions such as external slings, fixations, embolization and damage control surgery such as pelvic packing and internal iliac ligation are also included in DCR as a component [14]. Recent literature rarely mention the use of permissive hypotension in the management of pelvic trauma and it is safe to keep the said component out of resuscitation armamentarium in management of pelvic fractures [15].

Posterior ring fractures are associated with high transfusion requirements, need for laparotomy and death. Need for laparotomy in order to treat pelvic fractures and /or associated injuries is not uncommon. While negative FAST (focused

abdominal sonography for trauma) scan virtually eliminate the need for laparotomy, CT showing moderate to large haemoperitoneum has a good predictive value. In predicting final outcome for patients with pelvic fractures impact of associated injuries are significant. High Injury severity score is associated with long ICU stay, increased incidence of MODS, Sepsis and mortality [15].

2.2. Management-Specific

Specific management is focussed at haemostasis, stabilization of pelvis and management of other associated injuries, including that involving intra-pelvic organs. Bleeding associated with pelvic fractures usually come from bony surfaces, pre-sacral and lumbar venous plexuses and only 15-20% are from arterial injuries [16]. AED and pelvic packing addresses arterial bleeding well while mechanical pelvic stabilization tend to control bleeding from bony surfaces and veins. Non availability of a precise way to determine the exact source of bleeding leading to haemodynamic instability has led to controversies remaining over timing and optimal order of angiography, mechanical pelvic stabilization and packing [17].

Following options are available for haemostasis and stabilization of pelvis in the acute setting include

2.2.1. External Stabilization

External Stabilization can assist haemostasis in different ways such as reducing the fracture surfaces, stopping venous bleeding, reducing pelvic volume and ensuring blood clot stability [18]. Stability obtained depend on the type of the fracture, the bone quality, the design of the fixator, the patient habitus, the quality of reduction, the techniques of maintenance etc [19].

Methods of external stabilization of pelvic injuries includes both non-invasive and invasive techniques.

(i). Non Invasive External Stabilization**a. Pelvic binding**

This is the quickest, easiest and most widely available method to reduce bleeding from and stabilize a pelvis fracture. The commercial slings are available but they can be improvised with bed sheets. Application reduces pelvic volume thereby space available for bleeding which was much evident in post-procedural radiographs. Although some types of pelvic fractures show no improvement and in some lateral compression injuries the deformity has actually increased, no hazards were associated with the use of pelvic binding [20].

b. Military Ant Shock Trousers (MAST)

This popular military device and some modifications of it are used by civilian pre-hospital and hospital setting to reduce pelvic blood flow and bleeding [21].

(ii). Invasive External Stabilization**a. Anterior External fixation**

Anterior external fixation has been used with or without skeletal traction to stabilize pelvic fractures. The pins are inserted to pelvis at different locations which are connected by external bars. These pins can be inserted through the iliac wings or “upper way”, supra-acetabular area or “lower way” as well as sub crystal approach parallel to iliac crest. Iliac wing pins are usually sufficient for Open book and lateral compression fractures (Tiles B1, B2) while Tiles C require some form of posterior fixation. Thick bony Supra-acetabular anchorage provide better stability and access to abdominal surgery [19]. Sub crystal approach developed by Solomons LB *et al* in 2009 has the advantage over other techniques in the form of speed, accuracy and safety even in the hands of less experienced [22].

Patients rarely present with isolated pelvic injuries. Concomitant abdominal injuries are frequent making abdominal surgery a requirement. Some patients are obese having made it necessary to come up with different configurations of external fixations which fits the respective situation.

Numerous different external fixator configurations are available for this purpose such as the single configuration, the double configuration, the single tent, the double tent, rhomboid *ect.* Use of two parallel connecting rods for external pelvic ring fixation provides the highest translational (lateral compression/distraction) and rotational (bending of the hip) stability [22].

The anterior pelvic external fixation mounted on iliac crest with pre and postoperative continuous skeletal traction can restore and maintain vertically unstable sacral fracture. It achieves excellent functional and radiographic outcome and has few complications [23].

b. Posterior External Fixation

The most widely used device C-clamp compresses and stabilizes posterior elements which are intimately related to blood vessels. Many patients show immediate improvement of their vital signs on application [24]. However inaccurate placement can damage superior gluteal artery and sciatic nerve.

2.2.2. Traction

This is usually employed along with one of the above invasive external fixation devices and particularly in vertically

unstable pelvic fractures [23]. Employment of traction usually precludes decision for internal fixation approximately 5-10 days later.

2.2.3. Angioembolization (AED)

Emerged as a valuable tool to stop arterial bleeding in 1980's it can be used even repeatedly in a haemodynamically unstable patient with pelvic trauma once the non pelvic bleeding has been ruled out. In patients whose CT scans demonstrating extravasation of contrast i.e high flow haemorrhages, AED and open surgery may be required irrespective of haemodynamic status [25]. Localized pelvic blush or ‘low flow haemorrhage’ can be managed conservatively with judicious use of blood products [26, 27]. AED can be used selectively or non-selectively with latter running higher risk of complications. They include gluteal muscle necrosis (6%), surgical wound breakdown (5%), deep infections (4%), impotence (2%) and long term complications of buttock, thigh and perineal paraesthesia (31%) [28]. Early intervention using AED appears to have a clear benefit [29]. Diagnostic only angiography is used with decreasing frequency while use of AED is gaining popularity in management of pelvic fractures [30]. However 24/7 equal availability of the resource high AED is still beyond the administrative capabilities of some of the best trauma centres [31].

2.2.4. Internal fixation

Although this option is often considered impractical in the acute setting advent of minimally invasive internal fixation (percutaneous internal fixation) using options such as transiliacal internal fixator and iliosacral screws become essential at times to achieve haemorrhage control. These methods usually require traction and follow up with tendency to proceed to more solid and long term solutions such as pelvic plates and spino-pelvic fixation once patient is stabilized. However reports available reveal management by acute definitive internal fixation may give a comparable outcome [32, 33].

2.2.5. Open Surgery**(i). Pre Peritoneal Packing (PPP)**

Since the first report by pohlemann in 1994 this technique has grown in popularity [34]. It mainly control venous bleeding which contributes to haemodynamic instability in a majority but has an impact on arterial bleeding. To be effective in an unstable pelvic fracture this has to be combined with anterior external fixation [34-36].

(ii). Internal Iliac Ligation

This tool may become necessary as a last resort despite associated complications [37].

3. Conclusions

The modalities employed and their timing varies between trauma centres. External fixation followed by AED is favoured by some centres. Severe cases may benefit from Preperitoneal pelvic packing along with external fixation

followed by AED [38, 39]. Internal iliac ligation may be required in extreme cases. Some centres in developed countries go for AED early before open surgical options and even external fixators due to minimum invasiveness and rapid

accessibility [25]. The management algorithm need to be developed by each trauma centre taking local conditions in to consideration. An example is given below.

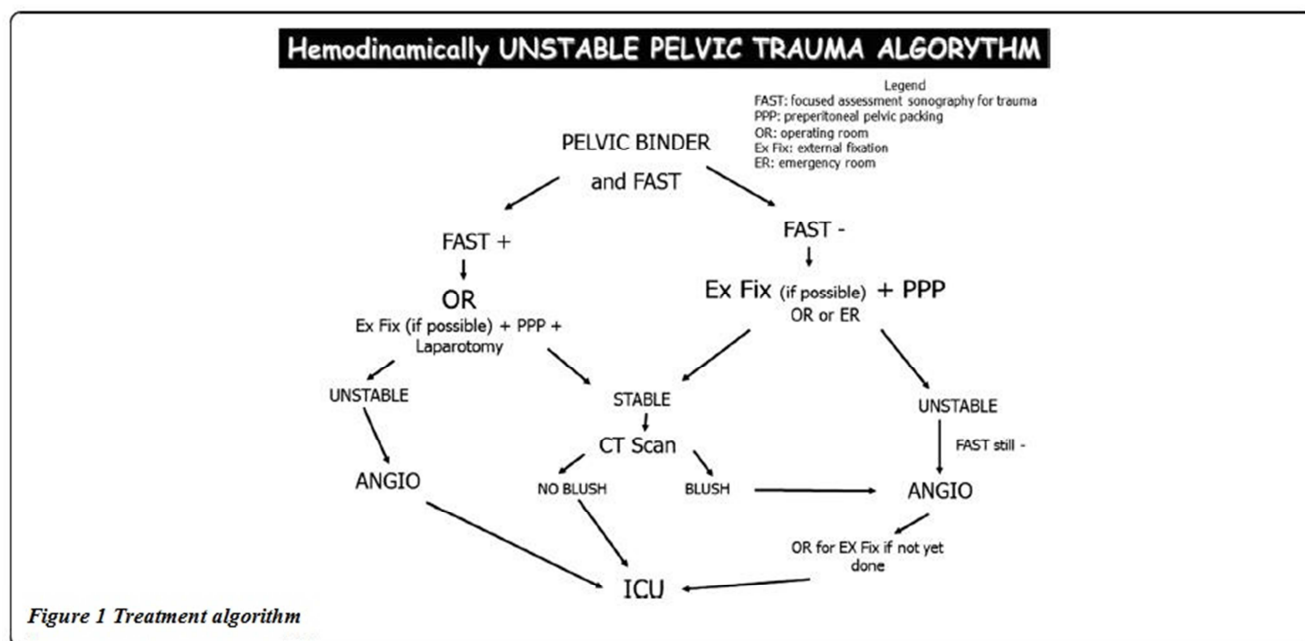


Figure 1. Hemodynamically unstable pelvic trauma alogrythm. [25].

Adjusted pelvic fracture mortality rate has significantly decreased over the time with comparable mortality rate among stable and unstable patterns, a result of dedicated attention given to this challenging injury by leading trauma centres [40]. However still the mortality rate is unacceptably high from pelvic fractures due to variations in injury pattern, complexity of presentation and multidisciplinary approach required. Research should continue to develop modalities for rapid and accurate assessment, aggressive resuscitation aimed at achieving early pelvic haemostasis and stability in addition to managing significant associated injuries.

References

- [1] Management of pelvic fractures./Eckroth-Bernard K1, Davis JW. 2010 Dec; 16 (6): 582-6. doi: 10.1097/MCC.0b013e3283402869.
- [2] Acta Chir Orthop Traumatol Cech. 2012; 79 (1): 65-8./[The influence of patient age and mechanism of injury on the type of pelvic fracture: epidemiological study]. Ježek M1, Džupa V.
- [3] Hemorrhage after low-energy pelvic trauma.-Krappinger D1, Zegg M, Jeske C, El Attal R, Blauth M, Rieger M. J Trauma Acute Care Surg. 2012 Feb; 72 (2): 437-42.
- [4] Magnetic resonance imaging for the evaluation of ligamentous injury in the pelvis: a prospective case-controlled study./Gary JL1, Mulligan M, Banagan K, Sciadini MF, Nascone JW, O'toole RV.- J Orthop Trauma. 2014 Jan; 28 (1): 41-7. doi: 10.1097/BOT.0b013e318299ce1b./.
- [5] The selection of diagnostic modalities in the management of pelvic fracture patients requiring transfers/Chih-Yuan Fu†, Shang-Ju Yang†, Chien-Hung Liao*, Being-Chuan Lin, Shih-Ching Kang, World Journal of Emergency Surgery 2015, 10: 33 doi: 10.1186/s13017-015-0027-4.
- [6] Diagnosis and therapy of acute hemorrhage in patients with pelvic fractures - Kos S1, Gutzeit A, Hoppe H, Liu DM, Jacob AL. Semin Musculoskelet Radiol. 2013 Sep; 17 (4): 396-406. doi: 10.1055/s-0033-1356469. Epub 2013 Oct 7.
- [7] Young-Burgess Classification of Pelvic Ring Fractures: Does It Predict Mortality, Transfusion Requirements, and Non-orthopaedic Injuries?/Manson, Theodore MD; O'Toole, Robert V MD; Whitney, Augusta MD; Duggan, Brian MD; Sciadini, Marcus MD; Nascone, Jason MD -journal of Orthopaedic Trauma: October 2010 - Volume 24 - Issue 10 - pp 603-609doi: 10.1097/BOT.0b013e3181d3cb6b.
- [8] Burgess AR, Eastridge BJ, Young JW, Ellison TS, Ellison PS Jr, Poka A, Bathon GH, Brumback RJ (1990). "Pelvic ring disruptions: effective classification system and treatment protocols". J Trauma 30 (7): 848-56. doi: 10.1097/00005373-199007000-00015. PMID 2381002.
- [9] Tile M (Jan 1988). "Pelvic ring fractures: should they be fixed?" J Bone Joint Surg Br 70 (1): 1-12. PMID 3276697.
- [10] Mattox book-Trauma, Third Edition/david v. felliciano MD, Ernest E. Moore MD, Kenneth L. Mattox MD, copy right-1996 by Appeltion and Lange/ISBN 0-8385-9010-1-90000.
- [11] Hemodynamically unstable pelvic fracture management by advanced trauma life support guidelines results in high mortality.-Hou Z1, Smith WR, Strohecker KA, Bowen TR, Irgit K, Baro SM, Morgan SJ. Orthopedics. 2012 Mar 7; 35(3): e319-24. doi: 10.3928/01477447-20120222-29.

- [12] Crit Care. 2012 Aug 22; 16 (4): R163. doi: 10.1186/cc11487/Acute management and outcome of multiple trauma patients with pelvic disruptions./Burkhardt M, Nienaber U, Pizanis A, Maegele M, Culemann U, Bouillon B, Flohé S, Pohlemann T, Paffrath T; Trauma Register DGU; German Pelvic Injury Register of the Deutsche Gesellschaft für Unfallchirurgie.
- [13] World J Emerg Med. 2010; 1(2): 85–92. PMID: PMC4129756/What are the ten new commandments in severe polytrauma management/CW Kam, CH Lai, SK Lam, FL So, CL Lau, and KH Cheung.
- [14] Damage control strategies in the management of acute injury/Stephanie A Savage T. C. Fabian/European Journal of Trauma and Emergency Surgery (Impact Factor: 0.35). 04/2014; 40(2): 143-150. DOI: 10.1007/s00068-014-0386-7.
- [15] Emerg Med Australas. 2010 Dec; 22 (6): 556-64. doi: 10.1111/j.1742-6723.2010.01355.x/Management guideline in haemodynamically unstable patients with pelvic fractures: Outcomes and challenges. Asadollahi S1, de Steiger R, Gruen R, Richardson M.
- [16] Injury. 2014 Feb; 45 (2): 374-8. doi: 10.1016/j.injury.2013.10.011. Epub 2013 Oct 18. Critical review of pelvic fractures associated with external iliac artery lesion: a series of six cases. Pascarella R1, Del Torto M2, Politano R2, Commessatti M3, Fantasia R2, Maresca A2.
- [17] Management of Bleeding Pelvic Fractures- I. Marzi, T. Lustenberger/Scand j surgery, 2014 Apr 15: 103 (02): 104-111.
- [18] Research Article Biomechanical Comparison of Different External Fixation Configurations for Posttraumatic Pelvic Ring Instability/Simon Tiziani, 1 Georg Osterhoff, 1 StephenJ. Ferguson, 2 Gregor Spreiter, 2 MaxJ. Scheyerer, 1 Gian-Leza Spinaz, 1 GuidoA. Wanner, 1 Hans-Peter Simmen, 1 and Clément M. L. Werner1 1 Department of Surgery, Division of Trauma Surgery, University Hospital Zurich, Raemistrasse100, 8091Zurich, Switzerland/Hindawi Publishing Corporation Advances in Orthopedic Surgery Volume 2014, Article ID 360165, 5 pages <http://dx.doi.org/10.1155/2014/360165>.
- [19] METHODS AND TECHNIQUES OF PERCUTANEOUS EXTERNAL FIXATION IN PELVIC FRACTURES Pavlin Apostolov, Martin Burnev, PetarMilkov Clinic of Orthopaedics and Traumatology MBAL “Saint Anna” Hospital - Varna, Bulgaria-DOI: 10.5272/jimab.2011171.166.
- [20] Efficacy and safety of emergency non-invasive pelvic ring stabilisation-Laszlo Toth, Kate L. King, Benjamin McGrath, Zsolt J. Balogh, Volume 43, Issue 8, August 2012, Pages 1330–1334 doi: 10.1016/j.injury.2012.05.014.
- [21] Use of an improvised pneumatic anti-shock garment and a non-pneumatic anti-shock garment to control pelvic blood flow. Hauswald M, Williamson MR, Baty GM, Kerr NL, Edgar-Mied VL. Int J Emerg Med. 2010 Jul 21; 3 (3): 173-5. doi: 10.1007/s12245-010-0191-y.
- [22] The subcrystal pelvic external fixator: technique, results, and rationale. Solomon LB1, Pohl AP, Sukthankar A, Chehade MJ. -J Orthop Trauma. 2009 May-Jun; 23 (5): 365-9. doi: 10.1097/BOT.0b013e3181a2aacc3.
- [23] Surgical Science, 2013, 4, 225-230 <http://dx.doi.org/10.4236/ss.2013.44043> Published Online April 2013 (<http://www.scirp.org/journal/ss>) Treatment of Vertically Unstable Sacral Fractures with Pelvic External Fixation and Skeletal Traction-Xueyuan Wu1*, Hongbin Zhu2, Heng Du1*, Wei Ma1#, Chihua Guo1 1Department of Orthopaedics, The First Affiliated Hospital, Medical School, Xi'an Jiaotong University, Xi'an, China.
- [24] Clin Orthop Relat Res. 1991 Jun; (267): 71-8. The antishock pelvic clamp. Ganz R1, Krushell RJ, Jakob RP, Küffer J.
- [25] Management of hemodynamically unstable pelvic trauma: results of the first Italian consensus conference. Stefano Magnone et al. World Journal of Emergency Surgery 2014, 9: 18 doi: 10.1186/1749-7922-9-18.
- [26] Management strategy of vascular injuries associated with pelvic fractures Klein SR1, Saroyan RM, Baumgartner F, Bongard FS. Cardiovasc Surg (Torino). 1992 May-Jun; 33 (3): 349-57.
- [27] Spiral computed tomography in the assessment of vascular lesions of the pelvis due to blunt trauma]/Romano L1, Pinto A, De Lutio Di Castelguidone E, Scaglione M, Giovine S, Sacco M, Pinto F./ J Radiol Med. 2000 Jul-Aug; 100(1-2): 29-32.
- [28] Clin Orthop Relat Res. 2013 Sep; 471 (9): 2906-11. doi: 10.1007/s11999-013-3119-z. Acute complications of patients with pelvic fractures after pelvic angiographic embolization. Matityahu A1, Marmor M, Elson JK, Lieber C, Rogalski G, Lin C, Belaye T, Miclau T 3rd, Kandemir U.
- [29] Angioembolization for pelvic hemorrhage control: results from the German pelvic injury register./Hauschild O1, Aghayev E, von Heyden J, Strohm PC, Culemann U, Pohlemann T, Suedkamp NP, Schmal H. J Trauma Acute Care Surg. 2012 Sep; 73(3): 679-84.
- [30] Utilization of angiography and embolization for abdominopelvic trauma: 14 years' experience at a level I trauma center./Roudsari BS1, Psoter KJ, Padia SA, Kogut MJ, Kwan SW/ AJR Am J Roentgenol. 2014 Jun; 202 (6): W580-5. doi: 10.2214/AJR.13.11216.
- [31] Are we delivering two standards of care for pelvic trauma? Availability of angioembolization after hours and on weekends increases time to therapeutic intervention./Schwartz DA1, Medina M, Cotton BA, Rahbar E, Wade CE, Cohen AM, Beeler AM, Burgess AR, J Trauma Acute Care Surg. 2014 Jan; 76(1): 134-9. doi: 10.1097/TA.0b013e3182ab0cfc. Holcomb JB.
- [32] Acute definitive internal fixation of pelvic ring fractures in polytrauma patients: a feasible option. Enninghorst N1, Toth L, King KL, McDougall D, Mackenzie S, Balogh ZJ. J Trauma. /2010 Apr; 68 (4): 935-41. doi: 10.1097/TA.0b013e3181d27b48.
- [33] Is Closed Reduction and Percutaneous Fixation of Unstable Posterior Ring Injuries as Accurate as Open Reduction and Internal Fixation? Lindsay A1, Tornetta P 3rd, Diwan A, Templeman D./ J Orthop Trauma. 2015 Aug 6.
- [34] Pohlemann T, Gansslen A, Bosch U, Tschern H: The technique of packing for control of hemorrhage in complex pelvic fractures. Tech Orthop 1994, 9: 267-270.
- [35] Ertel W, Keel M, Eid K, Platz A, Trentz O: Control of severe hemorrhage using C-clamp and pelvic packing in multiply injured patients with pelvic ring disruption. J Orthop Trauma 2001, 15: 468-474.

- [36] Cothren CC, Moore EE, Johnson JL, Moore JB: Outcomes in surgical versus medical patients with the secondary abdominal compartment syndrome., *Am J Surg* 2007, 194 (6): 804-807.
- [37] Bilateral internal iliac artery ligation as a damage control approach in massive retroperitoneal bleeding after pelvic fracture./DuBose J1, Inaba K, Barmparas G, Teixeira PG, Schnüriger B, Talving P, Salim A, Demetriades D. *J Trauma*. 2010 Dec; 69 (6): 1507-14. doi: 10.1097/TA.0b013e3181d74c2f.
- [38] Abrasaarrrts, *Orthop Traumatol Surg Res*. 2013 Apr; 99(2): 175-82. doi: 10.1016/j.otsr.2012.12.014. Epub 2013 Feb 23. Unstable pelvic ring injury with hemodynamic instability: what seems the best procedure choice and sequence in the initial management? Abrassart S1, Stern R, Peter R.
- [39] Berlew cc- *J Am Coll Surg*. 2011 Apr; 212 (4): 628-35; discussion 635-7. doi: 10.1016/j.jamcollsurg.2010.12.020/Preperitoneal pelvic packing/external fixation with secondary angioembolization: optimal care for life-threatening hemorrhage from unstable pelvic fractures./Burlew CC1, Moore EE, Smith WR, Johnson JL, Biffl WL, Barnett CC, Stahel PF.
- [40] *J Orthop Trauma*. 2015 Sep 3. [Epub ahead of print]Improved Survival After Pelvic Fracture: 13 Year Experience at a Single Trauma Center Using a Multi-disciplinary Institutional Protocol. Black SR1, Sathy AK, Jo C, Wiley MR, Minei JP, Starr AJ.