

# Plica semilunaris sub-tenon approach retrobulbar anesthesia for posterior segment surgery

Patel SN, Langer PD, Bhagat N\*

Institute of Ophthalmology and Visual Science, UMDNJ - New Jersey Medical School, Newark, NJ 07103

## Email address:

Patel118@umdnj.edu(Patel SN), Planger@umdnj.edu(Langer PD), Bhagatne@umdnj.edu(Bhagat N)

## To cite this article:

Patel SN, Langer PD, Bhagat N. Plica Semilunaris Sub-Tenon Approach Retrobulbar Anesthesia for Posterior Segment Surgery, *Journal of Surgery*. Vol. 1, No. 2, 2013, pp. 12-13. doi: 10.11648/j.js.20130102.11

**Abstract:** Purpose: To describe a surgical technique to access the posterior sub-Tenon's space through a plica semilunaris incision where retrobulbar anesthesia is given in a safe and consistent manner. Methods: A modified technique for retrobulbar anesthesia with fewer complications. Results: This anesthetic approach has been used consistently and effectively in controlling intraoperative pain in 581 eyes undergoing both 20-gauge and small gauge pars plana vitrectomy over the last 5 years at our institution. Conclusion: Retrobulbar anesthesia through a plica semilunaris incision using a blunt cannula may have a better safety profile than the intraconal approach using a sharp needle.

**Keywords:** Retrobulbar Anesthesia, Sub-Tenon, Vitrectomy

## 1. Introduction

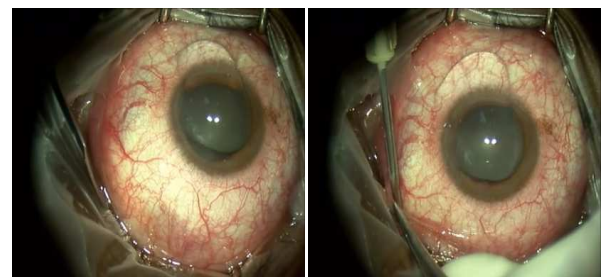
Regional or local anesthesia for posterior segment surgery is usually achieved by retrobulbar block using a transcutaneous approach wherein anesthetic solution is injected into the retrobulbar intraconal space. In spite of its effectiveness, rare but serious complications have been reported including accidental globe perforation, retrobulbar hemorrhage, penetration of the optic nerve sheath, retinal vascular occlusion, and myotoxicity.[1,2]

Sub-Tenon's anesthesia has been established as a simple, safe and effective technique in anterior segment surgery since the early 1990s.[3] We describe a technique (used by surgeon NB in 581 cases) to access the sub-Tenon's space through a plica semilunaris incision where retrobulbar anesthesia is given in a safe and consistent manner for posterior segment surgery. See video (hyperlink at the end of references) which demonstrates the technique.

## 2. Surgical Technique

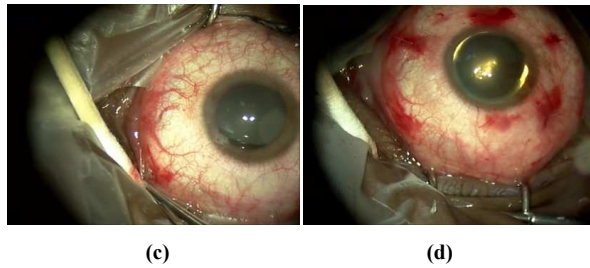
Sterile lidocaine gel is placed on the eye after the eye is prepped and draped in the standard ophthalmic fashion.[4] With sufficient surface anesthesia achieved, the surgeon uses Wescott scissors to create a small incision (approximately 1.5 mm) in the fold of plica semilunaris at its junction with the bulbar conjunctiva. This inferonasal incision extends posteriorly through the conjunctiva and underlying Tenon's

capsule (Fig. 1a). A blunt 22-gauge cannula attached to a syringe containing the anesthetic solution is then inserted in the sub-Tenon's space and guided around the globe posterior to the equator (Fig. 1b). Typically, 3.0 to 4.0 mL of anesthetic solution consisting of lidocaine (2%) and marcaine (0.5%) in a 1:1 ratio is injected.[4] Mild proptosis of the globe is seen. Adequate anesthesia and akinesia are readily achieved with minimal hemorrhagic ooze from the incision site and without altering the sclerostomy incision sites (Fig. 1c). At the end of the procedure, a small subconjunctival hemorrhage is usually noted in the inferonasal quadrant (marked as “\*”), through which retrobulbar anesthesia was given. Some hemorrhage is noted at sites of cannula insertions and lens ring suturing (Fig. 1d). The conjunctival incision in the fold of plica is not sutured and heals well.



(a)

(b)



**Figure 1.** (a) Creation of the snip incision in the fold of plica semilunaris at its junction with bulbar conjunctiva. (b) Insertion of 22-gauge blunt-tip cannula. (c) Appearance immediately following injection. Note a small subconjunctival hemorrhage at the incision site. (d) Appearance at the end of the procedure. Note small subconjunctival hemorrhages at the site of cannula insertions and lens ring suturing.

### 3. Discussion

The Tenon's fascia, or fascia bulbi, is a thin membrane firmly attached to the sclera at about 1.5 mm posterior to the corneoscleral junction extending posteriorly to the optic nerve.[5] It is perforated by the ciliary nerves and tendons of the extraocular muscles. Our technique is a modified sub-Tenon's block, where a blunt cannula is inserted into the posterior sub-Tenon's space through a snip incision of the conjunctiva and Tenon's fascia.[6] The cannula can be freely mobilized posteriorly around the equator of the globe. Ultrasound has been used to demonstrate the posterior tracking of anesthetic solution into the retrobulbar space during sub-Tenon's injection[7], accounting for observed proptosis. Pain sensation is blocked by the anesthetic acting on the ciliary nerves as they pierce the Tenon's capsule posteriorly. Vision decreases due to the direct effect of anesthetic on the optic nerve posteriorly, and akinesia is obtained by direct blocking of the motor nerve fibers as they pass through the fascia. This anesthetic approach has been used consistently and effectively in controlling intraoperative pain in 581 eyes undergoing both 20-gauge and small gauge pars plana vitrectomy over the last 5 years at our institution. The only side effects encountered have been mild discomfort during the injection and local conjunctival chemosis. The use of a blunt tip cannula minimizes the risk

of many of the serious complications of retrobulbar intraconal anesthetic injection with a sharp needle, including loss of vision, apnea, and retrobulbar hemorrhage.

### 4. Conclusions

Due to the reliability and efficacy of this technique, we have largely abandoned retrobulbar intraconal injections using a sharp needle as a means of obtaining intraoperative local anesthesia for posterior segment surgery.

### Supplemental Video:

<http://www.youtube.com/watch?v=CT69NVVolOo>

### References

- [1] Rubin AP. Complications of local anaesthesia for ophthalmic surgery. *British journal of anaesthesia*. Jul 1995;75(1):93-96.
- [2] Hamilton RC. A discourse on the complications of retrobulbar and peribulbar blockade. *Canadian journal of ophthalmology. Journal canadien d'ophtalmologie*. Dec 2000;35(7):363-372.
- [3] Hansen EA, Mein CE, Mazzoli R. Ocular anesthesia for cataract surgery: a direct sub-Tenon's approach. *Ophthalmic surgery*. Oct 1990;21(10):696-699.
- [4] Oetting, T. *Basic Principles of Ophthalmic Surgery*. Second edition. American Academy of Ophthalmology; 2011.
- [5] Kakizaki H, Takahashi Y, Nakano T, et al. Anatomy of Tenon's capsule. *Clinical & experimental ophthalmology*. Aug 2012;40(6):611-616.
- [6] Dombrow M, Elkomos G, Bhagat N. Sub-Tenon Anesthesia: An Efficacious and Safe Route for Pars Plana Vitrectomies. [abstract] *Investigative Ophthalmology & Visual Science* 2008; 49:E-Abstract 5985.
- [7] Winder S, Walker SB, Atta HR. Ultrasonic localization of anesthetic fluid in sub-Tenon's, peribulbar, and retrobulbar techniques. *Journal of cataract and refractive surgery*. Jan 1999;25(1):56-59.