

# Endometriosis in the Bartholin gland: A case report

**Ihssane Hakimi, Youssef Benabdejlil, Jaouad Kouach, Driss Moussaoui, Mohamed Dehayni**

Department of Gynecology-Obstetric, Military Training Hospital Med V, Rabat, Morocco

## Email address:

hakimihssane@gmail.com (I. Hakimi), youssefbenabdejlil@gmail.com (Y. Benabdejlil), kouach\_jaouad@yahoo.fr (J. Kouach), Moussaouidriss@yahoo.fr (D. Moussaoui), Mohamedehayni@gmail.com (Md. Dehayni)

## To cite this article:

Ihssane Hakimi, Youssef Benabdejlil, Jaouad Kouach, Driss Moussaoui, Mohamed Dehayni. Endometriosis in the Bartholin Gland: A Case Report. *Journal of Gynecology and Obstetrics*. Vol. 2, No. 5, 2014, pp. 75-76. doi: 10.11648/j.jgo.20140205.12

**Abstract:** We report a case of endometriosis infiltrating the Bartholin gland. The initial diagnosis was a Bartholin gland cyst. The diagnosis was made during the operation when chocolate-colored fluid poured into operation field. The presence of endometriosis may be considered as a diagnosis in cases with cystic mass in the Bartholin gland. It's a rare case. Indeed, only few cases are reported in the literature.

**Keywords:** Endometriosis, Bartholin Gland

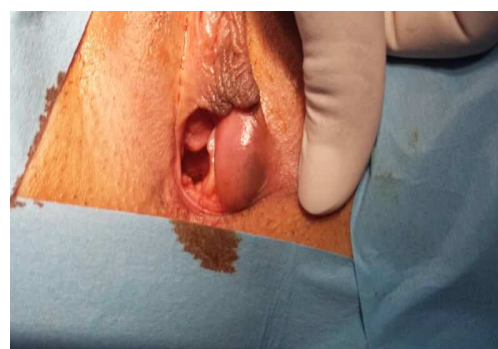
## 1. Introduction

Endometriosis is a common gynecologic disorder, affecting 1–7% of the population, 21% of infertile women, and 10% of 30–40-year-old women [1–3]. Endometriosis most commonly affects the pelvic peritoneum close to the ovaries, including the uterosacral ligaments, the ovarian fossa peritoneum and the peritoneum of the cul-de-sac [4]. Clinically, endometriosis is a ubiquitous disease and may cause both intra- and extra-genital symptoms. Endometriosis in the Bartholin gland is rare [1]. Endometriosis of vulva and perineum has been reported [5–8]. Matseoane et al. reported the first case of endometriosis in the Bartholin gland [9]. The authors report another case of endometriosis presenting within the Bartholin gland in the literature.

## 2. Observation

Mrs. RT, 28 years old, married, with no medical and family history, nulligravida, with regular menstrual cycles, using oral contraceptive since she got married, was referred by her general practitioner for a swelling in her left labium majus 7 months ago. That swelling appeared to be more prominent during menses. Pelvic examination revealed a 4 cm x 6 cm cystic mass in the left Bartholin gland (Figure 1). The uterus was regular and normal size. Ovaries and uterus were normal on ultrasonographic examination. We considered the Bartholin gland cyst and planned to perform cystectomy for Bartholin cyst under spinal anesthesia. During the operation, the dissection was difficult. The cyst

wall was ruptured and a chocolate-colored content poured into operation field. Microscopically, endometrial gland and stroma, fibrosis and hemosiderin deposits were seen. The final diagnosis was an endometriosis of the Bartholin gland. The patient received 6 months of treatment with *Luteinizing Hormone Releasing Hormone (LHRH)* analogues with good evolution.



**Figure 1.** Cystic mass in the left Bartholin gland

## 3. Discussion

Endometriosis is a disease characterized by the presence of functioning endometrial tissue at sites other than the uterine cavity. Current evidence suggests that ectopic endometrium usually results from transplantation of viable endometrial tissue, which is shed in retrograde manner through the fallopian tube at the time of menstruation (Sampson's theory) [10]. Factors that may favor intraperitoneal growth of viable endometrium have not

been identified, although impaired cellular immunity as well as increased exposure to retrograde menstruation may play a role. Hematogenous and lymphatic spread, direct implantation, and transformation of totipotent mesothelial cells (Meyer's theory) [11] undoubtedly contribute a minority of cases to the overall incidence. The origin of endometriosis in extra abdominal pelvic sites is not fully understood. Direct extension of endometriosis along the round ligament from preexisting pelvic endometriosis can explain endometriosis of the labia majora. An isolated focus of endometriosis in the Bartholin gland can, theoretically, be the result of coelomic metaplasia, lymphatic and/or vascular spread. Hormonal stimulation can result in the growth of endometrial fragments that have reached the Bartholin gland via menstrual discharge. Pelvic lesions are the main common sites of occurrence, but endometriosis also occurs at extra-pelvic sites and in these cases patients' symptoms are determined by the localization and not by the size of the lesions. Endometriosis at extra-pelvic sites often causes unusual symptoms. Sometimes typical catamenial pains also occur, with cyclical symptoms in 50% of patients [12], such as menstrual variability in size and tenderness of the mass.

These are often unrecognized by the physicians and a correct preoperative diagnosis cannot be made in all of cases. In our case, we had not recognized until during the operation because endometriosis was not suspected. The diagnosis of extra-pelvic endometriosis is frequently incidental, or is made at histologic examination [12,13] as we have seen in our case.

Although rare, Bartholin gland endometriosis should always be borne in mind when women of reproductive age have a presumptive diagnosis of Bartholin cyst especially if it is associated with menstrual variability in size and pain. In fact, there is not a real way to prevent this rare location of endometriosis [12].

## 4. Conclusion

The presence of endometriosis should be considered as a possible diagnosis in cases with a cystic mass in the labium majus in a woman, especially if it is associated with menstrual variability in size.

## References

- [1] Mahmood TA, Templeton A. The impact of treatment on the natural history of endometriosis. *Human Reprod* 1990 Nov;5(8):965–70.
- [2] Barbieri RL. Etiology and epidemiology of endometriosis. *Am J Obstet Gynecol* 1990 Feb;162(2):565–7.
- [3] Tran KT, Kuijpers HC, Willemsen WN, Bulten H. Surgical treatment of symptomatic rectosigmoid endometriosis. *Eur J Surg* 1996 Feb;162(2):139–41.
- [4] Nisolle M, Paindaveine B, Bourdon A, Berliere M, Casanas-Roux F, Donnez J. Histologic study of peritoneal endometriosis in infertile women. *Fertil Steril* 1990 Jun;53(6):984–8.
- [5] Binder SS. Endometriosis of vulva and perineum: report of a case. *Pacif Med Surg* 1965 Sept-Oct ;73(5):294–6.
- [6] Mahmud N, Kusuda N, Ichinose S, Gyotoku Y, Nakajima H, Ishimaru T, Yamabe T. Needle aspiration biopsy of vulvar endometriosis. A case report. *Acta Cytol* 1992 Jul--Aug;36(4):514–6.
- [7] Irvin W, Pelkey T, Rice L, Andersen W. Endometrial stromal sarcoma of the vulva arising in extraovarian endometriosis: a case report and literature review. *Gynecol Oncol* 1998 Nov;71(2):313–6.
- [8] Bolis GB, Maccio T. Clear cell adenocarcinoma of the vulva arising in endometriosis. A case report. *Eur J Gynaecol Oncol* 2000;21(4):416–7.
- [9] Matseoane S, Harris T, Moscovitz E. Isolated endometriosis in a Bartholin gland. *N Y State J Med* 1987 Oct;87(10):575–6.
- [10] Sampson JA. The development of the implantation theory for the origin of peritoneal endometriosis. *Am J Obstet Gynecol* 1940;40:549.
- [11] Meyer R. Über den stand der adenomyositis und adenomyome im allgemeinen und insbesondere über adenomyositis serosepithelialis und adenomyometritis sarcomatosa. *Zbl Gynak* 1919;43:745.
- [12] Singh KK, Lessells AM, Adam DJ, Jordan C, Miles WF, Macintyre IM, Greig JD. Presentation of endometriosis to general surgeons: a 10-year experience. *Br J Surg* 1995 Oct;82(10):1349–51.
- [13] Cristalli B, Raguin E, Nos C, Heid M, Levardon M. Inguinal hernia and endometriosis. *J Gynecol Obstet Biol Reprod (Paris)* 1993;22(2):149–50.