

Case Report

Application of Intra-Orbital Septal Transfer of Lateral Orbital Septal Pedicled Fat Flap in the Treatment of Upper Eyelid Dents

En-Jing Wang , Bin Xu*

Department of Plastic Surgery, Yang Zhong People's Hospital, Zhenjiang, China

Abstract

Objective: To observe the clinical effect of intraorbital septal transfer of the lateral upper eyelid mass and orbital septum pedicled fat flap in the treatment of upper eyelid depression. **Method:** During the double eyelid surgery, the fat mass on the lateral side of the upper eyelid was exposed, a small incision was made on the outside of the orbital septum, the fat in the orbital septum was released, the blood vessels on the inside of the root of the fat mass were preserved, and the fat was sharply separated from the outside to the inside. The mass is trimmed into a strip-shaped pedunculated fat flap. A small lateral incision is made along the lateral side to separate the medial fat mass in the orbital septum. The separated fat flap is refilled into the orbital septum from the lateral incision and pulled to the medial side for fixation. **Results:** 33 patients were followed up for 3 to 12 months after surgery. Except for 1 patient with severe upper eyelid skin laxity who underwent surgical repair, the rest of the patients' upper eyelid depression was effectively relieved and the upper eyelids looked natural. The patients were satisfied with the surgical results. **Conclusion:** The intra-orbital septum transfer of the lateral upper eyelid mass and orbital septum pedicled fat flap is a simple and effective surgical method for the treatment of upper eyelid depression, with less pain and quick recovery. It is worth recommending in the treatment of upper eyelid depression.

Keywords

Upper Eyelid Depression, Autologous Fat, Pedicled Fat Flap

1. Introduction

Upper eyelid depression mainly occurs at the upper eyelid margin below the eyebrow arch and is one of the important manifestations of facial aging. Thinning of the orbital supporting tissue and shrinkage of the volume tissue are the main causes of upper eyelid thinness [1]. The lack of fullness in the upper eyelid area can cause the loss of skin support structures, further accelerating the relaxation of the eyelid skin [2]. Among them, orbital fat has the most significant impact on the fullness of the upper

eyelid [3]. With the improvement of people's living standard and the continuous improvement of aesthetic requirements, in clinical practice, we found that young patients with mild upper eyelid depression are more common. The traditional treatment method is fat filling [4-8], mainly autologous particle fat injection and free fat flap transplantation. Autologous granule fat will inevitably cause some damage and pain to other parts of the body during the process of extraction. The problem of survival and

*Corresponding author: 375364072@qq.com (Bin Xu)

Received: 10 January 2024; **Accepted:** 31 January 2024; **Published:** 20 February 2024



Copyright: © The Author(s), 2024. Published by Science Publishing Group. This is an **Open Access** article, distributed under the terms of the Creative Commons Attribution 4.0 License (<http://creativecommons.org/licenses/by/4.0/>), which permits unrestricted use, distribution and reproduction in any medium, provided the original work is properly cited.

inpersistence of autologous particle fat injection has long plagued plastic surgeons. The free fat flap often leads to the dispersion of fat particles and the liquefaction of fat after transplantation caused by the pruning process, and the swelling is obvious in the short term after surgery and the postoperative effect is often unsatisfactory. Compared with free fat transplantation, intraorbital transposition of autogenous pedicled orbital septal fat can translocate the drooping lateral orbital septal fat to the upper eyelid depression. The pedicled fat flap can be used to increase the survival rate of fat and maintain the fat's survival rate. Softness to achieve better filling effect.

2. Materials and Methods

2.1. Clinical Data

There were a total of 133 patients in this group from March 2020 to December 2023, all of whom were female, aged 35-45 years old. 18 cases were followed up within 6 months after surgery, and 115 cases were followed up within 6-12 months; all were Bilateral.

2.2. Surgical Methods

2.2.1. Preoperative Design

Improve various routine preoperative examinations, eliminate surgical contraindications, inquire about surgical history, exclude patients who have undergone lateral orbital septum fat removal surgery, check that the skin in the surgical area is free of redness, swelling, ulceration and inflammation, and avoid menstrual periods for female patients. The patient takes a sitting position to mark the upper eyelid depression range and design a double eyelid incision.

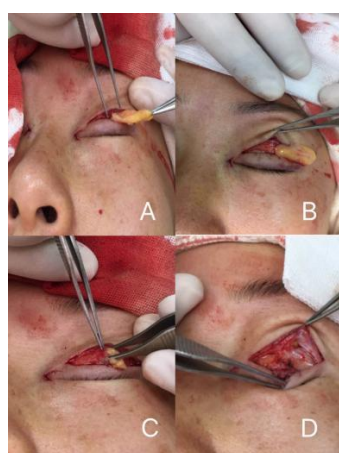


Figure 1. Surgical procedure of Intra-Orbital Septal Transfer of Lateral Orbital Septal Pedicled Fat Flap. A: A small 2-3mm incision was made in the lateral orbital septum with orbital septum fat bulge; B: Trim fat into long strips, while the medial vascular pedicle is preserved; C: pull the formed fat flap inward from the small incision; D: Confirm fat filling on the inner side.

2.2.2. Surgery Process

Double eyelid surgery was performed as usual, the orbital septum was exposed, and a small 2-3mm incision was made on the lateral orbital septum, and the orbital septum fat was bulging. The orbital septum fat is pulled out through a small incision, and 2% lidocaine is injected to relieve the discomfort caused by the orbital septum fat being pulled. After the orbital septal fat is completely exposed, the fat mass is trimmed into a long strip, while the medial vascular pedicle is preserved. Use vascular forceps to gently separate the orbital septum from the small incision inward along the orbital septum to the innermost side, and then pull the formed fat flap inward from the small incision to fill the upper eyelid depression. Observe that the bilateral eye sockets and double eyelids are basically symmetrical, and suture the levator aponeurosis and incision skin with 7-0 nylon suture. Apply chlortetracycline eye ointment to the surgical area, apply appropriate pressure bandage with sterile gauze, and the operation is completed. The dressing was changed on the second day after the operation, and the blood scab was washed with normal saline. The incision was kept clean and dry after the operation, and the sutures were removed after 7 days.

3. Result

None of the 133 patients in this group suffered postoperative complications such as wound infection, hematoma, and local induration. All 133 patients were followed up for 6 to 12 months. One patient with severe upper eyelid skin laxity underwent surgical repair and the double eyelid width was redesigned. In the remaining patients, the upper eyelid depression was effectively alleviated and the upper eyelids appeared natural. The patients were satisfied with the surgical results.

4. Discussion

The main cause of upper eyelid thinness is the reduction of the volume of the upper eyelid content and the weakening of its supporting force; the atrophy, ptosis and retraction of orbital septum fat are the main reasons for the reduction of eye socket volume. As the patient ages, the medial group of orbital septum fat droops and shrinks severely, so the upper eyelid depression is often more severe in the medial position [9]. For the reduction of orbital tissue volume, the traditional response method is mainly free fat filling. However, fat filling has two disadvantages. First, the amount of fat filling is often difficult to control, and multiple fillings are often required to gradually correct it; second, after free fat filling, there is a clear boundary between the cellulite and the periorbital tissue, and the texture is hard and difficult to close the eyes. There is an obvious bulge in the eyes. In view of the weaknesses after free fat transplantation, we designed the intra-orbital septal fat flap transposition of lateral orbital septal fat. Orbital septum fat is

a homogenous tissue for the upper eyelid region, with consistent physiological functions, anatomical structure, easy sampling, and minimal trauma. It is the preferred transplant tissue, and the postoperative local morphology is good, without local unevenness [10]. During double eyelid surgery, the orbital septum fat is released and trimmed into a long strip of pedicled fat flap, and then the orbital septum fat is drawn medially and filled along the orbital septum. The orbital septum fat that should have been discarded is made into a pedicled fat flap to fill in the upper eyelid depression, thereby improving the shape of the upper eyelid. The pedicled fat flap is easy to survive in the orbital septum, avoids the process of fat absorption after surgery, and has small morphological changes. When the range of the orbital septum cannot reach the medial side, an incision can be made on the medial side of the orbital septum, the fat flap can be pulled out and placed behind the orbicularis oculi muscle, which can achieve better results while fixing the fat flap.

There are many methods of applying autologous fat filling to treat sunken upper eyelids [11-17]. Most of them require fat to be extracted from other parts of the body and then injected to fill the upper eyelids. It not only increases unnecessary trauma, increases patient pain, and prolongs the postoperative recovery period, but also creates the risk of vascular embolism during injection. The fat particles in other parts of the body are somewhat different from the fat particles in the upper eyelid orbital septum in terms of size and properties. Even the orbital septal fat in the lower eyelid bag is different from the fat particles in the upper eyelid orbital septum in terms of particle size and properties. Fat is very similar, but due to the lack of vascular nutritional support, the survival rate after transplantation will also affect the doctor's judgment on the amount of filling during surgery. Upper eyelid hyaluronic acid and hyaluronic acid filling are also good materials to solve the upper eyelid depression. When the amount of fat in the orbital septum is insufficient, it can be a better choice for filling the upper eyelid depression.

5. Conclusions

Intraorbital transfer of lateral orbital septal pedicled fat flap for the treatment of upper eyelid depression has the advantages of safety, effectiveness and few complications. The shape of the upper eyelid can be improved by improving part of the surgical steps in the conventional heavy eyelid surgery, especially suitable for patients with the upper eyelid depression caused by the upper eyelid aging. Satisfactory results were obtained in postoperative recovery time, correction effect of upper eyelid depression and patient experience.

Conflicts of Interest

The authors have no financial interest to declare in relation to the content of this article.

References

- [1] Lee S, Yen M T. Nonsurgical rejuvenation of the eyelids with hyaluronic acid gel injections [J]. *Semin Plast Surg*, 2017, 31(1): 17-21. Ciuci P M, Obagi S. Rejuvenation of the periorbital complex with autologous fat transfer: current therapy [J]. *Oral Maxillofac Surg*, 2008, 66(8): 1686-1693.
- [2] Lee H, Park M, Lee J, et al. Histopathologic findings of the orbicularis oculi in upper eyelid aging: total or minimal excision of orbicularis oculi in upper blepharoplasty [J]. *Arch Facial Plast Surg*, 2012, 14(4): 253-257.
- [3] Chun P, Yu S, Qin H, et al. The use of p45 plastination technique to study the distribution of preseptal and preaponeurotic fat tissues in Asian eyelids [J]. *Cell Biochem Biophys*, 2015, 73(2): 313-321.
- [4] Lin T M, Lin T Y, Chou C K, et al. Application of microautologous fat transplantation in the correction of sunken upper eyelid [J]. *Plast Reconstr Surg Glob Open*, 2014, 2(11): e259.
- [5] CHE D H, Lee L, Liu L. Clinical Effect of Nanofat Transplantation in the Treatment of Upper Eyelid Depression [J]. *Chinese Journal of Aesthetic Medicine*, 2021, 30(3): 11-13.
- [6] Tamboli D, Mancini R. Hyaluronic acid gel injection for multiple eyelid folds in asian eyelids: a novel approach [J]. *Ophthalmic Plast Reconstr Surg*, 2016, 32(4): 310-312.
- [7] YIN Y, Lee T, WONG S P. The Clinical Efficacy of Platelet-rich Plasma Combined with Non-crosslinked Sodium Hyaluronate Solution in the Treatment of Upper Eyelid Depression [J]. *Chinese Journal of Aesthetic Medicine*, 2020, 29(10): 6-10.
- [8] Gao L, Xu S, Lee J C. Clinical Application of Preoperative Accurate Grafting Measurement of Autogenous Fat Transplantation in the Correction of Upper Eyelid Depression [J]. *Chinese Journal of Aesthetic Medicine*, 2020, 29(2): 6-9.
- [9] Watanabe M, Buch K, Fujita A, et al. MR relaxometry for the facial ageing assessment: the preliminary study of the age dependency in the MR relaxometry parameters within the facial soft tissue [J]. *Dentomaxillofac Radiol*, 2015, 44(7): 20150047.
- [10] Gong Z X. Application of two different surgical methods in single eyelid with mild sunken upper eyelid [J]. *China Medical Cosmetology*, 2023, 13(6): 1-3. <https://doi.org/10.19593/j.issn.2095-0721.2023.06.001>
- [11] Chen Hui, Zhang Qian, Qiu Qiu, et al. Autologous fat graft for the treatment of sighted posttraumatic enophthalmos and sunken upper eyelid [J]. *Ophthalmic Plast Reconstr Surg*, 2018, 34(4): 381-386. <https://doi.org/10.1097/IOP.0000000000001028>
- [12] ZHU J W. Analysis of Clinical Application and Esthetic Effect in Patients with Sunken Upper Eyelid by Orbicularis Muscle Flap Combined with Septum Orbitale Fat Flap Method [J]. *Chinese Journal of Aesthetic Medicine*, 2018, 27(4): 3. <https://doi.org/CNKI: SUN: MRYX.0.2018-04-017>
- [13] LEYNGOLD I M, BERBOS Z J, MCCANN J D, et al. Use of hyaluronic acid gel in the treatment of lagophthalmos in sunken superior sulcus syndrome [J]. *Ophthalmic Plast Reconstr Surg*, 2014, 30(2): 175-179. <https://doi.org/10.1097/IOP.0000000000000040>

- [14] Yu C G, Lee Z X. Clinical effect of multi-level injection of nano-fat injection to correct the depression of upper eyelid [J]. Chinese Journal of Medical Aesthetics and Cosmetology, 2021, 27(3): 3. <https://doi.org/10.3760/cma.j.issn.1671-0290.2021.03.003>
- [15] Lin X L, Jin H, Wang J Q. Curative effect of dermofat flap in treatment of the moderately or severe upper eyelid depression [J]. Chinese Journal of Aesthetic and Plastic Surgery, 2016(5): 3. <https://doi.org/10.3969/j.issn.1673-7040.2016.05.004>
- [16] Sun S W, Ma J, Yu X F, Application of Dermofat-orbicularis Oculi Muscle Combined Flap in Correction of Sunken Upper Eyelid [J]. Chinese Journal of Aesthetic Medicine, 2020, 29(8): 3. <https://doi.org/CNKI: SUN: MRYX.0.2020-08-005>
- [17] Chen T, Tian T, Chen N X. Clinical observation for the hyaluronic acid filling eyelid depression with unsatisfactory double eyelid [J]. China Medical Cosmetology, 2021, 11(10): 3. <https://doi.org/10.19593/j.issn.2095-0721.2021.10.003>