



Review Article

Optical Coherence Tomography Angiography to Detect and Differentiate Ischemic Optic Neuropathy from Papilledema - Systematic Review

Manuel Augusto Pereira Vilela^{1,2}, Carina Graziottin Colossi²

¹Medical School, Federal University of Health Sciences, Porto Alegre, Brazil

²Ivo Corrêa-Meyer Institute, Porto Alegre, Brazil

Email address:

mapvilela@gmail.com (M. A. P. Vilela)

To cite this article:

Manuel Augusto Pereira Vilela, Carina Graziottin Colossi. Optical Coherence Tomography Angiography to Detect and Differentiate Ischemic Optic Neuropathy from Papilledema - Systematic Review. *International Journal of Ophthalmology & Visual Science*. Vol. 4, No. 4, 2019, pp. 66-70. doi: 10.11648/j.ijovs.20190404.12

Received: August 1, 2019; **Accepted:** September 25, 2019; **Published:** October 10, 2019

Abstract: Background: Optic disc is a region with a complex vascular stratification, with components from the posterior ciliary arteries and central retinal artery. Nonarteritic anterior ischemic optic neuropathy (NA-AION) and papilledema can produce disc edema and visual fields defects. Optical coherence tomography angiography (OCTA) can aid in the rapid differentiation of cases when signals overlap. Objective: The purpose of this systematic review is to discuss the current information concerning the signs in OCTA that eventually could help to differentiate these situations and analyze the best diagnostic evidence. Methods: A systematic search was conducted in the MEDLINE ("Medical Literature Analysis and Retrieval System Online") via Pubmed; Embase, Scopus, Web of Science, Google Scholar, BVS databases, in addition to a manual search on studies published, from inception until July 2019, with no language restriction. Results: Of the 20935 articles identified, eleven were included. Different methodologies, sample characteristics, types of equipment, potential artifacts, segmentation errors were the main arguments against formal meta-analysis. Conclusion: The main differentiation of papilledema from NA-AION is the vascular dropout. Density values in both retina and optic nerve head images were significantly lower in NA-AION. These vascular changes appears to precede detectable structural or visual field damage.

Keywords: Ischemic Optic Neuropathy, Optical Coherence Tomography Angiography, Papilledema

1. Introduction

Optical coherence tomography angiography (OCTA) has been recently used for rapid analysis of normal capillaries and abnormal neovessels distribution on the retina and optic nerve (ON). It is important to verify if OCTA really offers comparative or better conditions for the diagnostic differentiation between the papilledema and ischemic optic edema than the gold standard resources like intravenous fluorescein angiography (IVFA) or visual fields (VF).

A simple search at a database like Pubmed showed that: (1) there are a lot of publications related to OCTA (> 10.000) and optic disc edema (~ 6000); (2) the number is reduced with non-arteritic anterior ischemic optic neuropathy (NA-AION)

(~ 2800); but combined searches including OCTA and one of those specific situations found lower than 170 references. So the analysis of the optic disc with the OCTA for these situations is something new. [1]

About NA-NOIA the estimated prevalence is 2-10 cases/100.000 over 50 year old, with some well know related factors like Systemic Arterial Hypertension (50%), Diabetes mellitus (25%), Arterial Hypotension (nocturnal) and Atherosclerosis. The exact cause of this vascular compromise is unknow. Probably it is not an occlusive but much more a circulatory insufficiency of the distal system of the short posterior ciliary arteries (PCA)⁶. The risk for recurrence in the affected eye is less than 5%, but for the second eye could be 15% (much more in the arteritic anterior ischemic neuropathy - A-AION). There is a great variation

interindividual in the number and distribution of the PCAs. [2]

The clinical picture of ischemic optic neuropathy has characteristic signals: sudden, painless, monocular loss of vision with pale disc edema. Visual loss uses to be on awakening in a great number of cases. Progressive worsening in the first days is common but at the end, about 40% of the patients with 20/70 or better will improve a few lines. The watershed zones are vulnerable areas to ischemia, and some sector or diffuse filling defects are present. VF uses to show inferior nasal or altitudinal defects. [3] The structural OCT (B scan) delineates the edema specially on the RNFL. The management doesn't have an established treatment, except for the A-AION. One of the possibilities related to OCTA is to offers biomarkers for the prognosis or the involvement of the second eye. After a few days the ganglion cells complex (GCC) and the retinal nerve fiber layer (RNFL) could show thinning.

According to Hayreh - more than a 55 years ago - the pathogenesis of the papilledema is related to the abnormal pressure in the central serous fluid (CSF). [4] This will produce around the optic nerve sufficient compression and promote interruption of the axonal flow and edema. The progression of this edema will dilate or occlude the capillaries around the disc. Generally there is bilateral and asymmetric optic disc edema, and the intensity depends on the severity and duration of the ICH. Besides there are intermittent visual complaints and headache. VF shows enlargement of the blind spot. IVFA identify profuse leak on the disc and sometimes sectorial zones with dilated capillaries on the surface are recognized. These informations helps to make the differential diagnosis most of the times.

The purpose is to review the current information concerning the signs in OCT angiography that eventually could help to differentiate these situations and analyze the best diagnostic evidence.

2. Methods

This systematic review was conducted in accordance with Cochrane [5], PRISMA [6], ("Preferred Reporting Item for Systematic Reviews and Meta-Analysis"), and MOOSE [7] ("Meta-Analysis of Observational Studies in Epidemiology") criteria, and has been registered on the PROSPERO [8]

database ("International Prospective Register of Systematic Reviews"), and has been registered on the PROSPERO database (International Prospective Register of Systematic Reviews")

All articles published until July 2019 held on the MEDLINE ("Medical Literature Analysis and Retrieval System Online") via Pubmed; Embase, Scopus, Web of Science, Google Scholar, BVS databases were considered, with no language restriction. References used in the articles analyzed were taken in consideration.

All observational studies (cross-sectional, cohort, case-control) with patients at any age which had optic disc edema or ischemia evaluated by optical coherence tomography angiography were included.

The search used the MeSH terms "optical coherence tomography angiography", "optic disc edema", "papilledema", "ischemic optic neuropathy" or "anterior ischemic optic neuropathy", without methodological filters. The full search strategy is shown in Appendix.

The articles titles and abstracts were independently evaluated by the authors and disagreements were solved by consensus. We reviewed the full text of the selected articles. Risk of bias was assessed according to the Newcastle-Ottawa Scale [9]. This instrument comprises domains and analyze 1) patient selection, 2) comparability, and 3) outcome. All qualitative or quantitative characteristics of the studies were gathered. Meta-Analysis was not possible to perform due to the discrepancy in the methods of the studies. They have distinct methodology related to the inclusion or exclusion criteria, sample's characteristics, equipment used, potential artifacts, segmentations errors (automatic or manual) and the complementary informations took out from customizes softwares. These were the main arguments against formal meta-analysis.

3. Results

We identified 20935 studies, 11 of them were included in this analysis. Nine studies were related to NA-AION and 2 assessed optic disc edema. (Figure 1). The methodological quality of the studies is described in Table-1. All of them were considered like satisfactory studies.

Table 1. Risk of bias of includes studies.

Author	Selection			Comparability		Outcome	
	Representativeness	Size	Non-respondents	Risk factor		Assessment	Statistical test
Ghasemi- Falavarjani KG, et al ¹⁰	0	0	0	2	2	2	1
Ling JW, et al ¹⁸	0	0	0	1	2	2	1
Balducci N, et al ¹¹	0	0	0	1	1	2	1
Hata M, et al ¹²	0	0	0	2	2	2	1
Wright Mayes EW, et al ¹³	0	0	0	2	0	2	1
Augstburger E, et al ¹⁶	0	0	0	2	2	1	1
Song Y, et al ¹⁷	0	0	0	2	2	2	1
Gaier Ed, et al ¹⁴	0	0	0	2	2	2	1
Rebolledo G, et al ¹⁵	0	0	0	2	0	2	1
Fard MA, et al ¹⁹	0	0	0	1	0	2	1
Rougier MB, et al ²⁰	0	0	0	0	0	2	2

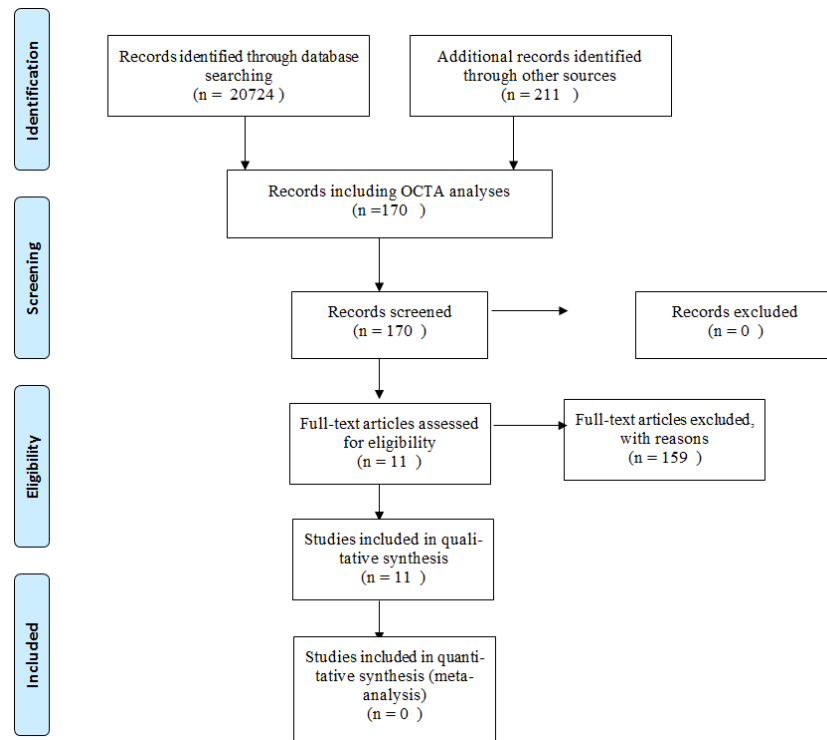


Figure 1. Study Flowchart.

There are 9 series recently published about OCTA and optic neuropathy and AION [10-18]. and two studies were related to the optic disc edema. [19, 20] All of them are small sampled size (~6-41 eyes) or (~ 5-30 patients) in NA-AION and (-25-44 eyes) or (-12-22 patients) in papilledema, and some of them are retrospective and without a control group. Mean age, time of diagnosis (acute ou non-acute), and gender had wide

variability. There were qualitative and quantitative analysis. The current knowledge is based on some of these conclusion. We have to watch out all the limitations. For example we must remember too that for the majority of the higher refractional situations (>6 D) and cataract patients were not evaluated. (table 2)

Table 2. Demographics and Objectives.

Author	Year	Eyes	n	Males (%)	Age (mean)	Control	Objectives
Ghasemi- Falavarjani KG, et al ¹⁰	2016	21	12	67	44.7	6	Qualitative description
Ling JW, et al ¹⁸	2017	14	14	43	59.76	12	Average non-perfusion areas; Mean defect correlation; Visual acuity correlation
Balducci N, et al ¹¹	2017	6	5	20	73.4	No	1. Dye angiography comparison; 2. Vessel density
Hata M, et al ¹²	2017	15	11	73	66.4	19	Quantitative analysis of perfusion; VF correlation
Wright Mayes EW, et al ¹³	2017	10	9	67	61.5	No	Qualitative description
Augstburger E, et al ¹⁶	2018	26	24	67	66.9	24	1. Quantitative analysis vessel density; 2. VF, B-OCT correlations
Song Y, et al ¹⁷	2018	41	30	40	55.5	30	Quantitative analysis of perfusion;
Gaier Ed, et al ¹⁴	2018	24	19	79	59.5	16	1. Quantitative analysis of perfusion; 2. VF correlation
Rebolleda G, et al ¹⁵	2018	6	6	83	72.5	10	Quantitative analysis of perfusion;
Fard MA, et al. ¹⁹	2018	20 (NA-AION) 39 (P)	20 (NA-AION) 20 (P)	70 64	56.1 40.8	48	1. Quantitative analysis of macular perfusion;
Rougier MB, et al ²⁰	2018	8 (NA-AION) 25 @	4 (NA-AION) 13 (P)	Nf	Nf	No	Qualitative and quantitative analysis

(%) percentage, (n) number of patients; (VF) visual field; (B-OCT) structural optical coherence tomography; (Nf) not found; (NA-AION)= nonarteritic ischemic optic neuropathy; (P) papilledema.

4. Discussion

It is essential to know the normal aspects of the OCTA on the disc. This is a region with a complex vascular stratification, that have components from the PCA and central retinal artery (CRA). The slabs permits a better visualization, and the observation of the flow signal helps to better define the doubts. The peripapillary capillaries are evident, most of time even with the existence of edema. This capillaries are dense, derived from the CRA and extends to the macular and temporal retinal vessels. The papillary capillaries at pre-laminar and laminar region are easiest to see, (only with great edema that can compress them) and depends on the slab we can see the coriocalillaries around the disc. [10]

The OCTA in NA-AION permits to visualize the boundary end extension of the non-perfusion in the ON - more than IVFA (leakage interferes). The vessels density can be measured and permits comparison in the long and with the second eye. Tortuous capillaries and telangiectasies sometimes are detected, probably a local response to hypoxia. In acute ou chronic disease the loss of superficial PCR and ON do not change, but the deep vessels density in the ON uses to reduce in the late stages. (almost 20% more affected). There is a good correlation between the perfusion and the VA, VF and structural OCT repercussions. The unaffected eye are not different from the controls, this is an indication that there is no predictive biomarker (like vessels densities) for these patients. [10-18] (Figure 2)

The main signals of optic disc edema in OCTA are (1) dilatation and tortuosity of the surface capillaries (ON and

peripapillary capillaries - RPC), like “tangled ball or bushy”; (2) possible dropout in the chronic stages or very severe edema causing compression or undetectable by the sluggish flow; (3) RNFL average and sectoral thickness are greater than control or other pseudopapilledemas. [10, 19, 20]

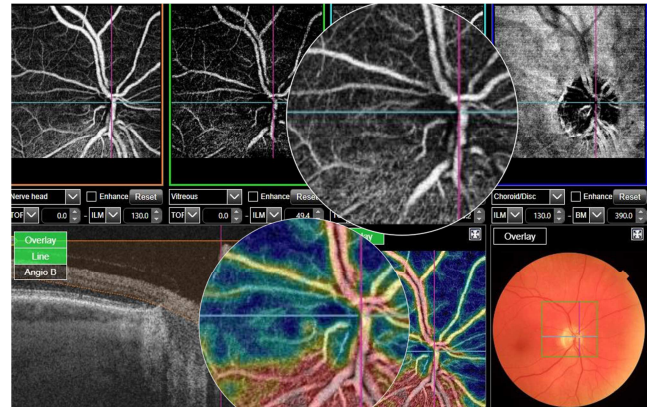


Figure 2. SS-OCTA of the optic disc showing vessels dropout in the upper half. Edema secondary to a ischemic optic neuropathy.

5. Conclusion

The main differentiation of papilledema from NA-AION is the vascular dropout. Density values in both RPC and ON head images were significantly lower in NA-AION. These vascular changes appears to precede detectable structural or visual field damage.

Appendix

Table A1. Full strategy used on databases.

Search	Add to builder	Query	Items found
#6	Add	Search optical coherence tomography angiography) AND OPTIC DISC EDEMA) AND papilledema	103
#5	Add	Search (optical coherence tomography angiography) AND anterior ischemic optic neuropathy AND ischemic optic neuropathy)	67
#11	Add	Search (ischemic optic neuropathy) AND anterior ischemic optic neuropathy	2746
#2	Add	Search (OPTIC DISC EDEMA) AND papilledema	5937
#1	Add	Search optical coherence tomography angiography	12041

References

- [1] <https://www.ncbi.nlm.nih.gov/pubmed/advanced>. Accessed 15/july/2019
- [2] Bioussé V, Newman NJ. Ischemic Optic Neuropathies. N Engl J Med (2015); 372 (25): 2428-36.
- [3] Hayreh SS. Ischemic optic neuropathy. Prog Retin Eye Res. (2009); 28 (1): 34-62.
- [4] Hayreh SS. Pathogenesis of oedema of the optic disc disc (papilloedema). A preliminary report. Br J Ophthalmol (1964); 48: 522-543.
- [5] Egger M, Davey-Smith G, Altman D. Systematic reviews in health care: meta-analysis in context. Philadelphia, John Wiley and Sons, 2008.
- [6] PRISMA. Preferred reporting items for systematic reviews and meta-analyses. Available from: <http://www.prisma-statement.org/index.htm>, cited 2019, July 15.
- [7] Stroup DF, Berlin JA, Morton SC, et al. Meta-analysis for observational studies in epidemiology: a proposal for reporting. Meta-analysis of Observational Studies in Epidemiology (MOOSE) group. JAMA (2000); 283: (12).
- [8] PROSPERO. International prospective register of systematic reviews. Available from: <http://www.crd.york.ac.uk/PROSPERO/> [cited 2019 July 15].

- [9] Wells GA, Shea B, O'Connell D. The Newcastle-Ottawa Scale (NOS) for assessing the quality of nonrandomized studies in meta-analysis. Ottawa: The Ottawa Hospital, 2000.
- [10] Ghasemi Falavarjani K, Tian JJ, Garcia GA, et al. Swept-source optical coherence tomography angiography of the optic disk in optic in optic neuropathy. *Retina* (2016); 36 Suppl 1: S168-S177. doi: 10.1097/IAE.0000000000001259.
- [11] Balducci N, Morara M, Veronese C, et al. Optical coherence tomography angiography in acute arteritic and non-arteritic anterior ischemic optic neuropathy. *Graefes Arch Clin Exp Ophthalmol* (2017); 255 (11): 2255-2261.
- [12] Hata M, Oishi A, Muraoka Y, et al. Structural and Functional Analyses in Nonarteritic Anterior Ischemic Optic Neuropathy: Optical Coherence Tomography Angiography Study. *J Neuroophthalmol* (2017); 37 (2): 140-148.
- [13] Wright Mayes E, Cole ED, Dang S, et al. Optical Coherence Tomography Angiography in Nonarteritic Anterior Ischemic Optic Neuropathy. *J Neuroophthalmol* (2017); 37 (4): 358-364.
- [14] Gaier ED, Gilbert AI, Rizzo JF, et al. Quantitative analysis of optical coherence tomographic angiography (OCT-A) in patients with non-arteritic anterior ischemic optic neuropathy (NAION) corresponds to visual function. *PLoS ONE* (2018); 13 (6): e0199793.
- [15] Rebolleda G, Díez-Álvarez L, García Marin Y, et al. Reduction of peripapillary vessel density by optical coherence tomography angiography from acute to the atrophic stage in non-arteritic anterior ischaemic optic neuropathy. *Ophthalmologica* (2018); 240 (4): 191-199.
- [16] Augstburger E, Zéboulon P, Keilani C, et al. Retinal and Choroidal Microvasculature in Nonarteritic Anterior Ischemic Optic Neuropathy: An Optical Coherence Tomography Angiography Study. *Invest Ophthalmol Vis Sci*. (2018); 59: 870-877.
- [17] Song Y, Min JY, Mao L, Gong YY. Microvasculature dropout detected by the optical coherence tomography angiography in nonarteritic anterior ischemic optic neuropathy. *Lasers Surg. Med* (2018); 50 (3): 194-201.
- [18] Ling J-W, Yin X, Lu, Q-Y, et al. Optical coherence tomography angiography of optic disc in non-arteritic anterior ischemic optic neuropathy. *Int j Ophthalmol* (2017); 10 (9): 1402-1406.
- [19] Fard MA, Sahraian A, Jalili J, et al. Optical coherence tomography angiography in papilledema compared with pseudopapilledema. *Invest Ophthalmol Vis Sci* (2019); 60: 168-175.
- [20] Rougier MB, Goff L, Korobelnik JF. Optical coherence tomography angiography at the acute phase of optic disc edema. *Eye Vis* (2018); 5: 15. doi: 10.1186/s40662-018-0109-y.