

Value of ^{18}F -FDG PET-CT and MR Fusion in Preoperative Diagnosis and Staging of Pancreatic Cancer

Yang Xiu-jin

Medical Image Diagnosis Center, Chongqing Panorama Hongling Medical Image Diagnosis Center Co., LTD, Chongqing, China

Email address:

yxj1991091009@163.com

To cite this article:

Yang Xiu-jin. Value of ^{18}F -FDG PET-CT and MR Fusion in Preoperative Diagnosis and Staging of Pancreatic Cancer. *International Journal of Medical Imaging*. Vol. 11, No. 2, 2023, pp. 30-33. doi: 10.11648/j.ijmi.20231102.12

Received: April 17, 2023; **Accepted:** May 8, 2023; **Published:** May 18, 2023

Abstract: *Background:* With the improvement of medical level, the incidence of some tumors decreased significantly; However, in the actual clinical work, it was found that the incidence and mortality of pancreatic cancer is increasing, and most of the findings are in the late stage, so the following studies have solved its current situation, so as to early detection, early treatment, improve the survival rate of patients; Secondly, better clinical staging, so as to reasonably select treatment methods. *Objective:* To use 18 fluoro-deoxyglucose (^{18}F -FDG) positron emission computed tomography (PET-CT) molecular metabolism imaging and MRI multi-parameter structure imaging, and then use different machine fusion technology to realize the comprehensive application of pancreatic cancer diagnosis and staging. *Methods:* A retrospective comparative study was conducted on 100 patients with pancreatic space occupying diagnosed in our center. All patients received enhanced MR Examination and ^{18}F -FDG PET-CT examination before surgery, and underwent different machine image fusion. *Results:* The sensitivity, specificity and accuracy of PET-CT and MRI in the diagnosis of pancreatic cancer were higher than those of PET-CT alone ($P < 0.05$). *Conclusion:* The PET-CT and MRI fusion technology can be used in the diagnosis of pancreatic cancer, which can be accurately staged and provide help for early clinical diagnosis and treatment.

Keywords: ^{18}F -FDG PET/CT, Pancreatic Cancer, MRI Imaging Technology, Different Machine Fusion

1. Introduction

With social progress, life changes, and the improvement of medical level, the incidence of some tumors has been significantly reduced; However, in clinical practice, the incidence and mortality of pancreatic cancer are constantly increasing, and most of the findings are in advanced stage. Due to the special location of pancreatic cancer, the early and middle stages of pancreatic cancer are mostly asymptomatic, difficult to detect; Most patients have ascites, jaundice, emaciation and other reasons to seek medical treatment, when it is found to be in the late stage, unable to be treated with surgery, the prognosis is very poor, easy to cause poor prognosis [1-2]. According to relevant data, the 5-year survival rate of pancreatic cancer is less than 10%. Even in developed countries, the 5-year annual rate of the United States and Japan is 6% and 7.8%, respectively, indicating a

very poor prognosis in the prompt period [3-4]. In addition, it has been reported in related literature that the 5-year survival rate of patients with tumor diameter less than 1cm can reach 100%, if timely surgical treatment and other adjuvant treatments are performed [5-6]. Therefore, early recognition and treatment of pancreatic cancer is of great significance. As a new technology, PET-CT and MRI different machine fusion technology can simultaneously fuse multiple MRI sequences with the help of molecular metabolism imaging, so as to provide the basis for accurate diagnosis of pancreatic tumors, so as to facilitate early detection and treatment, and improve the survival rate of patients. Secondly, better clinical staging, so as to reasonably select treatment methods [7-10]. In order to demonstrate the clinical value of this technology, 100 patients were analyzed in this study.

2. Data and Methods

2.1. General Information

100 patients with suspected pancreatic cancer admitted to our center from March 2018 to January 2022 were selected as the study objects. Among them, 66 were males and 34 were females; The age was (44.2±10.0) years.

2.2. Inclusion and Exclusion Criteria

Inclusion criteria: (1) asymptomatic patients; (2) patients with suspicious pancreatic space occupying indicated by ultrasonography, CT and MRI; (3) Tumor marker CA199 was elevated (≥ 35 U/ml). Exclusion criteria: (1) pregnant and lactating women; (2) severe abnormal liver and kidney function; (3) patients with jaundice; and (4) history of malignant tumor.

2.3. Methods

(1) Diagnostic equipment: GE Discovery 710 PET/CT scanner, GE Silent 3.0T Magnetic resonance scanner, GE Medical Imaging Software (AW Server 3.1).

(2) Scanning methods: All patients underwent 18 F-FDG PET-CT examination and enhanced MR Examination before surgery. a. PET-CT examination: Subjects fasted for 8h, and blood glucose was detected to make their fasting blood glucose lower than 6.9mmol/L; Then, the imaging agent was injected and the patient remained in repose for 40 minutes. Parameter setting: tube current: 150mA; Tube voltage: 120kV, layer thickness 3.27mm. Whole body PET/CT examination was performed, scanning from the crown of the

head to the symphysis pubis. b. After PET-CT scan, MR Enhanced scan was performed on the same empty stomach the next day for patients with suspected pancreatic cancer. After plain scan, 20ml glumine gadolinium penate injection with concentration of 0.5mmol/ml was injected intravenously, and the parameters were set as TR: 508ms, TE: 15.3ms. 400mm×455mm and matrix: 256×256 posterior axial position (T1 IDEAL, T2WI, fs-T2WI, DWI), coronary position (fs-T2WI), fs-T1WI lipid-enhanced scan, MR Arterial phase scan was performed after 30s delay; MR Parenchymal phase scan was performed 60s later; Wait 4min and perform MR Delayed phase scan.

2.4. Statistical Methods

SPSS20.0 software was used for data analysis, and $P < 0.05$ was considered as significant difference.

3. Results

3.1. Diagnosis

Surgical pathology showed that among the 100 patients, 94 were pancreatic cancer and 6 were benign tumors, as shown in Table 1.

3.2. Comparison of Diagnostic Efficacy of Different Examination Methods

Taking surgical pathology as the gold standard, the diagnostic efficacy of different machine fusion techniques of PET-CT and MR Was higher than that of single PET-CT examination ($P < 0.05$), as shown in Table 2.

Table 1. Examination results of different examination methods in 100 patients [example].

Diagnostic methods	Pathological diagnosis		Total
	Positive	Negative	
PET-CT diagnosis Positive	76	2	78
Negative	18	4	22
PET-CT and MR Positive heteromechanical diagnosis	92	0	92
Negative	2	6	8

Table 2. Comparison of diagnostic efficacy of different test methods (%).

Diagnostic methods	Sensitivity	Specificity	Accuracy
PET-CT diagnosis	80.84	66.66	80.01
18 F-FDG PET/CT and MR Different machine fusion diagnosis	97.86	100.00	98.01
χ^2	15.23	39.96	16.55
P	< 0.05	< 0.05	< 0.05

3.3. Typical Cases

A 48-year-old female with abdominal pain and bloating for more than half a year and weight loss for more than 2 months. The tumor index CA199 was slightly elevated, and the fixed powder enzyme was normal. PET/CT/MR Showed: Slightly longer T1 and slightly longer T2 signal shadows, slightly higher signal shadows on DWI, slightly lower signal shadows

on ADC (slightly limited diffusion), blurred adipose space around pancreatic head and neck, partially embedded superior mesenteric vein and portal vein, unclear boundary between distal splenic vein (confluence with portal vein) and lesions, and unclear boundary between distal splenic vein and descending duodenum. FDG uptake was significantly increased (SUVmax=12.03).

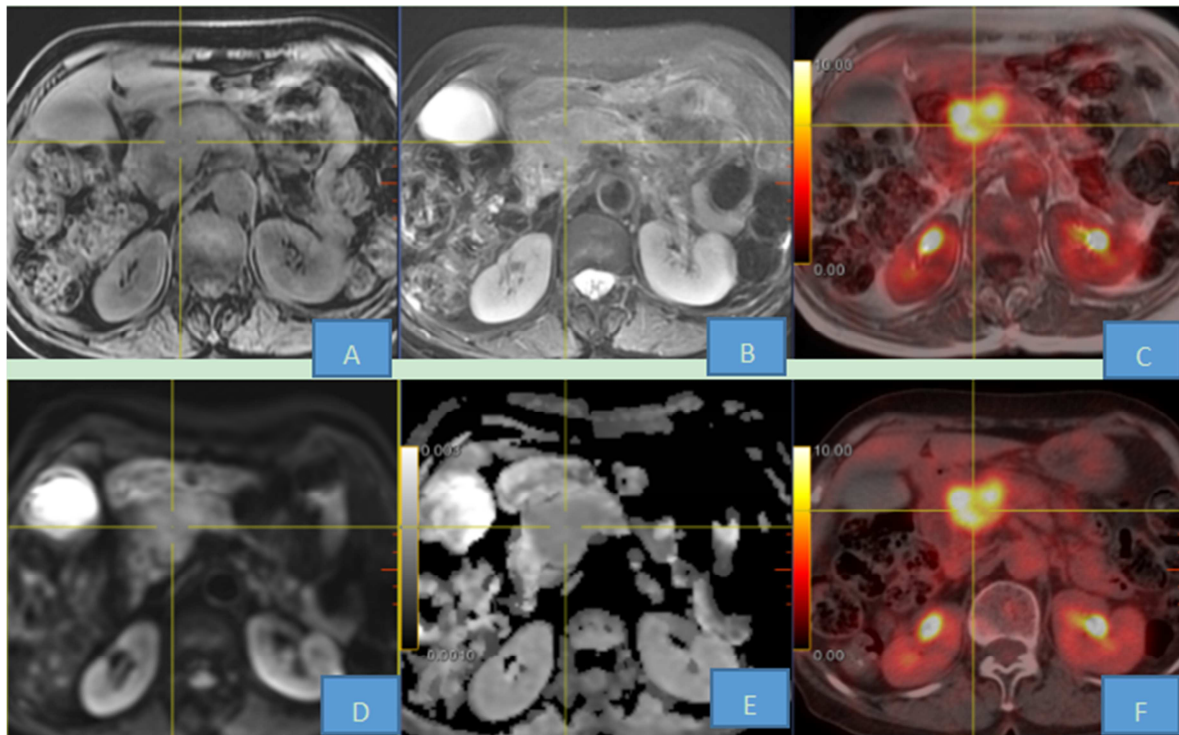


Figure 1. Typical cases of PET-CT and MRI fusion images.

Note: Images A and B are T1WI and fs-T2WI sequences, respectively. D and E are DWI and ADC sequences; C: fusion diagram of MR And PET; F is PET-CT fusion diagram.

4. Discussion

The onset of early and middle stage pancreatic cancer is insidious, and most of them have no obvious symptoms. The early diagnosis rate is low, and most of them are due to physical examination or high CA199. In all patients with jaundice, obvious emaciation or ascites, the tumor has already entered the advanced stage and the best opportunity for surgery is lost [11-12]. At present, the main auxiliary tests for the diagnosis of pancreatic cancer include: serum CA199 tumor marker, ultrasound, CT, MRI, PET/CT, PET/MRI, etc. Serum CA199 carbohydrate antigen has poor sensitivity to patients with early pancreatic cancer, and patients have entered the advanced stage when the tumor increases significantly. Therefore, it is only used as a screening reference; Due to factors such as abdominal fat and intestinal aeration, there may be a high probability of missed diagnosis in ultrasound examination, and it is difficult to characterize early pancreatic lesions by ultrasound alone. Therefore, CA199 tumor markers should be used as routine screening for patients undergoing physical examination [13]. Abdominal CT, as the current mainstream imaging auxiliary examination, has great advantages in the diagnostic staging of pancreatic cancer, especially in the surrounding soft tissue invasion and vascular conditions. However, its lack of specificity in the diagnosis of pancreatic cancer leads to limitations in the diagnosis of early pancreatic cancer. Therefore, the diagnosis of early pancreatic cancer needs more sensitive and specific

methods to improve the diagnostic efficacy [14-15]. As an image-assisted examination with rapid development in recent years, MRI, with its multi-parameter and multi-sequence scanning mode, combined with its dynamic enhancement curve and MRS Analysis, can significantly improve the diagnosis and differentiation of benign and malignant pancreatic cancer, especially for patients with tumor diameter less than 2cm. However, MRI alone cannot estimate the distant metastases, and its scanning time is longer. Some patients can not achieve long-term scanning, therefore, the evaluation of systemic metastasis has certain limitations [16-17]. PET-CT and PET-MRI, as high-end imaging equipment, are compatible with anatomical structure imaging and molecular functional imaging, providing a more accurate method for the early diagnosis of pancreatic cancer, and can also provide reference for distant metastasis of pancreatic cancer. However, due to the high cost of PET-MRI examination on the same plane, it is difficult for ordinary families to afford. Therefore, the application of different machine fusion technology of PET-CT and local MRI can not only improve the diagnostic efficiency, but also reduce the economic burden of patients [18-21].

In this study, the diagnostic sensitivity, specificity and accuracy of PET-CT and MRI were 97.86%, 100% and 98.01%, respectively, which were higher than that of PET-CT alone, and the difference between the two groups was statistically significant. The research methods were as follows: dynamic enhanced MRI scan was used to understand the peripheral invasion of pancreatic cancer, and T staging was

performed. Then PET-CT whole-body imaging was used to understand the whole body condition, whether there was lymph node metastasis, hematologic metastasis, and whether there was abdominal and peritoneal implantation for accurate staging of N and M. Make it comprehensively understand the patient's situation from the organizational structure and molecular level, play a decisive role in the diagnosis of benign, malignant and malignant stage of the lesion, so as to provide great help for clinical intervention.

In conclusion, in this study, the diagnostic efficacy of different machine fusion techniques of PET-CT and MRI was higher than that of CT, MRI and PET-CT alone, with statistical significance ($P < 0.05$). This study has promoted the implementation of ^{18}F -FDG PET-CT and MRI abnormal fusion technology, which is of great value and significance for the detection, diagnosis and staging of early pancreatic cancer. In order to better serve the clinic, the treatment pain of patients can be reduced and the survival rate of patients can be delayed.

References

- [1] Pan S B, Zhao H C, Xie K, et al. The value of enhanced CT and PET/CT in the diagnosis and staging of pancreatic cancer [J]. Hepatobiliary Surgery, 2013; 21 (6): 453-6.
- [2] Wei GH, Sun XG, Liu JJ, et al. The value of ^{18}F -FDG PET/CT in diagnosis and treatment of pancreatic malignant tumor [J]. Zhonghua He Yi Xue Yu Fen Zi Ying Xiang Za Zhi, 2009, 29 (1): 23-6.
- [3] Kikuyama M, Kamisawa T, Kuruma S, et al. Early diagnosis to improve the poor prognosis of pancreatic cancer [J]. Working (Basel), 2018, 10 (2): E48. DOI: 10.3390/cancers10020048.
- [4] Tang K, Lu W, Qin W, et al. Neoadjuvant therapy for patients with borderline resectable pancreatic cancer: a systematic review and meta-analysis of response and resection percentages [J]. Pancreatology, 2016, 16 (1): 28-37. DOI: 10.1016/j.pan.2015.11.007.
- [5] Ma Kaiqi, Xue Huanzhou, et al. Diagnostic value of MRI and PET-CT in early pancreatic cancer. Clinical Medicine, Jan. 2019, Vol. 39, No 1.
- [6] Heinrich S, Goerres GW, Schafer M, et al. Positron emission tomography/computed tomography influences on the management of resectable pancreatic cancer and its cost-effectiveness [J]. Ann Surg, 2005, 242 (2): 235-43.
- [7] Zheng Lichun, Zhang Wenjun, Liu Guichao, et al. Differential diagnosis of benign and malignant pancreatic lesions by PET / CT, MRI and combined application [J]. J Hebei Medical University, 2016, 37 (5): 562-566. (in Chinese) DOI: 10.3969/j.issn.1007-3205.2016.05.017.
- [8] Zhang WJ. Application of ^{18}F -FDG PET-CT in pancreatic cancer [D]. Beijing Xie He Yi Xue Yuan, 2012. (in Chinese)
- [9] Sperti C, Pasquali C, Decet G, et al. F-18 - fluorodeoxyglucose positron emission tomography in differentiating malignant from benign pancreatic cysts: a prospective study [J]. J Gastrointest Surg, 2005, 9 (1): 22-28. DOI: 10.1016/j.jassur.2004.10.002.
- [10] Peng Zhao-qiao, Bai Bo, WU Jing-ming, et al. PET+CT+MR "two-machine three-dimensional" image fusion based on body surface localization and its significance in orthopedic diagnosis [fJ/CD]. Chinese Journal of Joint Surgery: Electronic Edition, 2011, 5 (3): 350-357.
- [11] Tian Ming, Yan Jun, Hu Jinjing, et al. Prevalence and risk factors of pancreatic cancer [J]. Chinese Journal of Social Medicine, 2016; 33 (2): 137-40.
- [12] Bochatay L, Girardin M, Michard P, et al. Pancreatic cancer in 2014: screening and epidemiology [J]. Rev Med Suisse, 2014; 10 (440): 1582-5.
- [13] Li Fei, Fu Min. CA19-9, CEA and CA125 combined with B-ultrasound, enhanced CT and MRI in the diagnosis of pancreatic cancer [J]. Sichuan Med, 2013, 34 (7): 926-928. (in Chinese) DOI: 10.3969/j.issn.1004-0501.2013.07.014.
- [14] Zhang WW, Hao BL, Wang Z, et al. (18) The value of F-deoxyglucose PET /CT and enhanced CT in the differential diagnosis of pancreatic cancer [J]. Journal of Clinical Military Medicine, 2017, 45 (10): 1035-1038. DOI: 10.16680/j.1671-3826.2017.10.13.
- [15] Yu ZF, Fang Y, Zhang J, et al. Comparative study of ^{18}F -FDG PET/CT and contract CT in diagnosing and staging assessment of pancreatic cancer [J]. Yi Xue Ying Xiang Xue Za Zhi, 2013, 23 (8): 1236-40.
- [16] Wang ZG, Shi QX, Gui J, et al. Clinical Value of CA19-9, Chuang, 2014, 21 (5): 507-10.
- [17] Kauhanen S, Rinta-Kiikka I, Kempainen J, et al. Accuracy of ^{18}F -FDG PET/CT, Multidetector CT, and MR Imaging in the Diagnosis of Pancreatic Cysts: A Prospective Single-Center Study [J]. J Nucl Med, 2015, 56 (8): The 1163-8.
- [18] Nagamachi S, Nishii R, Wakamatsu H, et al. The usefulness of ^{18}F -FDG PET/MRI fusion image in diagnosing pancreatic tumor: comparison with ^{18}F -FDG PET/CT [J]. Ann Nucl Med, 2013, 27 (6): 554-63.
- [19] Salavati A, Saboury B, Alavi A, et al. Com ment on: tumor aggressiveness and patient outcome in cancer of the pancreas assessed by dynamic ^{18}F -FDG PET /CT [J]. J Nucl Med, 2014; 55 (2): 350-1.
- [20] Fang Y, Zhang J, Cui Y, et al. Value of dual-time-point ^{18}F -FDG PET/CT in differential diagnose of pancreatic disease [J]. Yi Xue Ying Xiang Xue Za Zhi, 2013, 23 (11): 1733-5.
- [21] Buchs NC, Buhler L, Bucher P, et al. Value of contrast-enhanced ^{18}F -fluorodeoxyglucose positron emission tomography/computed tomography in detection and presurgical assessment of pancreatic cancer: a prospective study [J]. J Gastroenterol Hepatol, 2011, 26 (4): 657-62.