



Assessment of Biochemical and Histopathological Effects of Crude Venom of Cone Snail *Conus flavidus* on albino Mice

Mona F. Abou-Elezz¹, Alaa Y. Moustafa², Mohamed S. El-Naggar^{1, *}

¹Zoology Department, Faculty of Science, Suez Canal University, Ismaillia, Egypt

²Zoology Department, Faculty of Science, Sohag University, Sohag, Egypt

Email address:

msemaenr@hotmail.com (M. S. El-Naggar)

*Corresponding author

To cite this article:

Mona F. Abou-Elezz, Alaa Y. Moustafa, Mohamed S. El-Naggar. Assessment of Biochemical and Histopathological Effects of Crude Venom of Cone Snail *Conus flavidus* on albino Mice. *International Journal of Ecotoxicology and Ecobiology*. Vol. 2, No. 1, 2017, pp. 33-44.

doi: 10.11648/j.ijee.20170201.15

Received: January 10, 2017; Accepted: January 19, 2017; Published: February 18, 2017

Abstract: The genus *Conus* is equipped with a unique venomous mixture of conopeptides which secreted for predation and defense purposes. This work is aiming to explore and determine the effect of the crude venom of *Conus flavidus*, a worm-hunting cone snail inhabiting the Red Sea, on the oxidant/ antioxidant system in mice using some oxidative stress biomarker assays. In addition to assess its histopathological effects on some treated organs. The LC₅₀ were detected for the crude venom using the hemolytic assay (16.7 mg/ml) and male albino mice were injected intraperitoneally with ½ LC₅₀ (8.3 mg/kg B.Wt). Biochemically, after 2, 4, 6, 12, 24 hours of injection the results revealed significant inhibition of superoxide dismutase (SOD) and catalase (CAT) activities in blood and liver in almost all time intervals comparing with control one. However, it showed elevation in lipid peroxide content (LPC), protein carbonyl content (PCC), nitric oxide level (NO) reduced glutathione content (GSH) and total antioxidant capacity (TAC) contents of both blood and liver in almost all time intervals. Histopathologically, liver and heart were dissected after 1, 3 and 7 days of injection. The treated liver showed vacuolar degeneration, karyolysis and pyknosis, mild blood sinusoidal congestion and centrilobular necrosis. The treated heart illustrated degenerated myofibrils, pyknosis, edema, blood vessel congestion, loss of striation normal construction and fascicular pattern in the myocardium. These results revealed that *C. flavidus* crude venom has distinct effects upon the oxidant/antioxidant cellular system and degenerative pathological effects in some tissues of treated animals, proving that this venom may contain bioactive peptides, which could be purified and used for further pharmacological and drug discovery investigations in the future.

Keywords: *Conus flavidus*, Hemolytic Assay, Antioxidants, Histopathological Changes, Red Sea

1. Introduction

Marine cone snails from the genus *Conus* are estimated to contain up to 800 species [1], each has evolved an apparatus that synthesize, store and eject a unique set of venomous cocktail contains molecular-diversified components, could reach 100 components in a single crude venom, almost all of them are short peptides (10-40 amino acids) known generally as conopeptides [2-6]. *Conus* species use their venoms not only in predation but also in defense and competition purposes. According to the preferred preys, these carnivorous snails could be classified into vermivorous species

molluscivorous and piscivorous species [7-8].

Over several millions of years, there was a strong evolutionary stress on these snails to compensate their slow movement and deprive of strong mechanical weaponry, to survive and capture their preys and defense. This is achieved through evolving strategies, including peptide folding and post-translational modifications, to produce powerful peptides that efficiently and rapidly a wide range of ion channels and signal transduction pathways of the envenomed prey nervous systems, causing immediate immobilization [8-9].

Although *Conus* genus is arguably the largest venomous single genus, there is highly interspecific variation in their conopeptide sequences, even between very closely related

species, leading to estimate an enormous number of different pharmacologically bioactive components in the whole genus, to be considered as wealthy treasure for developing new therapeutics for human medicine uses [10, 2, 7, 11]. For example, many promising candidates of ω -conotoxins use calcium ion channels as potential targets for novel therapeutics directed to ischemic brain damage, intractable pain, migraine and some forms of ataxia and epilepsy [12]. In 2004, ω -MVIIA from *C. magus* has been approved as a commercial drug (Prialt®) by FDA and EMA to treat intractable pain [13].

Although the vermivorous cone snails are the largest family of *Conus* genus, many bioactive conopeptides from molluscivorous and piscivorous, have been isolated and purified to be extensively studied in pharmacological and drug developing researches in the future. Because the mammalian receptors and ion channel isoforms quite close in sequence to that of the physiologically homologue in fish, and the genetic and evolutionary distances between human and worm is much greater [8]. In contrast, the vermivorous species have been rarely studied, even at recent studies few of studies have revealed a variety of novel conopeptides, some of them with potent neuropharmacological activity present only in worm-hunting cone snails [13-16]. It is thus reasonable to postulate that the vermivorous species might be equally promising pharmacological treasures [17].

The goal of this study is to explore the bioactivity, cytotoxicity effects of the crude venom of *Conus flavidus*, a widely and commonly distributed worm-hunting cone snails in the Red Sea, using a range of oxidative stress biomarker assays, antioxidant assays on the mammalian system. Moreover, to assess its histopathological alternations on some tissues (liver and heart) of the albino mice for further pharmacological advantages, mainly at pain killer drugs.

2. Materials and Methods

2.1. Venom Preparation

Specimens were collected from different locations of Red Sea, Egypt (Hurgada: 27°07'35"N 33°49'49"E, Al-Qusair city: 26°05'41"N 34°17'06"E and Marsa Alam: 25°05'49"N 34°52'48"E). Snails were collected at shallow depth (1.5 -2 m) using a special net stalk. Venom glands were dissected and crude venom was prepared as described by [18]. The dissected glands were smashed using liquid nitrogen and then suspended in 2 ml of 0.1% formic acid (Sigma-Aldrich) and then centrifuged (15,000 g, 10 min, 4°C). The pellet was re-extracted three times with 2 mL of 0.1% formic acid. The supernatants were pooled, and then lyophilized. The lyophilized pooled venom was stored at -25°C for further usage.

2.2. Experimental Animals and Ethics

Swiss Webster male albino mice (20–25 g) were housed in polyethylene cages (65 cm×25 cm×15 cm), under conditions of controlled humidity (22±2°C) and on a 12 h-light/dark

cycle, with free access to standard laboratory mice chow and water. All procedures relating to care and maintenance of the animals were in accordance with International Guiding Principles for Animal Research and were overseen and approved by the Suez Canal University Bioethics and Animal Ethics Committee.

2.3. Hemolytic Assay and LC₅₀ Determination

Erythrocytes were obtained from fresh human blood. For erythrocyte suspension, 18 mL of blood were divided in 9 tubes (2ml/tube) and centrifuged for five min. at 10000 rpm, and the plasma was discarded. Next, for each tube, 2 mL of saline solution (NaCl 150 mm) were added. The tubes were then centrifuged for five minutes at 4000 rpm. The supernatants were discarded and the process repeated three more times and the erythrocyte suspension ready for use. Ascending concentration series of *C. flavidus* venom was prepared (2, 2.5, 3, 3.5, 4, 4.5, and 5 mg/2ml saline). Each venom concentration was added separately to one of RBCs tubes. Negative control was employed by adding 2 ml Saline to one RBCs tube, while positive control was prepared of equal volume of sodium phosphate-buffered saline containing 2% (v/v) of the non-ionic detergent, Triton X-100 (Sigma–Aldrich). Then, all nine tubes were gently shaken and incubated for 120 minutes at 37°C. After 4000 rpm centrifugation, optical density of lysed red cells was spectrophotometrically measured at $\gamma = 550$ nm, and hemolytic activity was calculated according to the equation of [19].

$$\% \text{ hemolysis} = \frac{A - A_0}{AX - A_0} \times 100$$

Where 'A' is absorbance with venom treatments, 'A0' is absorbance with saline and 'AX' is absorbance with Triton X-100.

The LC₅₀ was calculated from the trend line equation of obtained standard curve of the hemolytic assay.

2.4. Cytotoxic Assays

30 adult mice were injected intraperitoneally with crude *C. flavidus* venom (8.3 mg/kg, 6 animals per group) and a range of assays to determine the cytotoxicity of the venom were carried out after 2, 4, 6, 12 and 24 h. post injection. A control group (6 animals) was injected with 0.9% NaCl.

2.4.1. Lipid Peroxidation Assay

Plasma lipid peroxidation was determined by the method of [20], by the reaction of thiobarbituric acid (Winlab, UK) with the breakdown products of peroxidized lipids (e.g. malonyldialdehyde) and spectrophotometrically measuring the absorbance of breakdown products at 532 nm. The results were expressed as nmol of malonyldialdehyde (MDA)/mL plasma. Malonaldehyde bis (dimethyl acetal) (Sigma) was used as an external standard.

2.4.2. Protein Carbonyl Assay

Plasma protein carbonyl content was measured according to [21]. Protein was precipitated with an equal volume of 1%

trichloroacetic acid (TCA) and the pellet was resuspended in 1 mL of 2,4- dinitrophenylhydrazide (DNPH (Sigma), 10 mM, dissolved in 2 N HCl). Samples were left at room temperature for 1 h in the dark and vortexed every 15 min. An equal volume of 20% TCA was added and after centrifugation (12,000 rpm, 1 min, 4°C), pellets were washed three times with 1 mL of an ethanol: ethyl acetate mixture (1:1) to remove the free DNPH. The final pellet was dissolved in 1 mL of 6 M guanidine and kept at 37°C for 1 h in a shaking water bath. The solution was centrifuged (12,000 rpm, 15 min) and the carbonyl content (nmol/mg), measured as protein phenylhydrazone derivatives, and was determined at 370 nm using an absorption coefficient of $22,000 \text{ M}^{-1} \text{ cm}^{-1}$.

2.4.3. Nitric Oxide

Nitric oxide (NO) was measured using the Griess reaction [22]. Plasma (100 μL) was mixed with an equal volume of Griess reagent (1 part 0.1% naphthylethylenediamine dihydrochloride in distilled water plus 1 part 1% sulfanilamide in 5% concentrated H_3PO_4), at room temperature for 10 min. The absorbance was measured at 540 nm. Sodium nitrite was used as a standard.

2.4.4. Reduced Glutathione

The content of blood (bGSH) and liver glutathione (lGSH) of control and treated mice was estimated according to the method of Biutler [23]. Aliquots of 0.2 mL of blood or tissue homogenate (mice liver tissues were homogenized in cold 0.15 M KCl at 0.25 g/mL) were added to 1.8 mL distilled water and 3 mL of precipitating solution (1.67 g glacial metaphosphoric acid, 0.2 g EDTA and 30 g NaCl in 100 mL distilled water). The mixture was then centrifuged (2200 rpm, 15 min, 4°C). One milliliter of supernatant was added to 4 mL Na_2HPO_4 (0.3 M) and 0.5 mL dithiobis-2-nitrobenzoic acid reagent (DTNB, Sigma-Aldrich) (40 mg DTNB in 100 mL 1% sodium citrate) and the absorbance was measured at 412 nm. Glutathione reduced form (Sigma) was used as a standard.

2.4.5. Cu/Zn Superoxide Dismutase and Catalase Activities

Superoxide dismutase (Cu/Zn SOD) activity was estimated in the lysate of EAC cells according to Misra and Fridovich [24]. The rate of inhibition of auto oxidation was monitored at 560 nm; the amount of enzyme required to produce 50% inhibition is defined as one unit of enzyme activity. SOD activity was expressed as units/mL. Catalase (CAT) activity was determined using the method of Aebi [25] Samples were prepared in phosphate buffer (50 mM, pH 7) and Triton-X 100 (1%, v/v) was added to increase the observable CAT activity by releasing the enzyme from peroxisomes [26]. CAT was measured by monitoring the decomposition of H_2O_2 at 240 nm. The enzyme activity was calculated using a molar extinction coefficient of 43.6 mol.

2.4.6. Total Antioxidant Capacity Assay

Total antioxidant capacity in blood plasma was measured spectrophotometrically according to the method of Koracevic

[27] The ability of antioxidants to inhibit the H_2O_2 -induced oxidation of 2,2-azinobis (3-ethylbenzothiazoline-6-sulphonate) (ABTS) was measured by the reduction in concentration of the cation radical ABTS^+ , absorbing at 600 nm and expressed as mmol/L.

2.4.7. Histopathological Examinations

In order to investigate the histopathological changes on liver and heart, 18 adult mice were injected intraperitoneally with crude venom of *C. flavidus* (8.3 mg/kg, 6 animals per group), then they were anesthetized, sacrificed, carefully dissected after 1, 3 and 7 days post injection. A control group of animals was injected with 0.9% NaCl. Small pieces of liver and heart were fixed in 5% formalin solution. They were then dehydrated in ascending grades of alcohol, cleared in clearing reagents and embedded in paraffin. Paraffin serial sections with thickness 7 μm were cut using microtome. Some sections were deparaffinized in xylene and hydrated in descending series of ethanol alcohol. Then stained with hematoxylin and eosin, mounted in DPX mounting media, and examined under light microscope (Axio Lab.A1, Carl ZEISS, Germany) equipped with AxioCamERc5s camera.

2.5. Statistical Analysis

SPSS® statistical software (v. 21.01 SPSS Inc., Illinois, USA) was used in all data analyses [28]. Differences in the effects of *Conus* venom between control and treated groups of mice were assessed using the Student's unpaired t-test [29]. One-way analysis of variance (ANOVA) followed by Duncan's multiple post-hoc test was performed to evaluate the eventual significant differences in the biochemical measurements between control and treated groups.

3. Results

3.1. Hemolytic Assay

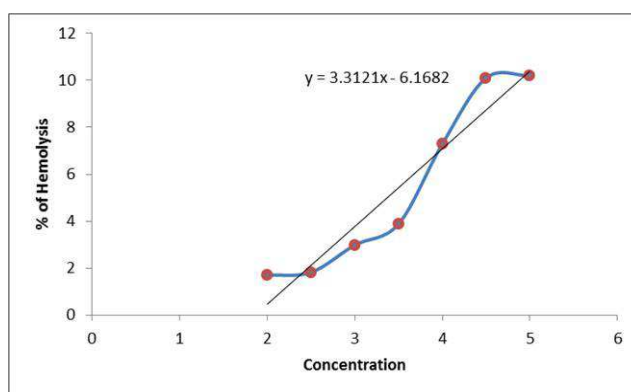


Figure 1. Percentage of in vitro hemolysis induced by different concentrations of *C. flavidus* crude venom.

In order to investigate the toxicity of crude venom of *C. flavidus*, in vitro hemolysis was evaluated by incubating an erythrocytes suspension of freshly-drawn human blood along with different concentrations of pooled venom, compared with the hemolysis of saline and triton X-100, and the

hemolytic activity was determined as hemolysis percentage (figure 1). The LC_{50} , which is the venom concentration required to produce 50% hemolysis, was calculated from the line equation of hemolysis curve, and its value was 16.682 mg/ml.

3.2. Effects of *C. flavidus* Venom on Oxidative Stress Biomarkers

In figure 2 (-A C) and table 1, all treated animal groups were intraperitoneally injected with $\frac{1}{2} LC_{50}$ (8.3 mg/ kg) of *Conus flavidus* venom in order to evaluate its effects on LPC, PCC and NO, respectively. Results in figure 2A illustrate the levels of plasma LPC in control and venom-treated groups at different time intervals (2, 4, 6, 12 and 24 h). It was noticed that the levels of LPC were significantly increased ($P \leq 0.05$) after 2 h. post-treatment as compared to the control values,

and the level of LPC then decreased at the rest of treated groups. The one-way ANOVA between treated groups revealed a highly significant difference ($F_{5,5} = 76.2$, $P \leq 0.05$) in the concentration of lipid peroxidation products. PCC concentrations in mice treated with both venom groups were significantly increased ($P \leq 0.05$) at all-time intervals with respect to the control groups (figure 2B). Significant differences in PCC were observed between the treated and control groups ($F_{5,5} = 39.1$, $P \leq 0.05$) using one-way ANOVA. In figure 2C, Toxic effects were quickly evident after injection with *C. flavidus* venom (significantly increased ($P \leq 0.05$) after 2 h. Levels of NO returned to control values after 12 h of venom injections. Levels of NO showed significant difference between the treated and control groups ($F_{5,5} = 10.1$, $P \leq 0.05$) using one-way ANOVA.

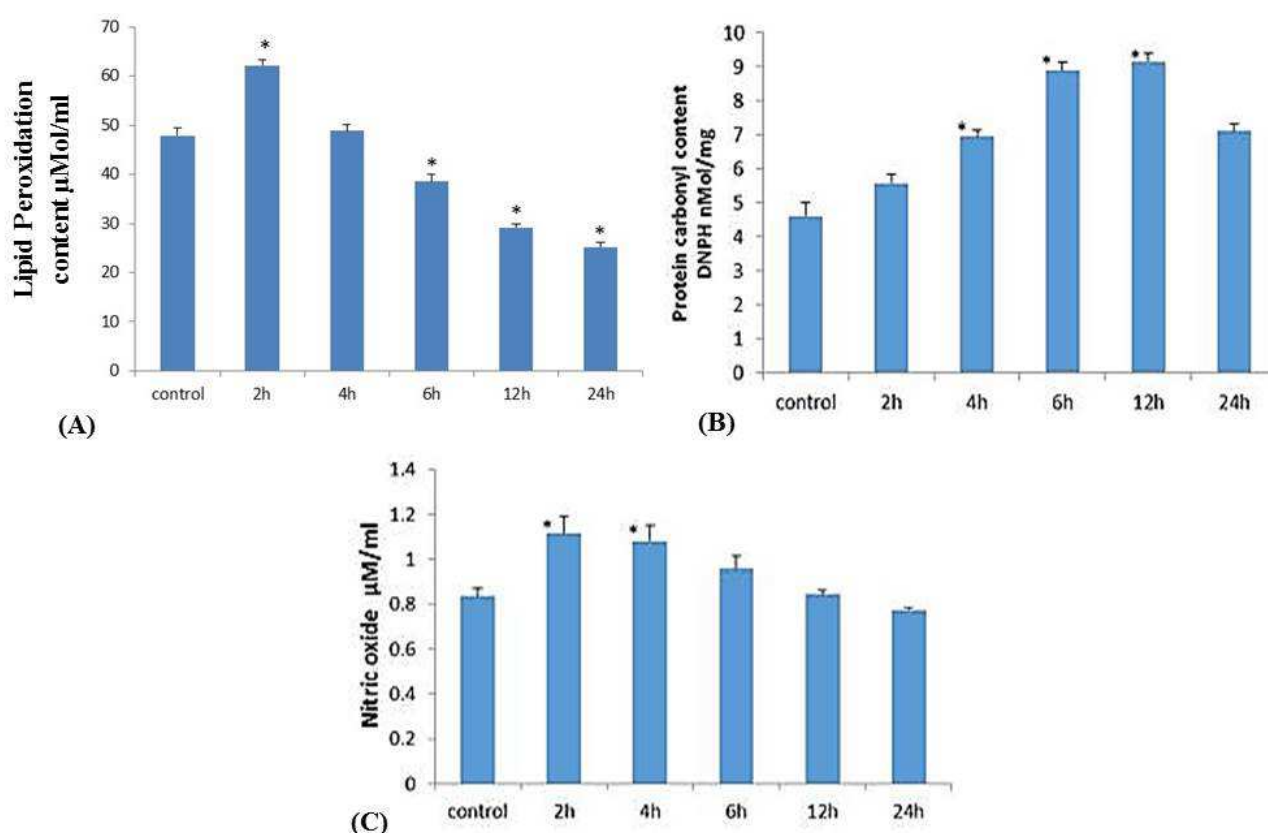


Figure 2. Effect of injected *C. flavidus* venom (8.3 mg/kg) on the level of lipid peroxidation (A), protein carbonyl content (B) and level of nitric oxide (C) of albino mice at different time intervals. (*) Significant difference between control and treated group using Student's unpaired t-test ($P \leq 0.05$).

Table 1. Change in Oxidative stress biomarkers levels after administration of *C. flavidus* venom (8.3 mg/kg).

Parameter	Control	Treated groups				
		2 h.	4 h.	6 h.	12 h.	24 h.
LPC	47.84±1.59 ^a	62.15±2.71* (+29.2%)	48.81±1.23 (+2.1%)	38.51±1.44* (-18.8%)	29.14±0.77* (-39.6%)	25.25±0.88* (-47.9%)
PCC	4.62±0.39	5.58±0.26 (+21.7%)	6.95±0.19* (+52.2%)	8.88±0.26* (+93.5%)	9.17±0.22* (+100%)	7.11±0.23* (+54.4%)
NO	0.84±0.03	1.15±0.08* (+36.9%)	1.08±0.07* (+28.6%)	0.96±0.06 (+14.3%)	0.85±0.02 (+1.2%)	0.78±0.01 (-7.1%)

(a) Values are presented as mean ± S. E. of 6 animals/ group. Values between brackets represent percent of change.

(*) Significant difference between control and treated group using Student's unpaired t-test ($P \leq 0.05$).

3.3. Effects of *C. flavidus* Crud Venom on Antioxidant System

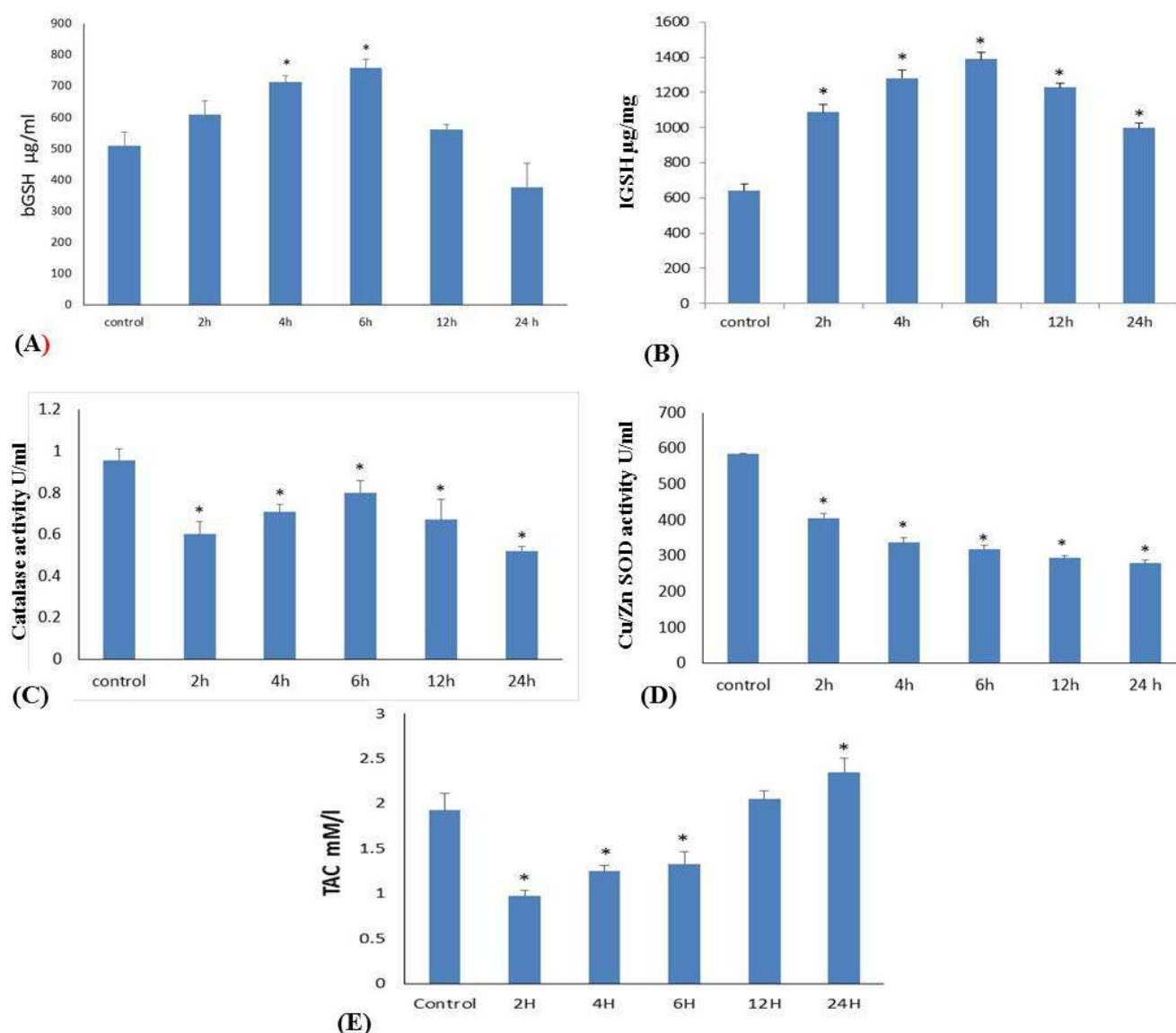


Figure 3. Effect of injected *C. flavidus* venom (8.3 mg/kg) on the level of blood glutathione (A), liver glutathione (B) Catalase activity (C), Cu/Zn-Superoxide dismutase (D) and total antioxidant capacity (E) of albino mice at different time intervals. (*) Significant difference between control and treated group using Student's unpaired t-test ($P \leq 0.05$).

Figure 3 (A- E), and table 2 illustrates the effect of *C. flavidus* crud venom (8.3 mg/kg) on the level of non-enzymatic antioxidants: blood glutathione (bGSH) and liver glutathione (lGSH) and enzymatic antioxidants: catalase (CAT) and Cu/Zn superoxide dismutase (Cu/Zn-SOD), as well as the total antioxidant capacity (TAC) in different-time treated groups.

In figure 3A, the levels of blood glutathione gradually increased, significantly ($P \leq 0.05$) after 4 h. and 6 h. time intervals, compared with control animals. On the other hand, liver glutathione levels increased significantly ($P \leq 0.05$) in all treated groups comparing with control group, figure 3B. According to one-way ANOVA, both blood and liver glutathione levels in treated groups significantly increased

($F_{5,5} = 15.83$ and $F_{5,5} = 49.39$ respectively, $P \leq 0.05$)

compared to control group.

The activities of CAT and Cu/Zn SOD were significantly decreased ($P \leq 0.05$) post venom treatment in all time intervals, especially after 24 h., compared with control values, as in figure 3C and D respectively. One-way ANOVA revealed that differences in the activities of CAT ($F_{5,5} = 61.24$, $P \leq 0.05$) and Cu/Zn SOD ($F_{5,5} = 92.42$, $P \leq 0.05$) between treated and control groups were significant. While in figure 3E, total antioxidant capacity was sharply and significantly decreased ($P \leq 0.05$) in first treated group comparing with treated group, and then increased gradually in next treated groups till exceeded significantly the control value in the last time interval. Using one-way ANOVA, there was a significant difference ($F_{5,5} = 16.18$, $P \leq 0.05$) between treated and control groups.

Table 2. Change in enzymatic and non-enzymatic antioxidant levels after administration of *C. flavidus* venom (8.3 mg/kg).

	Control	Treated groups				
		2 h.	4 h.	6 h.	12 h.	24 h.
bGSH	509.2±42.9 ^a	609.2±43.4 (+19.6%)	712.7±19.7* (+40.1%)	758.5±26.0* (+49.1%)	560.8±16.9 (+10.2%)	375.9±77.1 (-26.1%)
IGSH	640.2±36.9	1088.3±41.3* (+70.0%)	1279.8±49.7* (+100.0%)	1388.5±41.7* (+117.0%)	1227.7±24.8* (+91.9%)	997.7±26.7* (+55.9%)
CAT	1.23±0.065	0.61±0.058* (-50.4%)	0.71±0.034* (-42.3%)	0.81±0.061* (-34.2%)	0.67±0.099* (-45.5%)	0.52±0.023* (-57.7%)
Cu/Zn/SOD	585.9±8.9	405.7±14.4* (-30.4%)	336.9±11.0* (-42.5%)	317.2±7.0* (-45.9%)	294.2±9.9* (-49.8%)	279.4±17.4* (-52.4%)
TAC	1.93±0.19	0.97±0.07 (-49.7%)	1.25±0.07* (-35.2%)	1.33±0.14* (-31.1%)	2.05±0.09 (+6.2%)	2.35±0.16* (+21.8%)

(a) Values are presented as mean ± S. E. of 6 animals/ group. Values between brackets represent percent of change.

(*) Significant difference between control and treated group using student's unpaired t-test ($P \leq 0.05$).

3.4. Histopathological Effects of *C. flavidus* Venom

3.4.1. Liver

Figure 4 (A-G) represents liver sections in control animals and animals treated with *C. flavidus* venom (8.3 mg/kg) dissected after 1, 3 and 7 days, respectively.

Light microscope examination of liver tissue obtained from treated animals with *Conus flavidus* crude venom showed variable histopathological changes after intraperitoneal injection, comparing with normal untreated liver (figure 4B, C). These changes included, after one day of injection (figure 4B, C), loss of cellular outlines, and some

hepatocytes showed vacuolar degeneration, karyolysis and pyknosis with basophilic cytoplasm. After 3 days of injection (figure 4D, E), hepatocytes showed mild degeneration, Lymphocytic aggregation, chromatin fragmentation, pyknosis beside vacuolar cytoplasmic degeneration, mild blood sinusoidal congestion (hemorrhage). Whereas, after 7 days of injection (figure 4F, G), hepatocytes had acute degeneration, nuclear disappeared with highly vacuolar cytoplasm and finally some showed centrilobular necrosis. Furthermore, they showed more increase in lymphocytic infiltration.

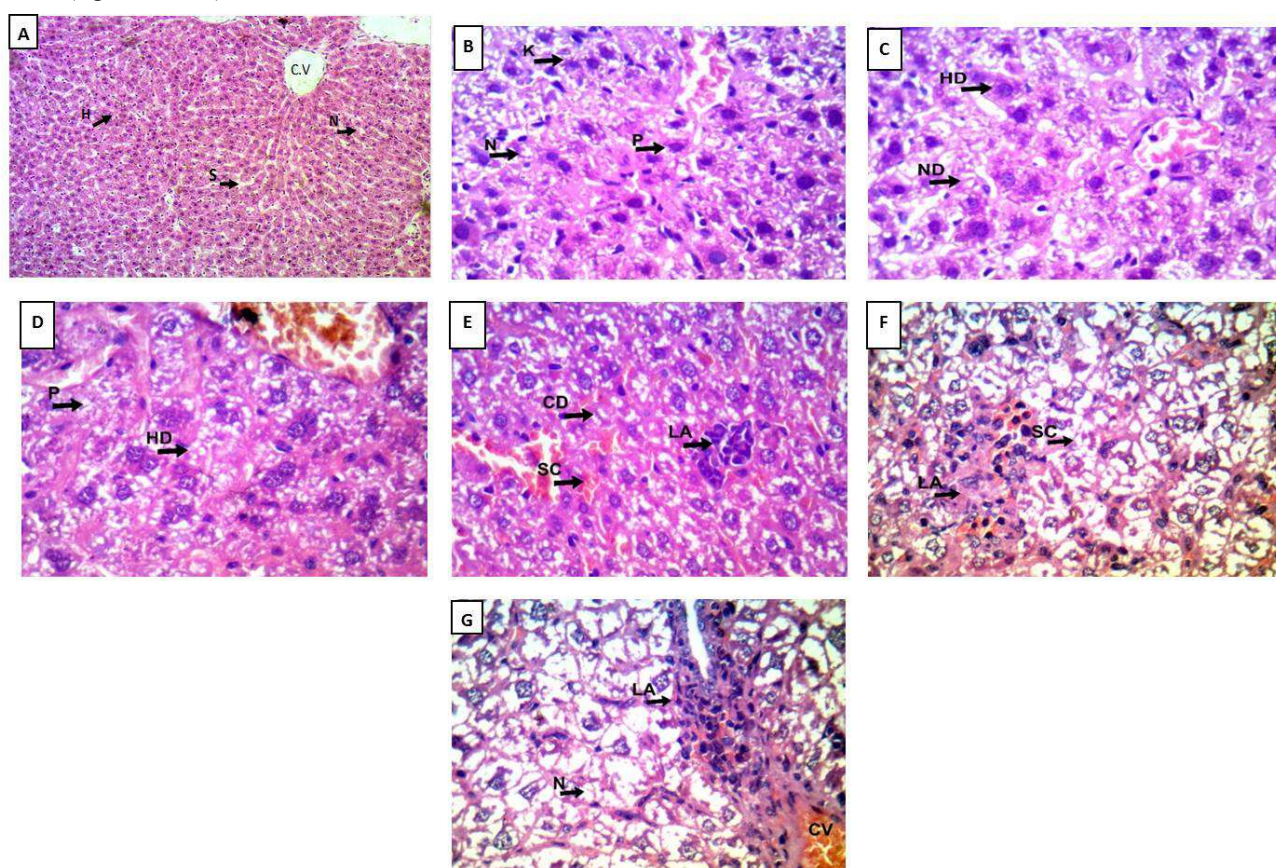


Figure 4. A- A light microscopic photograph of mouse liver section of a control mouse showing normal branching and anastomosing cords of hepatocytes (H) radiating from the central vein (C. V). The hepatocytes have vesicular nuclei (N) and separated by sinusoids (S) (H&E, x 200). B-F: light microscopic photographs of mouse liver sections after injection of $\frac{1}{2}$ LC₅₀ (8.3 µg/g) of *C. flavidus* crude venom. B-C- After 1 day of showing: loss of cellular outlines, hepatocytes vacuolar degeneration (HD), necrosis (N), nuclear disappear (ND), karyolysis (K) and pyknosis (P) (H&E, x 400). D-E- After 3 days showing: increase in hepatocytes degeneration, blood and mild sinusoidal congestion (SC), cytoplasmic vacuolar degeneration (CD), lymphocytic aggregation (LA), hepatocytes vacuolar degeneration (HD) and pyknosis (P) (H&E, x 400). F-G- After 7 days showing: congested central vein (CV) and most of hepatocytes with vacuolated cytoplasm and moderate vascular & sinusoidal congestion (SC), lymphocytic aggregation (LA), acute degeneration and necrosis (N) (H&E, x 400).

3.4.2. Heart

Figure 5 (A- D) demonstrates heart sections in control and treated mice with *C. flavidus* venom (8.3 mg/kg) anatomized after 1, 3 and 7-day time intervals, respectively (figure 5A).

Microscopically, treated heart tissue illustrated pronounced histopathological changes; after one day myocardium revealed myofibrillar separation in a few areas with minimal edema and blood vessel congestion, focal loss of striation, few pyknotic cells and preserved fascicular pattern (figure 5B). After three days of

treatment, sections showed slightly degenerated myofibrils, more loss of striation. In addition, increase of pyknotic cells, acute edema and slight loss of fascicular pattern were observed (figure 5C). While, after seven days of treatment, sections showed moderately degenerated myofibrils and myocytes with moderate edema, some areas with congested blood vessel and hemorrhage. Moreover, loss of striation, normal construction and fascicular pattern could be observed in the myocardium (figure 5D).

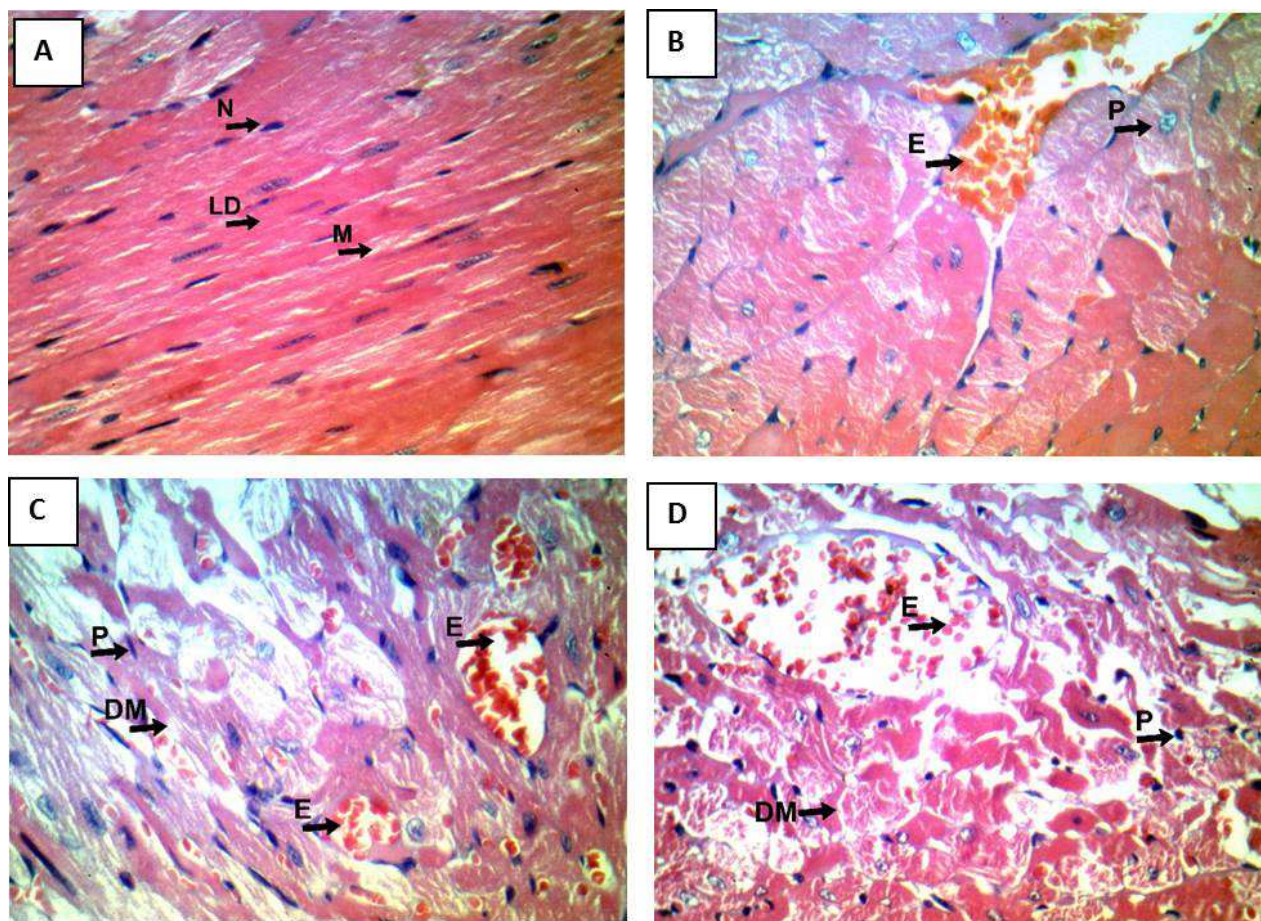


Figure 5. A- A light microscopic photograph of control mouse heart showing individual muscle fibers (M), their striated appearance, and the intercalated discs (LD) at the end of each muscle cell with vesicular nuclei (N). (H&E Stain, X 400). B- E light microscopic photographs of mouse heart after injection of $\frac{1}{2}$ LC₅₀ (8.3 μ g/g) of *C. flavidus* crude venom. B- After 1 day showing: slightly degenerated myofibrils with minimal edema (E) and congestion, focal loss of striation, few pyknotic cells (P) and preserved fascicular pattern. (H&E Stain, X 400) C- After 3 days showing: slightly degenerated myofibrils (DM) with mild edema (E) and congestion, focal loss of striation, few pyknotic cells (P) and slight loss of fascicular pattern. (H&E Stain X 400). D- After 7 days showing: moderately degenerated myofibrils (DM) and myocytes with moderate edema (E) and congestion with extravasated red cells and moderate loss of striation, few pyknotic cells (P) and loss of fascicular pattern (H&E Stain, x 400).

4. Discussion

Several studies have long been focused on the venom of both fish- and mollusc-hunting cone snails due to the biomedical interest of the conopeptides of these species [30-34]. On the other hand, worm-hunting species have been rarely studied, even if recent studies have reported a variety of novel conopeptides, some of them with potent neuropharmacological activity present only in vermivorous cone snails [35-37].

The *Conus* venom has been proposed to specifically target the prey's nervous system and other organs, impairing their functions and damaging the tissues, however the mechanism of tissue damage remains unclear. Cerebral edema, liver damage, hemorrhage and vascular congestion in lungs and kidneys, and inhibition/activation of certain enzymes have been reported [38] after *Conus* envenomation however, there is no evidence linking these effects with the direct cytotoxicity of conotoxins in the organs. So, we hypothesized the *C. flavidus* toxins could induce the generation of high

level of free radicals and (ROS) that are responsible for the cellular membrane damage in organs targeted by venom components. Before investigate the above hypothesis, the toxicity of the venom was evaluated through the hemolytic assay on the erythrocyte suspension, and consequently its LC_{50} was detected, and was found to be approximately 16.68 mg/ml. This hemolytic activity result is supported by the characterization of a cytolytic peptide from the venom of *Conus mustelinus* that was found to have potent hemolytic activity when tested on human erythrocytes [39].

To better understand the induced-cytotoxicity mechanism of *C. flavidus* venom, single dose $\frac{1}{2}$ LC_{50} (8.3 μ g/kg, mice i.p., different time intervals) was evaluated in two levels: Biochemical balance of cellular oxidant / antioxidant compounds, in terms of lipid peroxidase, protein carbonyl, GSH, CAT, SOD, TAC and NO, in addition to histopathological damage of some venom-treated mice tissues, like liver and heart. The biomarkers used to characterize toxic responses must be carefully selected. They are defined as a change in any biological, physical or chemical response associated with toxic effects or exposure to environmental chemicals [40].

The present study revealed that there are significant increases of oxidative stress biomarkers, indicating that the *C. flavidus* venom could cause oxidative damage in the envenomed animals. So, it is reasonable to postulate that the vermivorous species might be equally promising pharmacological treasures [17].

The results of the present study showed that intraperitoneal injection of crude *C. flavidus* venom (8.3 mg/kg) into mice elicited an array of neurotoxic signs including quivering, sedation, reduction in appetite for food and water, dyspnea followed by paralysis in the hind limbs. Similarly, several studies have shown that the venom of *C. geographus*, *C. omaria* and *C. lorioisii* caused various neurotoxic effects in mammals including blurring of vision, impaired speech, shallow breathing, blood pressure fluctuations, depression in motor coordination and muscle paralysis preceding death [41-43], [38]. In mice, that was associated with increased heart rate and strong muscular hind limb paralysis, skeletal muscle paralysis, dyspnea, loss of spontaneous activity followed by respiratory failure. [40]. The mechanism of paralysis following *Conus* envenomation could be attributed to junction blockade of nicotinic acetylcholine receptors, as well as inhibition of motor endplate depolarization by sodium channel blockade [45].

Also, the present study revealed that the contents of lipid peroxide increased significantly (figure 2A), protein carbonyl content increased significantly (figure 2B) and the level of nitric oxide increased significantly (figure 2C) in the treated animals, compared to control values. Pronounced increase in the oxidative stress biomarkers could be an indication for excessive production of reactive oxygen species (ROS) followed by oxidative damage in envenomed animals.

Lipid peroxidation is one of main manifestations of oxidative damage induced by the free radicals produced during various types of xenobiotic or pathological condition.

Peroxidation process of membrane lipids include loss of polyunsaturated fatty acids, decreased lipid fluidity, altered membrane permeability, effects on membrane associated enzymes, altered ion transport, release of material from subcellular compartments, and the generation of cytotoxic metabolites or lipid hydroperoxides [46].

Protein carbonyl is a product of irreversible non-enzymatic oxidation or carbonylation of protein [47]. Carbonyl groups are introduced into proteins by a variety of oxidative pathways [48-49]. The usage of protein carbonyl group as biomarker of oxidative stress has some advantages in comparison with the measurement of other oxidation products because of the relative early formation and the relative stability of carbonylated protein. Additionally, it is considered a widespread marker of severe oxidative stress, damage and disease-derived protein dysfunction [48], [50]. Nitric oxide (NO) superoxide anion, and related reactive oxygen species (ROS) play an important role as regulatory mediators in signaling processes and is the key of endothelium derived releasing factor implicated in the regulation of vascular tone and vasomotor function [51].

There are two possibilities to explain oxidative damage in the treaded groups. (i) Oxidative stress may be related to the hemolytic activity of *Conus* venom. In this situation, hemoglobin is oxidized to the ferric form, met-hemoglobin (met-Hb), and gains a pseudo peroxidase activity capable of catalyzing the production of superoxide ion ($O_2^{\cdot-}$) [52-53]. Although superoxide ion itself is not considered cytotoxic, it spawns toxic derivatives such as hydroxyl radicals and hypohalous acid [54]. A similar situation was found in the venom of *C. textile* [55], *C. californicus* [56] and *C. lorioisii* [38]. These studies concluded that proteolytic enzymes in the venom of *C. textile* and *C. lorioisii* were the prime cause of lysis of red cell membrane by digesting integral protein of the membrane, which in turn led to increased membrane permeability, increased osmotic fragility and hemolysis. (ii) An alternative explanation is that oxidative damage of *Conus* venom could be attributed to its active ingredient phospholipase A2. McIntosh [57] isolated and functionally characterized a novel phospholipase A2 (conodipine-M) from the venom of *C. magus*. Conodipine-M displayed properties that were similar to those of previously characterized PLA2 from snake venom. Phospholipid hydrolysis by PLA2 enzyme releases arachidonic acid whose metabolism results in the formation of potentially toxic ROS and lipid peroxides [58].

El-Asmar and co-workers [59] have reported that the increase in polyunsaturated fatty acids following envenomation may lead to an increase in the rate of lipid peroxidation, which might be responsible for tissue damage. Also, lipid peroxidation may bring about protein damage and inactivation of membrane bound enzyme either through direct attack by free radicals or through chemical modification by its end products [60]. On the other hand, the level of blood GSH (figure 3A) and liver GSH (figure 3B) increased significantly at treated groups as compared to control group. On contrast there is significant decrease at

catalase and Cu/ZN SOD activities at all treated groups (figure 3C and 3D, respectively).

Oxidative stress may occur when the balance that exists between the formation of ROS and their removal by endogenous antioxidant scavenging compounds [61] is disrupted by excessive production of ROS. In the present work, the remarkable elevation in the GSH levels (the most abundant intracellular thiol based antioxidant) in the treated mice was probably necessary for host defense to encounter deleterious effects of ROS such as $O_2^{\cdot-}$, H_2O_2 and NO. Nikitovic and Holmgren [62] indicated that excessive production of NO is counteracted by its conjugation with GSH that results in the S-nitrosoglutathione (GSNO) adduct. GSNO can in its turn be cleaved directly by mammalian thioredoxin reductase (TrxR) or by the complete thioredoxin system, which again liberates GSH and NO under consumption of NADPH. GSNO has also been shown to inhibit TrxR indicating a possible regulatory mechanism.

SOD is one of the body's primary internal anti-oxidant defenses, and plays a critical role in reducing the oxidative stress implicated in atherosclerosis and other life-threatening diseases. Studies have shown that SOD can play a critical role in reducing internal inflammation and lessening pain associated. The main role of SOD is based on its ability to protect cells against oxidative damage caused by superoxide anion radicals. SOD rapidly dismutate superoxide anion to a less reactive molecule (H_2O_2), which is further degraded by CAT to water and oxygen [63]. So, the low activity of SOD in our study may be related to the elimination of superoxide anion radicals in treated animals. The present results are coincident with Abdel-Rahman *et al.* (2010) [64] who reported that the decrease in the SOD activity and increase in PCC could explain the induction of free radicals after scorpion envenomation.

Histopathological alterations have been used as markers to better understand animal health exposed to contaminants in lab [65-66] and field studies [67 -68]. The main advantage of using histopathological markers in monitoring is that this category of markers allows studying the target organs [69]. The changes found in these organs are normally as general to pinpoint than functional ones [70], exhibit as alarming signals of alterations to general animal health [71].

The present data displayed marked histopathological changes as a result of direct effect of *C. flavidus* venom injection. These changes involved hepatocytes degeneration, lymphocytic aggregation, chromatin fragmentation, vacuolar cytoplasmic degeneration, mild blood sinusoidal congestion, karyolysis, pyknosis, nuclear disappeared with highly vacuolar cytoplasm and finally some showed centrilobular necrosis. Regarding to other cone snails, liver injuries characterized other *Conus* species injection, Like vascular congestion and inflammatory cell infiltration around the portal triad of the liver of mice caused by *Conus lorioisii* crude venom with different doses ranged from 0.5 to 6.0 mg/kg via i.p.), [38].

Whereas, the crude venom (dose 5 mg /kg i.p.) of *Conus inscriptus*, *C. lentiginosus* and *C. zeylanicus* revealed

hepatocytes disrupted, central veins were occluded by hemolysed blood and perivascular area showed granulomatous lesions and vacuolated areas with honey-comb like appearance in mice [72]. Moreover, it had hyperplasia of cortical cells with constriction of sinusoidal space and marked ycknosis of the hepatocytes nuclei in case of *C. inscriptus* and *C. lentiginosus* crud venom [72]. The effect of crud venom of *C. zeylanicus* using 60 mg/kg via i.p. in mice revealed liver tissues were disrupted with hemorrhagic necrosis [44]. These results were associated with metabolic changes especially changes in liver biomarkers obtained in this study.

Meanwhile the presence of necrotic cell may be due to hypoxia by decrease the blood supply to an area of tissue and in turn hypoxia as well as enhancement of cell death by *C. flavidus* venom leading to generation of free radicals in plasma and organs during severe envenomation [73].

The second main organ at this study was the heart which histopathological changed showed moderately degenerated myofibrils and myocytes, edema blood vessel congestion, loss of striation, few pyknotic cells and loss of fascicular pattern. Crude venom of *Conus inscriptus*, *C. lentiginosus* and *C. zeylanicus* had histopathological changes; myocardium revealed myofibrillar separation with myocardial hemorrhage could myocardial vessels revealed thrombosis, leukocytes aggregation [72]. The ischemic myocardial lesion may not be caused only by catecholamines but by the cytokines and/or the neuropeptide Y released on coronary vessels. [74].

The histopathological effects of other cone snail's venom on vital tissues revealed spongiosis of the brain, hemorrhages/congested blood vessels in lung and endothelial cells of the renal tubule [75] and vascular congestion and inflammatory cell infiltration around the portal triad of the liver [38] after treatment with *Conus lorioisii* venom.

The present study concluded that, the venom of *C. flavidus* crude venom has distinct effect on all biochemical parameters. In addition to different histopathological changes on liver tissue including cytoplasmic degeneration, lymphatic aggregation, hepatocytes degeneration and sinusoidal congestion, the heart tissue also showed degeneration myofibrils, edema, congested blood vessels and hemorrhage. These results proved that there is an evidence of presence of some bioactive components in the crude venom of *C. flavidus* that could in prospective works be isolated and characterized to be used in the level of mammalian cells as possible templates for novel pharmacological therapeutics.

References

- [1] B. Livett, k. Gayler, & Z. Khalil. (2004). Drugs from the sea: conopeptides as potential therapeutics. Current medicinal chemistry, 11 (13), 1715-1723.
- [2] S. Conticello, Y. Gilad, N. Avidan, E. Ben-Asher, Z. Levy and M. Fainzilber (2001). "Mechanisms for evolving hypervariability: the case of conopeptides." Molecular Biology and Evolution 18 (2): 120-131.

- [3] D. Alonso, Z. Khalil, N. Satkunanathan and B. Livett (2003). "Drugs from the sea: conotoxins as drug leads for neuropathic pain and other neurological conditions." *Mini reviews in medicinal chemistry*, 3 (7): 785-787.
- [4] O. Buczek, G. Bulaj and B. Olivera (2005). "Conotoxins and the posttranslational modification of secreted gene products." *Cellular and Molecular Life Sciences CMLS* 62 (24): 3067-3079.
- [5] J. Jakubowski, W. Kelley, J. Sweedler, W. Gilly and J. Schulz (2005). "Intraspecific variation of venom injected by fish-hunting *Conus* snails." *Journal of Experimental Biology* 208 (Pt 15): 2873-2883.
- [6] C. Pi, Y. Liu, C. Peng, X. Jiang, J. Liu, B. Xu, X. Yu, Y. Yu, X. Jiang, L. Wang, M. Dong, S. Chen and A. L. Xu (2006). "Analysis of expressed sequence tags from the venom ducts of *Conus striatus*: focusing on the expression profile of conotoxins." *Biochimie* 88 (2): 131-140.
- [7] S. Luo, D. Zhangsun, Y. Wu, X. Zhu, L. Xie, Y. Hu, J. Zhang and X. Zhao (2006). "Identification and molecular diversity of T-superfamily conotoxins from *Conus lividus* and *Conus litteratus*." *Chemical biology & drug design* 68 (2): 97-106.
- [8] S. Norton, and B. Olivera (2006). "Conotoxins down under." *Toxicon* 48 (7): 780-798.
- [9] Peng, C., G. Yao, B.-M. Gao, C.-X. Fan, C. Bian, J. Wang, Y. Cao, B. Wen, Y. Zhu, Z. Ruan, X. Zhao, X. You, J. Bai, J. Li, Z. Lin, S. Zou, X. Zhang, Y. Qiu, J. Chen, S. L. Coon, J. Yang, J.-S. Chen and Q. Shi (2016). "High-throughput identification of novel conotoxins from the Chinese tubular cone snail (*Conus betulinus*) by multi-transcriptome sequencing." *GigaScience* 5: 17.
- [10] J. Bingham, P. Jones, A. Lewis, R. Andrews, P. Alewood, In *Biochemical Aspects of Marine Pharmacology*, Lazarovici, P., Spira, M. E., Zlotkin, E. (Eds.), 1996, 13-27.
- [11] E. Heading. (2002). *Conus* peptides and neuroprotection. *Current opinion in investigational drugs (London, England: 2000)*, 3 (6), 915-920.
- [12] S. McDonough, I. Boland, L. Mintz, I. Bean, 2002. Interactions among toxins that inhibit N-type and P-type calcium channels. *J. Gen. The Journal of general physiology*. 119, 313-328.
- [13] S. Staats, T. Yearwood, G. Charapata, W. Presley, S. Wallace, M. Byas-Smith, R. Fisher, A. Bryce, A. Mangieri, R. Luther, M. Mayo, D. McGuire, D. Ellis, 2004. Intrathecal ziconotide in the treatment of refractory pain in patients with cancer or AIDS: a randomized controlled trial. *JAMA* 291, 63-70.
- [14] H. Terlau, and B. Olivera (2004). "Conus venoms: a rich source of novel ion channel-targeted peptides." *Physiological reviews* 84 (1): 41-68.
- [15] C. Moller, S. Rahmankhah, J. Lauer-Fields, J. Bubis, G. Fields and F. Mari (2005). "A novel conotoxin framework with a helix-loop-helix (Cs alpha/alpha) fold." *Biochemistry* 44 (49): 15986-15996.
- [16] B. Aguilar, E. Lopez-Vera, A. Heimer de la Cotera, A. Falcon, M. Olivera and M. Maillo (2007). "I-conotoxins in vermivorous species of the West Atlantic: peptide sr11a from *Conus spurius*." *Peptides* 28 (1): 18-23.
- [17] C. Romeo, L. Di Francesco, M. Oliverio, P. Palazzo, G. Massilia, P. Ascenzi, F. Polticelli and M. E. Schinina (2008). "Conus ventricosus venom peptides profiling by HPLC-MS: a new insight in the intraspecific variation." *Journal of separation science*, 31 (3): 488-498.
- [18] L. Cruz, A. Ramilo, P. Corpuz, B. Olivera, 1992. *Conus* peptides: phylogenetic range of biological activity. *The Biological Bulletin*. 183, 159-164.
- [19] M. Almaaytah, L. Zhou, T. Wang, B. Chen, B. Walker and C. Shaw (2012). "Antimicrobial/cytolytic peptides from the venom of the North African scorpion, *Androctonus amoreuxi*: Biochemical and functional characterization of natural peptides and a single site-substituted analog." *Peptides* 35 (2): 291-299.
- [20] K. Yagi, (1987). Lipid peroxides and human disease. *Chemistry and physics of lipids* 45, 337-351.
- [21] Z. Reznick, L. Packer, (1994). Oxidative damage to proteins: spectrophotometric method for carbonyl assay. *Methods in enzymology*. 233, 357-363.
- [22] C. Green, A. Wagner, J. Glogowski, L. Skipper, J. Wishnok, R. Tannenbaum, 1982. Analysis of nitrate, nitrite and [15N] nitrate in biological fluids. *Analytical biochemistry*. 126, 131-138.
- [23] E. Biutler, O. Doron, B. Kelly, (1963). Improved method for determination of blood glutathione. *Journal of laboratory and clinical medicine* 61: 882-888.
- [24] P. Misra, I. Fridovich,, (1972). The role of superoxide anion in the autoxidation of epinephrine and a simple assay for superoxide dismutase. *Journal of Biological chemistry*, 247 (10): 3170-3175.
- [25] H. Aebi, Catalase in vitro. In *Oxygen radicals in biological systems: Meths Enzymol.* Edited by Packer L. Orlando: Academic; 1984: 121-126.
- [26] G. Cohen, D. Dembiec, J. Marcus J (1970). Measurement of catalase activity in tissue extracts. *Analytical biochemistry*, 34: 30-38.
- [27] D. Koracevic, G. Koracevic, V. Djordjevic, V., Andrejevic, S., Cosic, V., (2001). Method for the measurement of antioxidant activity in human fluids. *Journal of clinical pathology*. 54, 356-361.
- [28] P. Dancy, J. Reidy, (2002). *Statistics without maths for psychology* (Eds.), Harlow: Pearson Education.
- [29] W. Snedecor, (1956). *Statistical Methods*, 4th Eds. The Iowa Collage Press, Iowa State, USA.
- [30] S. Dutertre, H. Jin, I. Vetter, B. Hamilton, K. Sunagar, V. Lavergne, & F. Alewood. (2014). Evolution of separate predation-and defence-evoked venoms in carnivorous cone snails. *Nature communications*, 5.
- [31] M. Olivera, (2002). "Conus" Venom Peptides: Reflections from the Biology of Clades and Species. *Annual Review of Ecology and Systematics*, 25-47.
- [32] M. Olivera, (1997). EE Just lecture, 1996 *Conus* venom peptides, receptor and ion channel targets, and drug design: 50 million years of neuropharmacology. *Molecular biology of the cell*, 8 (11), 2101-2109..
- [33] M. Olivera, & W. Teichert, (2007). Diversity of the neurotoxic *Conus* peptides. *Molecular Interventions*, 7 (5), 251.

- [34] M. McIntosh, & M. Jones, (2001). Cone venom—from accidental stings to deliberate injection. *Toxicon*, 39 (10), 1447-1451.
- [35] B. Aguilar, E. Lopez-Vera, E. Ortiz, B. Becerril, D. Possani, M. Olivera, and P. Heimer de la Cotera,. (2005). A novel conotoxin from *Conus delessertii* with post-translationally modified lysine residues. *Biochemistry*, 44: 11130–11136.
- [36] M. Loughnan,, A. Nicke, A. Jones, I. Schroeder, T. Nevin, J. Adams, F. Alewood, and J. Lewis, R. J. (2006). Identification of a Novel Class of Nicotinic Receptor Antagonists. *The Journal of Biological Chemistry*, 281 (34): 24745–24755.
- [37] A. Zugasti-Cruz, M. Maillot, E. Lopez-Vera, A. Falcon, Heimer de la Cotera, E. P., Olivera, B. M. and Aguilar, M. B. (2006). Amino acid sequence and biological activity of a gamma-conotoxin-like peptide from the worm-hunting snail *Conus austini*. *Peptides*, 27: 506–51.
- [38] R. Saminathan, S. Babuji, S. Sethupathy, P. Viswanathan, T. Balasubramanian and P. Gopalakrishnakone (2006). "Clinico-toxinological characterization of the acute effects of the venom of the marine snail, *Conus loroisii*." *Acta Trop* 97 (1): 75-87.
- [39] S. Biggs, Y. Rosenfeld, Y. Shai, and M. Olivera, (2007). Conolysin-Mt: a *Conus* peptide that disrupts cellular membranes. *Biochemistry*, 46 (44), 12586-12593.
- [40] C. Oviedo-Gómez, M. Galar-Martínez, S. García-Medina, C. Razo-Estrada, and M. Gómez-Oliván, (2010). Diclofenac-enriched artificial sediment induces oxidative stress in *Hyalella azteca*. *Environmental Toxicology and Pharmacology*, 29 (1), 39-43.
- [41] R. Endean, G. Parrish, and P. Gyr, (1974). Pharmacology of the venom of *Conus geographus*. *Toxicon*, 12: 131–138.
- [42] J. Cruz, and J. White, (1995). Clinical toxicology of *Conus* snail stings. In: *Handbook of Clinical Toxicology of Animal Venoms and Poisons*, 117-127.
- [43] D. Fegan, and D. Andresen (1997). "*Conus geographus* envenomation." *Lancet* 349(9066): 1672.
- [44] D. Annadurai, R. Kasinathan, and S. Lyla, (2007). Acute toxicity effect of the venom of the marine snail, *Conus zeylanicus*. *Journal of environmental biology*, 28 (4), 825-828.
- [45] M. Olivera, R. Hillyard, J. Rivier, S. Woodward, R. Gray, G. Corpuz, and J. Cruz, (1990). Conotoxins: targeted peptide ligands from snail venoms. In: Hall, S., Strichartz, G. (Eds.), *Marine Toxins*. American Chemical Society Washington, DC, pp. 256–278.
- [46] A. Santamaria, S. Rodriguez, A. Zugasti, A. Martinez, S. Galvan-Arzate, and S. Puertas, (2002). A venom extract from the sea anemone *Bartholomea annulata* produces haemolysis and lipid peroxidation in mouse erythrocytes. *Toxicology*, 173: 221–228.
- [47] I. Dalle-Donne, R. Rossi, R. Colombo, D. Giustarini, & A. Milzani, (2006). Biomarkers of oxidative damage in human disease. *Clinical Chemistry*, 52 (4), 601-623.
- [48] I. Dalle-Donne, R. Rossi, D. Giustarini, A. Milzani, and R. Colombo. (2003). Protein carbonyl groups as biomarkers of oxidative stress. *Clinica chimica acta*, 329 (1), 23-38.
- [49] I. Fedorova, A. Mikov, E. Maleeva, A. Andreev, E. Bocharov, D. Tikhonov, and A. Kozlov, S. A. (2014). Novel insect-toxin from *Tibellus oblongus* spider venom. In *FEBS Journal* (281), 414-415.
- [50] T. Mayne. (2003). Antioxidant nutrients and chronic disease: use of biomarkers of exposure and oxidative stress status in epidemiologic research. *The Journal of nutrition*, 133 (3), 933S-940S.
- [51] L. Petricevich. (2004). Cytokine and nitric oxide production following severe envenomation. *Current Drug Targets-Inflammation and Allergy*, 3 (3), 325-332.
- [52] I. Alayash. (1999). Hemoglobin-based blood substitutes: oxygen carriers, pressor agents, or oxidants? *Nature Biotechnology*, 17: 545–549.
- [53] T. Kawano, R. Pinontoan, H. Hosoya, & S. MUTO. (2002). Monoamine-dependent production of reactive oxygen species catalyzed by pseudoperoxidase activity of human hemoglobin. *Bioscience, biotechnology, and biochemistry*, 66 (6), 1224-1232.
- [54] N. Jiang, S. Tan, B. Ho, and L. Ding. (2007). Respiratory protein-generated reactive oxygen species as an antimicrobial strategy. *Nature Immunology*, 8 (10): 1114-1122.
- [55] G. Reyes, & J. Cruz. (1983). Haemolytic factors from *Conus textile* venom. *Acta Med. Phillips*, 17-25.
- [56] S. Kreger. (1989). Cytolytic activity in the venom of the marine snail *Conus californicus*. *Toxicon*, 27 (1): 56.
- [57] M. McIntosh, F. Ghomashchi, H. Gelb, J. Dooley, J. Stoehr, B. Giordani, R. Naisbitt, and M. Olivera, (1995). Conodipine-M, a novel phospholipase A2 isolated from the venom of marine cone snail *Conus magus*. *The Journal of Biological Chemistry*, 270 (8): 3518-3526.
- [58] M. Adibhatla, F. Hatcher, and J. Dempsey. (2003). Phospholipase A2, hydroxyl radicals, and lipid peroxidation in transient cerebral ischemia. *Antioxidant and Redox Signaling* 5: 647–654.
- [59] F. El-Asmar, M. Farag, S. Shoukry, and R. El-Shimi. (1979). Effect of scorpion *Leiurus quinquestriatus* venom on lipid peroxidation. *Toxicon*, 17: 279.
- [60] B. Halliwell, and M. Gutteridge. (1989). *Free Radicals in Biology and Medicine*, second ed. Oxford Univeristy Press, New York.
- [61] M. Gutteridge, J. M. and Mitchell, J. (1999). Redox imbalance in the critically ill. *British Medical Bulletin*, 55 (1), 49-75.
- [62] D. Nikitovic, and A. Holmgren. (1996). S-nitrosoglutathione is cleaved by the thioredoxin system with liberation of glutathione and redox regulating nitric oxide. *Journal of Biological Chemistry*, 271 (32), 19180-19185.
- [63] J. Wetscher, M. Bagchi, D. Bagchi, G. Perdakis, R. Hinder, K. Glaser, and A. Hinder. (1995). Free radical production in nicotine treated pancreatic tissue. *Free Radical Biology and Medicine*, 18 (5), 877-882.
- [64] A. Abdel-Rahman, M. Abdel-Nabi, A. Nassier, and J. Schemerhorn. (2010). Neurotoxic and cytotoxic effects of venom from different populations of the Egyptian *Scorpio maurus palmatus*. *Toxicon*, 55, 298-306.
- [65] W. Wester, and H. Canton. (1991). the usefulness of histopathology in aquatic toxicity studies. *Comparative Biochemistry and Physiology Part C: Comparative Pharmacology*, 100 (1), 115-117.

- [66] S. Thophon, M. Kruatrachue, S. Upatham, P. Pokethitiyook, S. Sahaphong, & S. Jaritkhuan, (2003). Histopathological alterations of white seabass, *Lates calcarifer*, in acute and subchronic cadmium exposure. *Environmental Pollution*, 121 (3), 307-320.
- [67] J. Schwaiger, R. Wanke, S. Adam, M. Pawert, W. Honnen, & R. Triebkorn. (1997). The use of histopathological indicators to evaluate contaminant-related stress in fish. *Journal of Aquatic Ecosystem Stress and Recovery*, 6 (1), 75-86.
- [68] J. Teh, S. Adams, and E. Hinton. (1997). Histopathological biomarkers in feral freshwater fish populations exposed to different types of contaminant stress. *Aquatic Toxicology*, 37 (1), 51-70.
- [69] M. Gernhofer, M. Pawet, E. Schramm, Müller & R. Triebkorn. 2001. Ultrastructural biomarkers as tools to characterize the health status of fish in contaminated streams. *Journal of Aquatic Ecosystem, Stress and Recovery*, 8: 241-260.
- [70] E. Fanta, A. Rios, S. Romão, C. Vianna, & S. Freiburger. (2003). Histopathology of the fish *Corydoras paleatus* contaminated with sublethal levels of organophosphorus in water and food. *Ecotoxicology and environmental safety*, 54 (2), 119-130.
- [71] E. Hinton, J. Lauren, L. Holliday, and S. Giam, (1988). Liver structural alterations accompanying chronic toxicity in fishes: potential biomarkers of exposure. In *Preprints of Papers Presented at National Meeting, Division of Water, Air and Waste Chemistry, American Chemical Society;(USA)* (Vol. 28).
- [72] P. Kumar, K. Venkateshvaran, P. Srivastava, K. Nayak, M. Shivaprakash, and K. Chakraborty. (2013). Toxicity and histopathological observations on albino mice on intra-peritoneal injection of three species of *Conus*. *International Journal of Advanced Research in Pharmaceutical and Bio Sciences*, 3 (1).
- [73] D. Uchitel. (1997). Toxins affecting calcium channels in neurons. *Toxicon*, - 11911161.8(35).
- [74] M. Bahloul, H. Kallel, N. Rekik, C. Ben Haminda, H. Chelly, and M. Bouaziz. (2005). Cardiovascular dysfunction following severe scorpion envenomation. *Mechanisms and physiopathology. Presse Medicale*, 34, 115-120.
- [75] M. Fainzilber, and E. Zlotkin. (1992). A new bioassay reveals mollusc-specific toxicity in molluscivorous *Conus* Venoms. *Toxicon*, 30 (4): 465-469.