

Case Report

Recurrent Parathyroid Adenoma at the Same Site Importance of ROLL

Ayesha Ammar^{*}, Kahkashan Bashir, Muhammad Faheem, Sadaf Batool, Noreen Marwat, Naseer Ahmed, Shazia Fatima

Pakistan Atomic Energy Cancer Hospital, Nori, Islamabad

Email address:

ayashaammar25308@gmail.com (A. Ammar)

^{*}Corresponding author

To cite this article:

Ayesha Ammar, Kahkashan Bashir, Muhammad Faheem, Sadaf Batool, Noreen Marwat, Naseer Ahmed, Shazia Fatima. Recurrent Parathyroid Adenoma at the Same Site Importance of ROLL. *International Journal of Diabetes and Endocrinology*. Vol. 6, No. 1, 2021, pp. 9-15.

doi: 10.11648/j.ijde.20210601.13

Received: December 1, 2020; **Accepted:** December 15, 2020; **Published:** January 15, 2021

Abstract: Background: Recurrent hyperparathyroidism is defined by the re-appearance of parathyroid hormone (PTH) and high blood calcium levels more than 6 months after successful initial surgery for primary hyperparathyroidism. Many causes are associated with recurrent hyperparathyroidism and one of the main reasons is the presence of parathyroid adenoma. Radio-guided occult lesion localization (ROLL) has emergent role in per-operative localization of pathological lesions. ROLL has established role in breast cancer, axillary and thyroid surgery. ROLL is a valuable addition in parathyroid exploration especially in small sized parathyroid adenomas. ROLL is safe and efficient techniques helping in more accurate lesion centricity. Case presentation A 35 years old female was referred to our Nuclear Medicine department due to recurrently raised Calcium and PTH levels. She had complaints of generalized aches and pains with no visible neck nodule. Her Ultrasound neck showed no abnormal lesion while 99m Tc MIBIScan showed an area of increased radiotracer uptake in the right side of neck. Focused surgical neck exploration was done and a parathyroid adenoma was removed. Conclusions Parathyroid adenoma is a most common cause of primary hyperparathyroidism and usually presents symptomatically with high calcium and parathyroid hormone levels. Parathyroid adenoma is diagnosed by imaging and laboratory studies. One stop management is the surgical removal of 3 and a half removal of parathyroid gland and only sparing half of the gland.

Keywords: Recurrence, Parathyroid Adenoma, Raised PTH, Serum Calcium, ROLL

1. Introduction

Normally people have 4 parathyroid glands in the neck and they are positioned posterior to the thyroid gland. Adenomatous formation can occur in any of them. However supernumerary parathyroid glands are also common and are seen in the common practice multiple times.[1, 2] Inferior parathyroid glands about 62% were more often ectopic, the reason behind this may be the relatively longer path of migration of the inferior glands during embryologic development. High variability exists among the common locations of ectopic parathyroid glands but the common locations noted in literature are thymus, superior mediastinum, intrathyroidal, tracheoesophageal groove, and

retroesophageal regions. In more than 80% of the cases parathyroid adenoma is the cause of primary hyperparathyroidism. Rest of the causes are multigland hyperplasia, multiple parathyroid adenomas or, rarely a, parathyroid carcinoma<1.3. [3]

IMAGINGTECHNIQUES: Pt was subjected to the dual phase scintigraphy with 99mTcMIBI as radiotracer. Radiotracer was injected i/v and static images were taken at 15mins, 1, 2 and 2and half hours. Early phases reveal radiotracer uptake both in the thyroid as well as parathyroid gland while the delayed images reveal intense uptake in the right lower lateral side of neck. These Sestamibi findings were highly suggestive of parathyroid adenoma. Correlative SPECT- CT showed uptake in the inferior parathyroid gland.

2. Case Report

A 35 year old female was referred to our Nuclear Medicine department due to hypercalcaemia and raised PTH levels. Hypercalcaemia was first detected in September 2014. She presented with complaints of generalized weakness, depression and spontaneous fractures, with no h/o fall or trauma. Physical examination revealed only a nodule in the right side of neck. She was housewife. She did not have any past history of renal stones.

Laboratory data revealed sustained hypercalcaemia that is 11.6mmol/L, elevated PTH that is 1284 (12-65) intact-PTH. Her renal functions were within normal limits, serum creatinine was 70 μ mol/L, and 24-hour urine calcium was 5mmol/L per 24hours. Her complete blood count (CBC) and liver function tests were normal.

Her correlative dexta scan also showed osteoporosis. Her correlative bone scan showed picture of metabolic bone disease with Tie sternum, beaded appearance of the costochondral junctions, increased target to background ratio and faint visualization of kidneys. She had fracture of femur and nailing and plating was performed. Rest of the tests was normal. Ultrasound neck doesnot reveal any parathyroid gland in 2014. ^{99m}Tc-sestamibi dual-phase imaging showed an area of increased radiotracer uptake in the right lower lobe of parathyroid region. Pt was then referred to the surgical department and parathyroid surgery was performed and after that pt became pain free and there were no signs of weakness and also PTH level fall down. H/P report revealed parathyroid adenoma.

Pt was referred again in February 2020 with same complaints of weakness, nausea, vomiting, bone pains. Her serum PTH and serum calcium levels were started to rise. Now she had PTH 1398pg/ml and calcium this time was 12mmol/L. She was sent for the ^{99m}Tc MIBI scintigraphy to our department. Again the scintigraphy revealed parathyroid adenoma in the lower right pole. At this time we had in our department the facility of SPECT CT and it also showed same results. Again was sent to the surgical department and the H/P revealed parathyroid adenoma. She became pain free and no signs of weakness were noted. Pt remained well for 2 months.

Pt was referred for the third time in June 2020 with same complaints. SPECT CT showed uptake in the right side in the mediastinum lying deep to the clavicle that was slightly lower than the one noted in the right inferior parathyroid region. Now here comes the importance of ROLL. This time we took the help of our gamma probe to guide the surgeon. Initially we took the background counts that were 343 and we mark the lesion with the probe and the counts were more than 1600. Supraclavicular incision was made and guiding with the gamma probe parathyroid was removed and H/P again showed parathyroid adenoma. Parathyroid scan was again performed after a month of surgery in august and it revealed no evidence of adenoma or hyperplasia in neck or mediastinum.

3. Discussion

MIBI has long been in use for localizing the pathological parathyroid gland and also for the preoperative localization. In the combination technique, probability of correct localization of the lesion is quite high (sensitivity was reported as 96%, specificity as 83%, positive predictive value as 88% and negative predictive value as 94%). [4] The most popular method of assisted surgical techniques is the use of gamma surgical probe.

The same localization of both tumors, as demonstrated by the finding of suture, could be ascribed to spillage of parathyroid tissue during surgery even if the tumour had been an adenoma. [5] However, local malignant recurrence in parathyroid carcinoma is more frequent than metastases. [6] The criteria for selection of patients for this radioguided procedure as per IAEA guidelines can be summarized as follows [7]:

1. Patients with primary hyperparathyroidism and rarely tertiary hyperparathyroidism
2. Scintigraphic visualization of a single site of tracer uptake
3. Good uptake of ^{99m}Tc-sestamibi by the hyper functioning parathyroid gland
4. Absence of concomitant solid thyroid nodules
5. Exclusion of the multiple endocrine neoplasm (MEN) syndromes

In our daily clinical practice it is noticed that the size of parathyroid adenoma is always less 2 cm while it is less than 1g in weight. If the size of parathyroid adenoma exceeds 2 cm than the question arises to differentiate between parathyroid adenoma and parathyroid carcinoma. [8]. Parathyroid cysts or cystic adenomas often show large sized parathyroid glands. [9]. Application of ROLL techniques helps in the optimal determination of the incision level by localizing the lesion on the skin before the incision. A meta-analysis concerning 24 studies published between January 2003 and March 2014 including 1,276 patients showed a per-patient pooled sensitivity of 86 % for SPECT/CT which was superior to the 74 % value observed with stand-alone SPECT and 70 % with planar scintigraphy. In this analys is the rate of ectopic parathyroid adenomas ranged between 4 % and 20 % with a clear added value of SPECT/CT for the localization of the ectopic sites [10]. Recent addition is the use of 18F-fluorocholine PET/CT has been found to perform better (92% sensitivity, 100% specificity) than ^{99m}Tc-Sestamibi SPECT/CT (49% sensitivity, 100 % specificity) in localizing hyper functioning parathyroid tissue in 24 patients with primary hyperparathyroidism a study performed by Wong et al [10]. The gold standard for the conformation is the histopathological examination once it is removed. But a study by Amza *et al.* stated that the most accurate results can be obtained by a combination of post operative PTH levels with the histopathological examination. [11]. This superiority of imaging with 18F-fluorocholine, is mainly based on the detection of multiple lesions and hyperplasia as an indication of choice to localize parathyroid abnormal tissue in patients with negative ^{99m}Tc-sestamibi imaging. This approach may

lead to successfully image- guided surgery [12, 13]. In a study performed by Estremes et al he utilizes the portable gamma camera for the retrieval of the ^{99m}Tc -sestamibi-avid parathyroid adenomas.[14]. Recurrent hyperparathyroidism is defined by the re-appearance of high blood calcium levels more than 6 months after successful initial surgery for primary hyperparathyroidism. Further probing in to this matter following 5 main causes are identified. [15, 16]

1. One of the reasons is the presence of another adenoma that lies dormant. The dominant one releases more PTH and thus the other one remains inactive. When the active one was removed surgically thus it activates the sleeping one. Thus it takes over and starts producing the PTH. It also has to be removed surgically.
2. The other condition is when all of the 4 glands are abnormal. The best solution for this is the removal of three and a half glands leaving behind the half of the gland, can be termed as missed parathyroid hyperplasia.
3. Third reason could be partial removal of the parathyroid gland and this could also be solved with the redo surgery.

4. Parathyromatosis is a condition when the initial surgeon accidentally breaks the capsule of parathyroid adenoma. Thus it helps to release the abnormal parathyroid cells and it spills and it seeds the nearby soft tissues of the neck. Parathyroidectomy is the option here. But in some cases the small cells left behind and can eventually grow back.
5. Last but not the least is the parathyroid carcinoma. It is extremely rare condition and it affects 1 in 1000 patients which can be often life threatening. Sometimes it is hard to tell the difference between parathyroid carcinoma and parathyromatosis-and here the Histopathologist can solve the puzzle.

4. Conclusion

In my opinion Roll will play an important role in establishing the role in minimum invasive surgery and thus decreasing the post op mortality and morbidity of the patient. Secondly it will decrease the surgeon based failure and will increase his confidence.

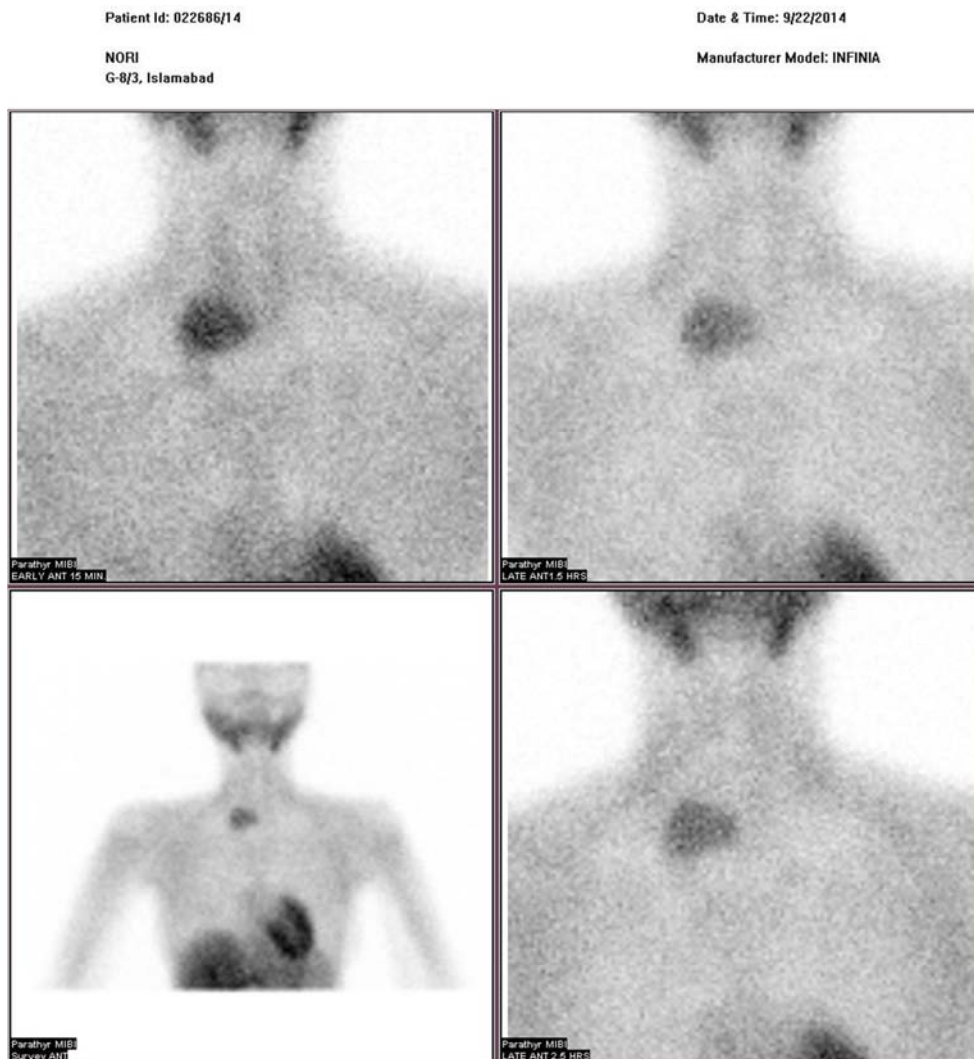


Figure 1. Showing the tracer retention in the parathyroid adenoma in right parathyroid gland in 2014.

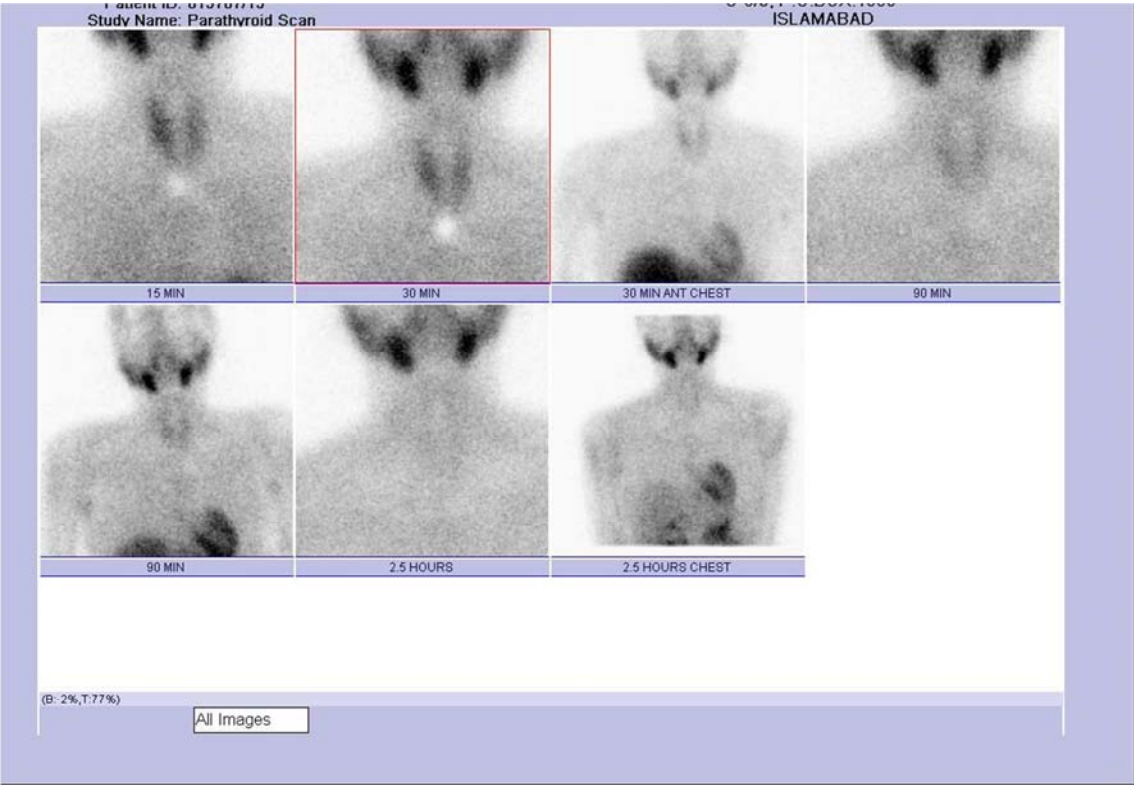


Figure 2. Showing no radiotracer uptake in the region of neck/mediastinum on planar imaging in 2015.

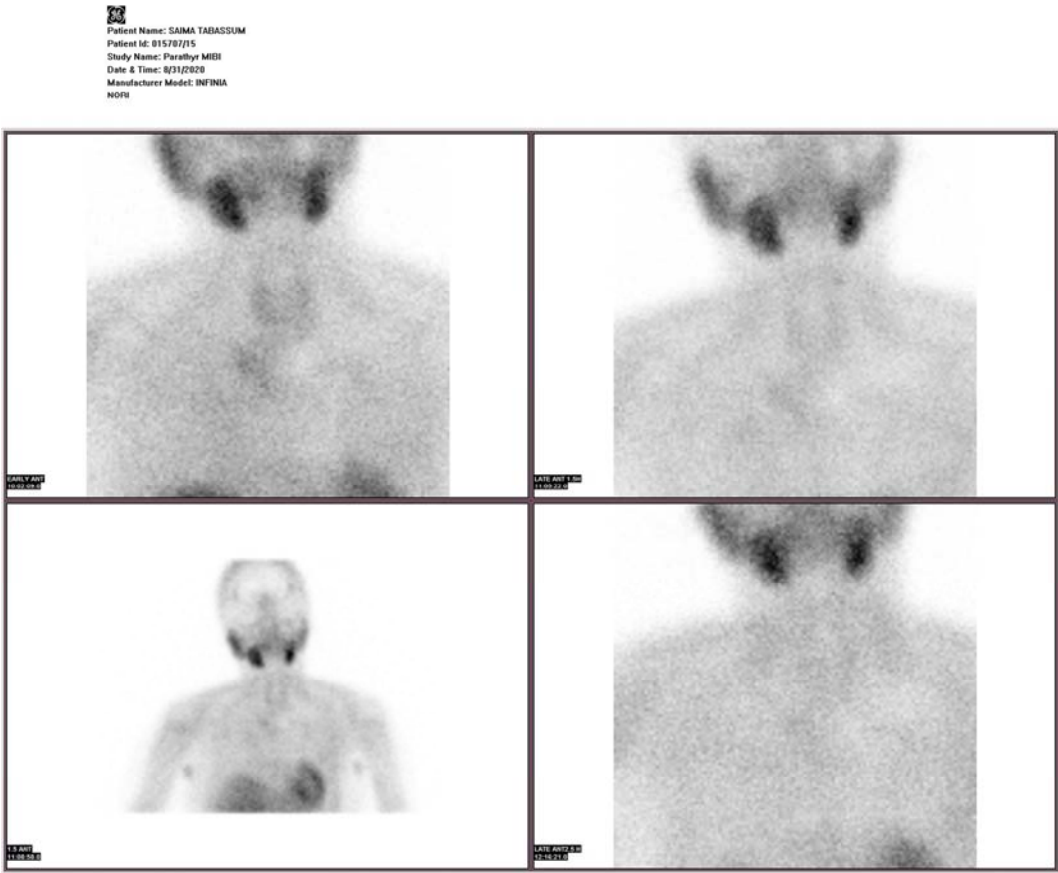


Figure 3. Showing parathyroid adenoma in the right parathyroid below the clavicle in 2020.

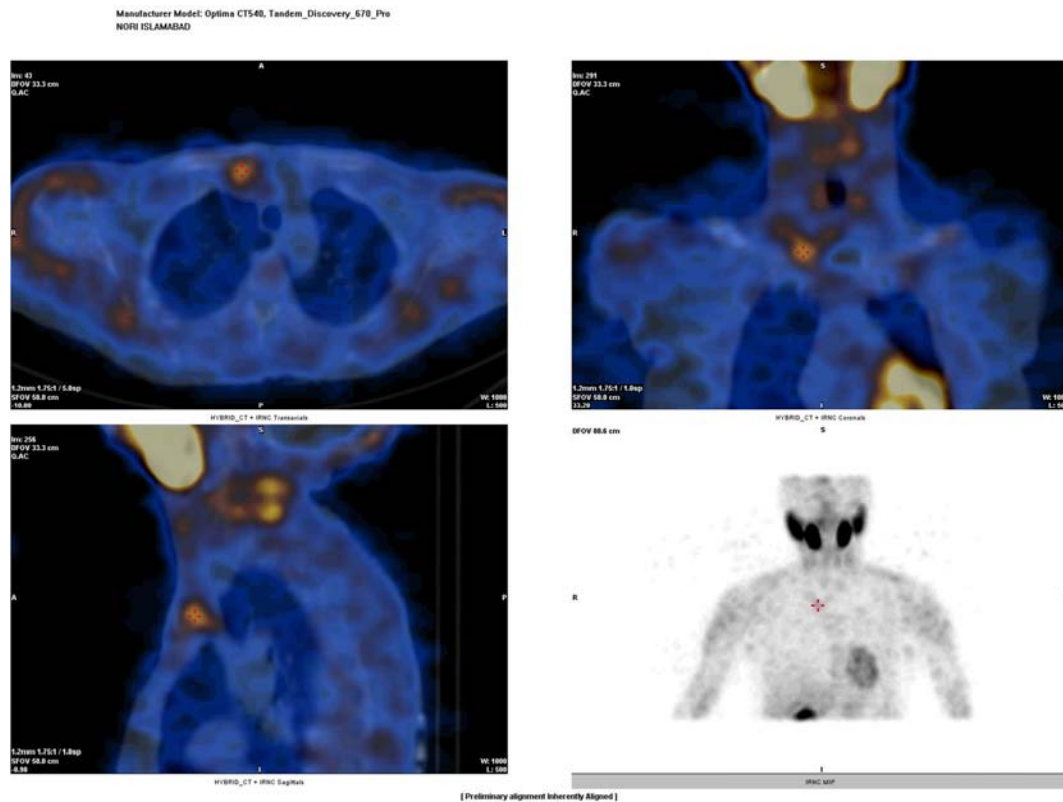


Figure 4. Showing radiotracer uptake below the right clavicle in recurrent parathyroid adenoma on SPECT/CT.

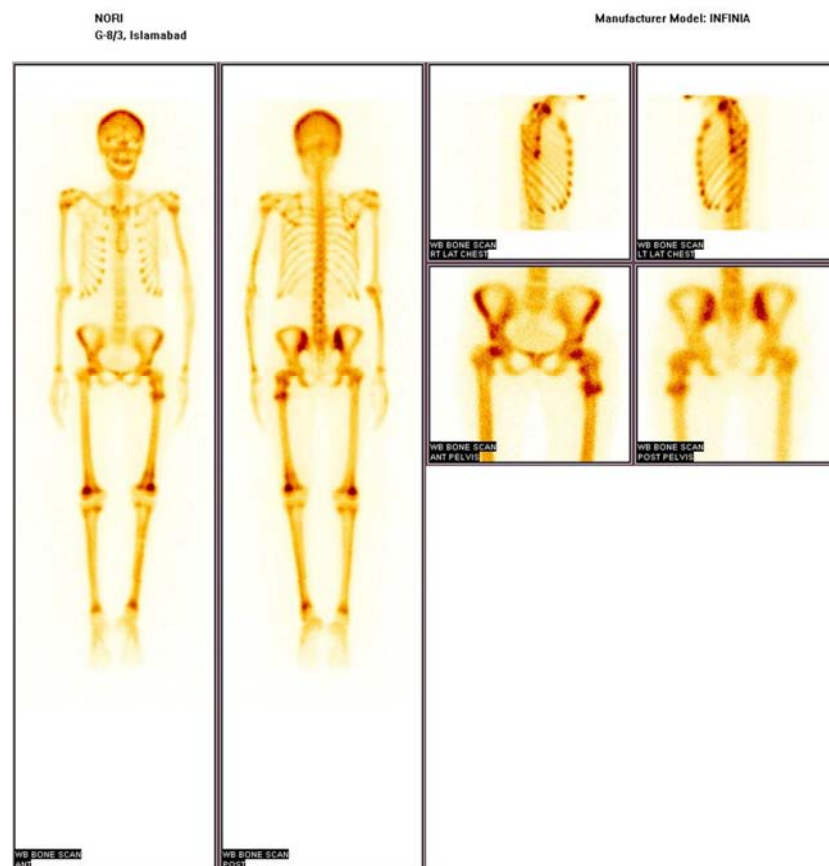
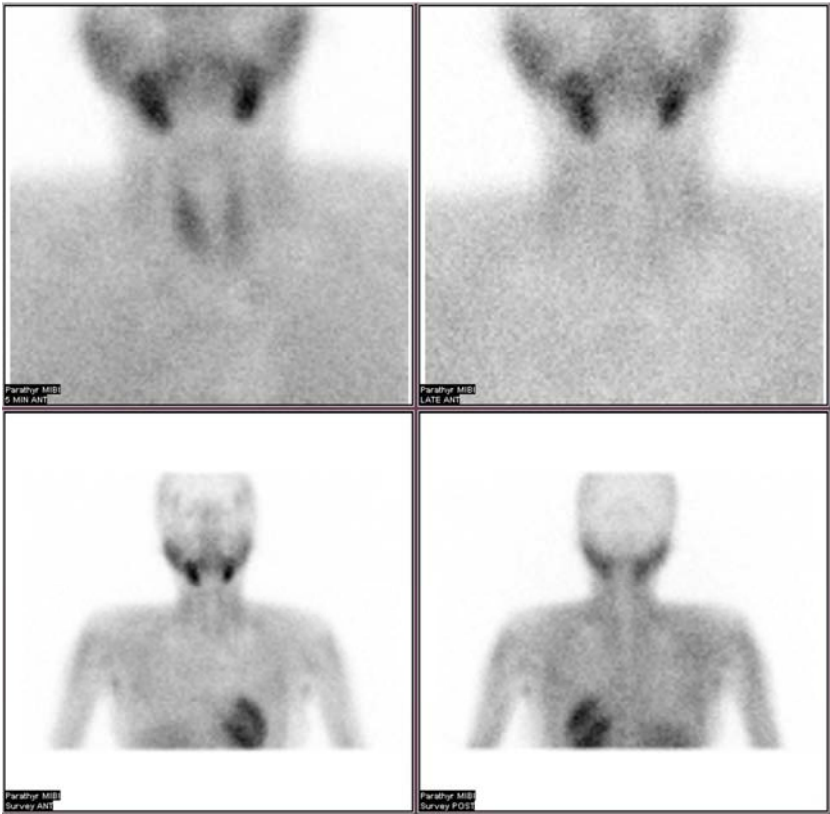
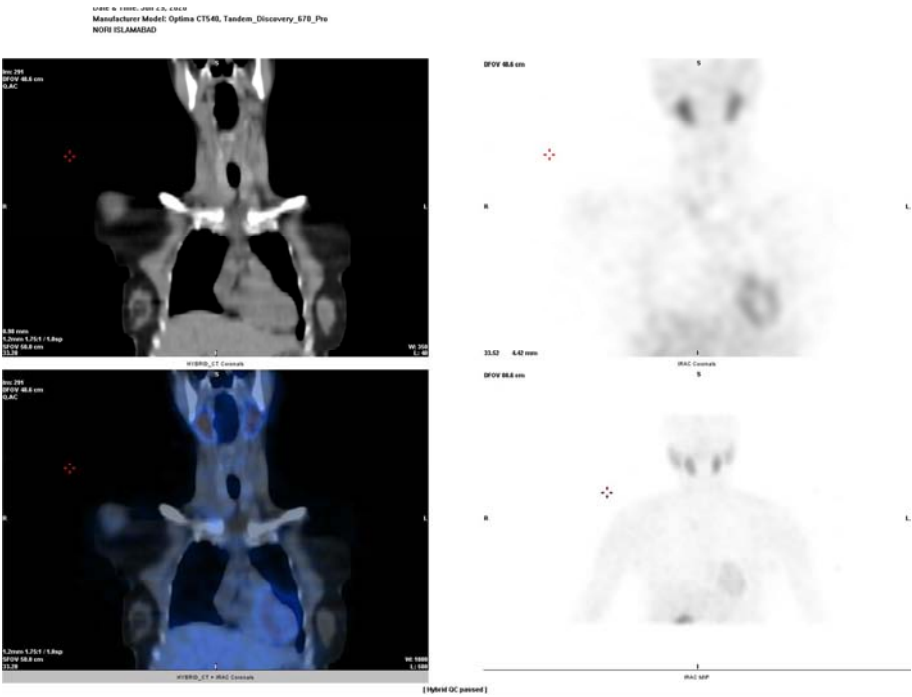


Figure 5. Showing metabolic like findings on bone scan of same patient.



6a



6b

Figure 6. Showing no radiotracer uptake in the neck and mediastinum in 2020 on planar as well as SPECT CT imaging.

Conflict of Interests

All the authors donot have any possible conflicts of interest.
None

Ethical Approval

Ethical approval is not required at our institution for publishing a case report in a medical journal.

Authors' Contribution

All authors contributed to the drafting, revising and final editing of the manuscript.

References

- [1] Moreno MA, Callender GG, Woodburn K, Edeiken-Monroe BS, Grubbs EG, Evans DB, Lee JE, Perrier ND. Common locations of parathyroid adenomas. *Ann Surg Oncol*. 2011; 18 (4): 1047-51.
- [2] Dasgupta DJ, Navalkisoor S, Ganatra R, Buscome J. The role of single-photon emission computed tomography/ computed tomography in localizing parathyroid adenoma. *Nucl Med Commun*. 2013; 34: 621-6.
- [3] Judson BL, Shaha AR. Nuclear imaging and minimally invasive surgery in the management of hyperparathyroidism. *J Nucl Med*. 2008; 49 (11): 1813-8.
- [4] Heffess CS. Embryology, anatomy, and histology. In: Wenig B, editor. *Atlas of head and neck pathology*. 2nd ed. China: Saunders Elsevier; 2008. p. 1012-28.
- [5] Rattner, D. W., Marrone, G. C., Kasdon, E. & Silen, W. Recurrent hyperparathyroidism due to implantation of parathyroid tissue. *Am J Surg* 1985, 149, 745-748.
- [6] Smith, J. F. & Coombs, R. H. Histological diagnosis of carcinoma of the parathyroid gland. *J Clin Pathol* 1984, 37, 1370-1378.
- [7] International Atomic Energy Agency (IAEA), editor. *Guided Intraoperative Scintigraphic Tumour Targeting (GOSTT): implementing advanced hybrid molecular imaging and non-imaging probes for advanced cancer management*. Vienna: IAEA; 2014.
- [8] M. Araujo Castro, A. A. López, L. M. Fragueiro, and N. P. García, "Giant parathyroid adenoma: differential aspects compared to parathyroid carcinoma," *Endocrinology, Diabetes & Metabolism Case Reports*, 2017. View at: Publisher Site | Google Scholar.
- [9] M. Ahmad, M. Almohaya, N. Al Johani, and M. Almalki, "Intrathyroidal Parathyroid Cyst: An Unusual Neck Mass," *Clinical Medicine Insights: Endocrinology and Diabetes*, vol. 10, no. 0, 2017. View at: Publisher Site | Google Scholar.
- [10] Wong KK, Fig LM, Gross MD, Dwamena BA. Parathyroid adenoma localization with 99mTc-sestamibi SPECT/CT: a meta-analysis. *Nucl Med Commun*. 2015; 36: 363-75. PubMed Cross Ref Google Scholar.
- [11] Amza AB, Muntean V, Dindelegan G, Ciuce C, Georgescu CE. Surgery Outcomes in Patients with Secondary Hyperparathyroidism and Impact of Intra-Operative PTH Measurement. *Acta Endocrinologica-Bucharest*. 2017; 13 (3): 322-328 [PMC free article] [PubMed] [Google Scholar].
- [12] Lezaic L, Rep S, Sever MJ, Kocjan T, Hocevar M, Fettich J. 18F-Fluorocholine PET/CT for localization of hyperfunctioning parathyroid tissue in primary hyperparathyroidism: a pilot study. *Eur J Nucl Med Mol Imaging*. 2014; 41: 2083-9. Pub Med Cross Ref Google Scholar.
- [13] Kluijfhout WP, Vorselaars WM, Vriens MR, Borel Rinkes IH, Valk GD, de Keizer B. Enabling minimal invasive parathyroidectomy for patients with primary hyperparathyroidism using Tc-99m-sestamibi SPECT-CT, ultrasound and first results of 18F-fluorocholine PET-CT. *Eur J Radiol*. 2015; 84: 1745-51. Pub Med Cross Ref Google Scholar.
- [14] Estrems P, Guallart F, Abreu P, Sopena P, Dalmau J, Sopena R. The intraoperative mini gamma camera in primary hyperparathyroidism surgery. *Acta Otorrinolaringol Esp*. 2012; 63: 450-7. Pub Med Cross Ref Google Scholar.
- [15] Abdulla AG, Ituarte PHG, Harari A, Wu JX, Yeh MW. Trends in the frequency and quality of parathyroid surgery: analysis of 17,082 cases over 10 years. *Ann Surg*. 2014: 1-5.
- [16] Yeh MW, Wiseman JE, Chu SD, et al. Population-level predictors of persistent hyperparathyroidism. *Surgery* 2011; 150: 1113-9.