



## Case Report

# A Very Rare Case of Mixed Intercostal Hemangioma and Literature Review

El-Ghazzaoui Ali<sup>1</sup>, Bedoyan Zarouhie<sup>2</sup>, Kawkabani Nadine<sup>3,\*</sup>, Abou-Khalil Bassam<sup>4</sup>

<sup>1</sup>Pediatric Surgery Resident, Saint Georges Hospital University Medical Center-University of Balamand, Beirut, Lebanon

<sup>2</sup>Anatomic Pathology Department, Saint Georges Hospital University Medical Center, Beirut, Lebanon

<sup>3</sup>Cardiac Surgery Anesthesia Department, Saint Georges Hospital University Medical Center, Beirut, Lebanon

<sup>4</sup>Cardio-Thoracic Surgery Department, Saint Georges Hospital University Medical Center, Beirut, Lebanon

## Email address:

[nadine\\_kaoukabani@yahoo.com](mailto:nadine_kaoukabani@yahoo.com) (K. Nadine)

\*Corresponding author

## To cite this article:

El-Ghazzaoui Ali, Bedoyan Zarouhie, Kawkabani Nadine, Abou-Khalil Bassam. A Very Rare Case of Mixed Intercostal Hemangioma and Literature Review. *International Journal of Cardiovascular and Thoracic Surgery*. Vol. 3, No. 1, 2017, pp. 1-4.

doi: 10.11648/j.ijcts.20170301.11

**Received:** September 28, 2016; **Accepted:** February 13, 2017; **Published:** March 1, 2017

**Abstract:** Hemangiomas affecting the chest wall are rare. The literature suggests sporadic cases of these chest wall tumors. We report in this paper a very rare subtype of intercostal hemangiomas (mixed subtype). We describe the physical, clinical, imaging and pathology findings as well as the surgical therapeutic procedure. In addition we review the literature for similar cases reported.

**Keywords:** Chest Wall Tumor, Intercostal Hemangioma, Mixed Sub Type Tumors

## 1. Introduction

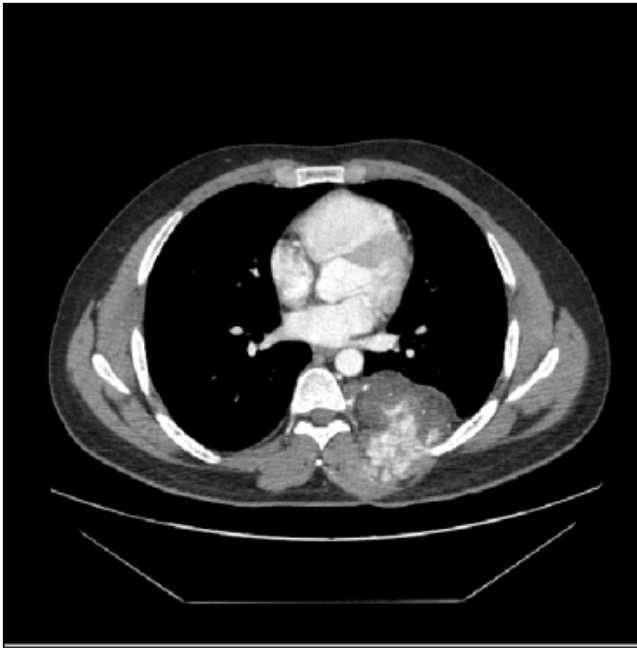Vascular tumors affecting the chest wall are very rare[1]. They are benign vascular tumors and are classified in five subtypes including the mixed tumors. The literature describes sporadic case reports of chest wall hemangiomas[1]. We report in this paper a very rare subtype of intercostal hemangiomas: the mixed subtype. We describe the physical, clinical, imaging and pathology findings as well the surgical therapeutic procedure that helped achieving a complete recovery of our patient. We also review the literature for similar cases.

## 2. Case Report

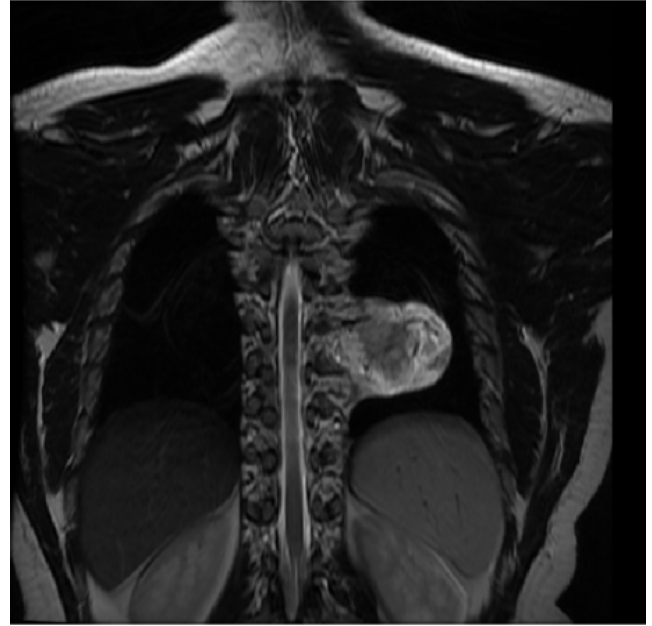
A 22 years old male patient was referred to us from another institution after performing an open biopsy for a left chest wall mass posteriorly. The patient was asymptomatic and had noticed an increase in the size of the mass over the last 2 months. He had an open biopsy at the other institution showing a hemangioma. The patient was known to be healthy,

non- smoker and with no previous medical or surgical histories. He denied recent trauma to that site. On physical exam, the mass could be felt upon palpation of the left posterior chest wall. No bruits or abnormal breath sounds were heard upon auscultation of the lung and mass.

CT scan of the chest with IV contrast showed a Hemangioma measuring 5.5 cm in height and 7.5 \* 6.5 cm in cross-section, located in the posterior intercostal space between the posterior arches of the left 7<sup>th</sup> and 8<sup>th</sup> ribs, with scalloping of these and showing spur-like formations, lateral to the descending aorta, spine and coming in contact with the para-spinal muscles. The Hemangioma extended from the 6<sup>th</sup> intercostal space to the 9<sup>th</sup> intercostal space. It showed a nodular and central enhancement after IV contrast injection and was supplied by the left 8<sup>th</sup> posterior intercostal artery and draining into the Azygos vein. (Figure 1)



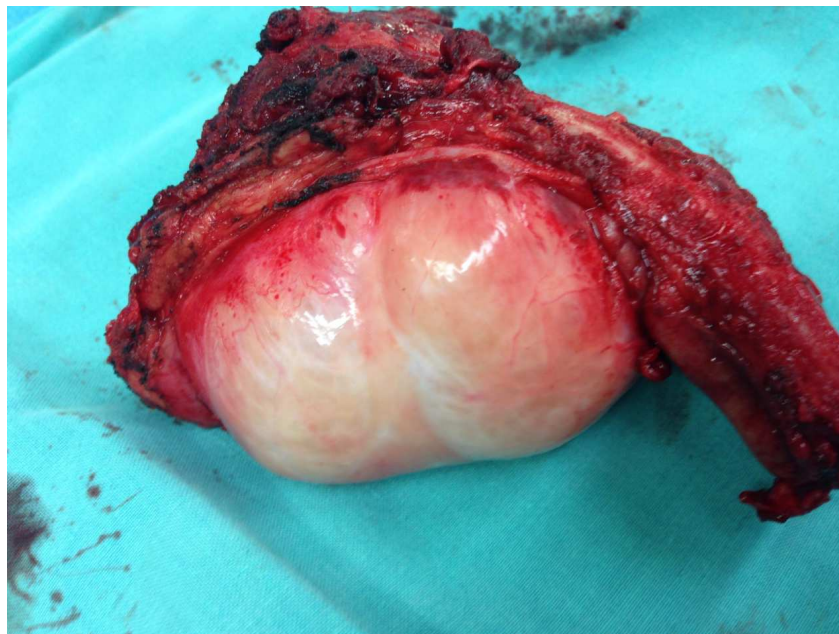
**Figure 1.** Axial CT scan Cut showing homogeneous enhancement of the Hemangioma during the arterial phase.



**Figure 2.** The MRI shows a 7\*7\*6 cm mass in the posterior aspect of the left chest wall between T7 and T11.

His MRI showed a 7 \* 7 \* 6 cm lesion in the posterior aspect of the left chest wall between T7 and T11 (Figure 2). The lesion did not invade the aorta or the spine. It did not enhance on T1 sequence but showed homogenous enhancement on T2 sequence and enhances more post IV gadolinium injection.

An arteriogram was not done. Patient was scheduled for thoracotomy to remove the mass. Intra-operatively, the 7<sup>th</sup> and 8<sup>th</sup> ribs were removed along with the mass that measured 7\*7\*5.5 cm (Figure3).



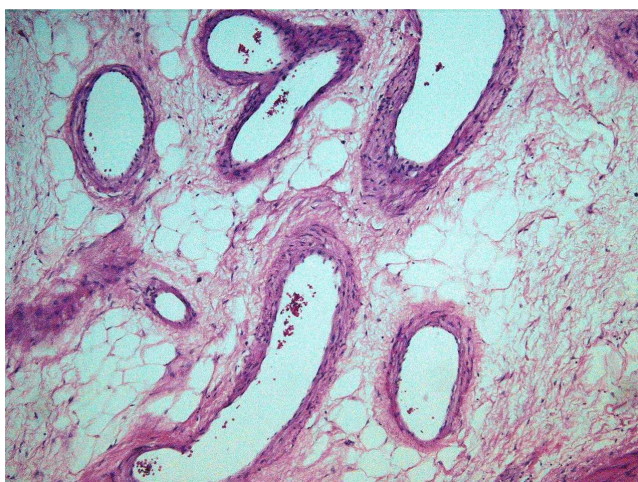
**Figure 3.** Hemangioma after resection (7\*7\*5.5cm). Its smooth contour and crossing of all the intercostal layers is seen.

The feeding artery which turned out to be a branch from the descending aorta and not from the intercostal artery is ligated. The defect was repaired using Gore-Tex Mesh. Pathology reported the presence of thick walled blood vessels alternating with areas of proliferation of cavernous dilated thin walled blood vessels and capillary sized blood vessels with regular

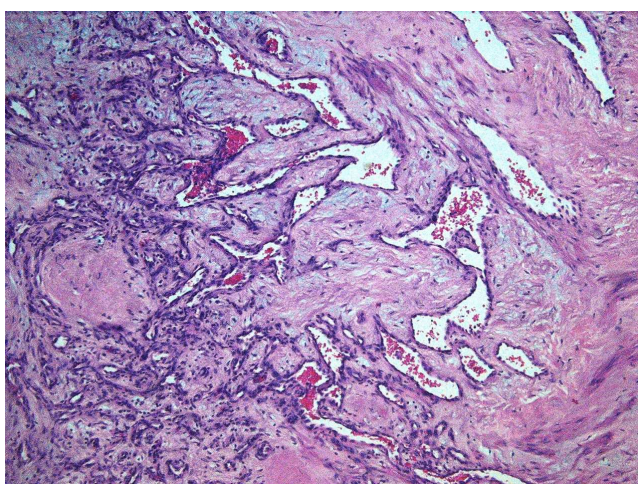
endothelial lining. The proliferation had a lobular pattern devoid of infiltrative pattern, all suggestive of mixed intercostal hemangioma (Figure 4 and 5).

The Patient had a smooth postoperative course and was discharged home on day 5. He is still doing well six month after the procedure, No recurrence of the lesion is reported.





**Figure 4.** Thick walled blood vessels. F.



**Figure 5.** Capillary sized (on the left) and Cavernous vessels (on the Right).

### 3. Discussion

Primary soft tissue neoplasms of the chest wall are rare. The most common benign lesions in adults are lipomas, and other benign tumors include neurogenic neoplasms of the intercostal nerves (neurofibroma and schwannoma), fibromas and angiofibromas of the intercostal muscles [2].

Hemangiomas are benign vascular tumors that account for 7% of all benign soft tumors in the entire body. They have been classified into five subtypes, i.e. capillary, cavernous, venous, arterio-venous and mixed [3]. The literature describes sporadic cases of different types of intercostal hemangiomas. Many papers reported venous tumors [4]-[5], arterio-venous entities[6], cavernous tumors[7], capillary hemangioma [8] and intramuscular large vessels type tumors[9]. Very rare cases of mixed intercostal hemangiomas were described. In fact very few cases of mixed tumors with capillary and cavernous components were encountered while reviewing the literature[9] [10].

The etiology of intramuscular Hemangiomas has been predominantly ascribed to two theories. The congenital origin is the most common cause and this is supported by the early

documentation during life. Scott theorized that abnormal embryonic sequestration may extend by establishing blood flow in fresh parts of a pre-existing malformation [11]. In addition to that, Hereditary does not seem to have a role since no two cases have been reported in the same family.

Trauma has been also implicated in the genesis of vascular anomalies. Its role may be to precipitate expansion of pre-existing condition or to produce small areas of granulation tissue and enlargement with continued disturbance[11]. Most patients present with a bulging mass from the lateral or posterior chest wall that is usually asymptomatic. Also, it can be found incidentally on imaging during workup for respiratory or cardiac complaints.

A diagnosis before surgery is difficult and it's easy to confuse these tumors with other malignant bone lesions that may require extensive resections. In our patient, the diagnosis was made pre-operatively from the open biopsy.

On CT scan, Intercostal Hemangiomas appear as homogenous, non-calcified muscular masses. IV administration of contrast causes homogenous enhancement of the mass usually. MRI is also used to confirm the diagnosis, and a skeletal muscle mass with a signal intensity similar to the adjacent muscles is seen on T1 sequence. On T2 sequence, after the administration of gadolinium, the mass enhances homogeneously. These CT and dynamic MR features allow differentiation of intercostal Hemangiomas from other benign extra-pleural or pleural tumors such as neurogenic tumors, localized fibrous tumors, and castleman's disease that can enhance after Intravenous contrast injection. Another feature distinguishing a Hemangioma from a localized fibrous tumor of the pleura is the high signal intensity of the former and typical low signal intensity of the latter on T2-weighted MR [2].

Arteriogram can be used pre-operatively to become familiar with the blood supply of the mass. Also, it can have therapeutic uses by embolization of the feeding vessels for lesser blood loss intra-operatively and for shrinking the mass. After embolization, prompt surgical resection should be done to prevent the occurrence of collateral circulation.

The standard treatment is complete surgical excision with clean margins. Chest wall reconstruction is considered if two ribs or more are resected. In a review of 89 cases of skeletal Hemangiomas, 18% recurred locally with 7% recurring more than once [8]. No distant metastases were described.

### 4. Conclusion

We describe in this paper a very rare subtype(mixed subtype) of intercostal hemangioma and we review the literature for similar cases. On the other hand we emphasize in this manuscript on the clinical, imaging and pathology findings that allow an accurate and correct diagnosis which is mandatory to define and direct optimal therapy. However more case reports are necessary in order to help us understand if the different subtypes of hemangiomas affect per se the prognosis and outcome.

---

## References

- [1] Murphy MD, Fairbairn KJ, Parman LM, Baxter KG, Pava MB, Smith WS: Musculoskeletal angiomatous lesions: radiologic-pathologic correlation. *Radiographics*.1995;15: 893-917.
- [2] Yuan Y, Matsumoto T, Miura M, Tanaka N, Emoto T, Kawamura T. et al: Imaging findings of an Intercostal Hemangioma. *Journal of Thoracic Imaging*.2002; 17: 92-95.
- [3] Agarwal P, Matzinger F, Maziak D, Dennie C: Case of the season: Intercostal Hemangioma. *Seminars in Roentgenology*.2006;41 (1): 4-6.
- [4] Dzian A and HamzikJ: Intercostal hemangioma of the chest wall:. *Kardishir torako chirurgia Pol*. 2016; 13 (1): 58-60.
- [5] Hashimoto H, Yoshiro Y, Obara K, Takeshima S, Sato K, Tanaka Y: Intercostal Venous Hemangioma presenting as a chest wall Tumor. *General Thoracic and Cardiovascular Surgery* (2009) 57; 228-230.
- [6] Kara M, Dikmen E, Sak SD, Kaverku S: Intercostal arteriovenous hemangioma. *European Journal of Cardio-thoracic surgery*.2000; 18: 622-624.
- [7] Ulku R, Onat S, Avci A, Ozmen CA: Resection of intercostals hemangiomawith involved chest wall and ribs. *Tex Heart Inst J*. 2010; 37 (4): 486-489.
- [8] Winchester D, Victor T, Fry W: Intercostal Hemangioma presenting as chest wall tumor. *The annals of Thoracic Surgery*. 1992; 54: 145-6.
- [9] Kubo M, Moriyama S, Nogami T, Kunitomo t, Nawa S: Intercostal Hemangioma. *Japanese Journal of Thoracic and Cardiovascular Surgery* 2004; 52: 435-438.
- [10] Yonehara Y, Nakatsuka T, Ichioka I, Takato T, Matsumoto S, Yamada A: Intramuscular Hemangioma of the anterior chest wall. *British journal of Plastic Surgery*. 2000; 53 (3): 257-9.
- [11] Sirmali M, Turu H, Findik G, Agackiran Y, Kaya S: A Huge Mass Destroying the Fifth Rib: A rare Case of Cavernous Hemangioma. *ActaChir Belg*, 2007; 107, 454-456.
- [12] Recuerda A, Rodriguez M. E, Giron J, Alvarez P, Pelillo J. C, Pajeulo M: Vascular tumors Arising in the Chest wall: 25 years Experience. *Arch Bronconeumol*. 2005; 41 (1): 53-6.