



Evaluation of Airway Volume and Area in Skeletal Class II Patients Treated with Forsus FRD Using 3D Acoustic Pharyngometry and Its Correlation with Cephalogram Data

Varun Govindraj^{1,*}, Sanjeev Datana², Shiv Shankar Agarwal², Deepak Chauhan³

¹Division of Orthodontics and Dentofacial Orthopedics, Command Dental Centre (WC), Chandimandir Cantt, India

²Department of Orthodontics and Dentofacial Orthopedics, Armed Forces Medical College, Pune, India

³Division of Orthodontics and Dentofacial Orthopedics, Corps Dental Unit (CC), Mathura Cantt, India

Email address:

drvarungovindaraj@gmail.com (V. Govindraj)

*Corresponding author

To cite this article:

Varun Govindraj, Sanjeev Datana, Shiv Shankar Agarwal, Deepak Chauhan. Evaluation of Airway Volume and Area in Skeletal Class II Patients Treated with Forsus FRD Using 3D Acoustic Pharyngometry and Its Correlation with Cephalogram Data. *International Journal of Clinical Oral and Maxillofacial Surgery*. Vol. 7, No. 2, 2021, pp. 40-45. doi: 10.11648/j.ijcoms.20210702.15

Received: August 29, 2021; **Accepted:** December 20, 2021; **Published:** December 29, 2021

Abstract: *Aim:* To evaluate, pre and post Forsus FRD treatment changes in mean airway volume and area measured in Acoustic Pharyngometer (AP) and to correlate the findings with lateral cephalogram data. *Material and Methods:* This study was planned on skeletal Class II malocclusion patients diagnosed with mandibular hypoplasia as a cause of Class II malocclusion, requiring fixed functional therapy. Pre-treatment AP records were recorded once the levelling and alignment phase was complete and Forsus FRD appliance was placed. Appliance treatment was continued till the desired objectives i.e optimal overjet and overbite were achieved. Post functional AP records were made at the end of functional therapy, after removal of Forsus FRD. *Results:* Post functional treatment indicated statistically significant changes on evaluation of upper airway dimensions of the subjects, in mean upper airway volume and area. *Conclusion:* Study concluded that Forsus FRD is an effective method for correction of skeletal Class II malocclusion among adolescent patients, enhancing significant increase in volume and area of hypopharyngeal and oropharyngeal spaces, thus improving the upper airway patency and as a reliable guide to prevent developing Obstructive Sleep Apnoea (OSA) in future in these individuals.

Keywords: Upper Airway Mean Area, Upper Airway Mean Volume, Acoustic Pharyngometry, Forsus FRD

1. Introduction

Growth and development of craniofacial structures, its relation with respiration and airway has been extensively studied due to its functional concern in orthodontics [1] It is agreed upon that the upper airway structures play a vital role in development of craniofacial structures [2] (Figure 1). Reduced airway dimensions in oropharyngeal structures leads to breathing difficulties in children's and obstructive sleep apnoea (OSA) in later stages [3]. Subjects with reduced airway dimensions generally depicts the features of skeletal Class II malocclusions with retrognathic or hypoplastic mandible [4] calls for a specific treatment to improve the position of mandible to increase the airway capacity [5]. In growing patients the treatment modalities to correct skeletal Class II

malocclusion with mandibular hypoplasia would be to redirect the mandibular growth by use of removable or fixed functional appliances. But in adolescent patients, camouflage or surgical repositioning the hypoplastic segment of the mandible remains the only modality [6] where compliance becomes a major issue to hinder the treatment efficiency and outcome. The efficiency of fixed functional appliances (FFA) has been established to overcome the compliance issue in adolescents since it does not require any monitoring or daily checks [7]. One such appliance classified as a hybrid FFA are Forsus Fatigue Resistant Device (FRD) a combination of rigid and flexible fixed functional appliances for the correction of skeletal Class II in non-compliant patients [8, 9].

Forsus FRD produce 80% of dentoalveolar changes, 20% of skeletal changes with a definite change in the airway

patency. The concluding studies were based on 2D lateral cephalogram which is of limited clinical value representing the three dimensional (3D) structures in two dimension (2D). Since the evolution of Cone Beam Computer Tomography (CBCT), it has transformed the state of diagnosis and treatment planning in orthodontics still there are little consensus whether CBCT can provide better assessment in evaluating the dynamic airway functions [10].

Quest for assessment of dynamic airway structures to obtain a reliable consensus at par with CBCT in evaluation of Obstructive Sleep Apnoea (OSA) lead to the introduction of Acoustic Pharyngometry (AP), a non-invasive modality to assess the dynamic pharyngeal regions in terms of areas and volumes of specific airway zones without any radiation exposure [11]. This study aims to evaluate the mean changes in airway volume and area (pre and post) in skeletal Class II adolescent patients treated with Forsus FRD (Figure 1) measured using AP and correlate these findings with lateral cephalogram data and other CBCT studies on airways.

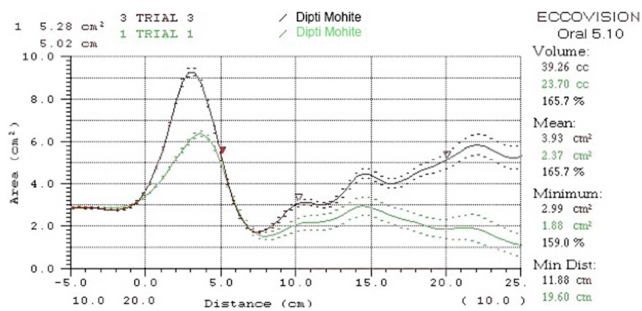


Figure 1. Acoustic pharyngometry depiction of volume and area on monitor.

2. Methodology

This prospective observational study was done with a sample size of 15 subjects (7 male & 8 female). Patients were diagnosed as cases of skeletal Class II malocclusion with mandibular hypoplasia with a h/o snoring and deprived sleep. Inclusion criteria set for the study was, age of 14-16 yrs with the ANB value range of $5^{\circ} \pm 2^{\circ}$ planned for non-extraction treatment. Exclusion criteria were patients with cleft lip and palate, poor periodontal condition, any previous history of orthodontic treatment. Patients were bonded with fixed orthodontic pre adjusted edgewise appliance (PEA) with 0.018" Roth prescription. Conventional wire sequence was followed till 0.017"x0.025"SS arch wire. Once the levelling and alignment was completed AP readings (upper airway volume and area) were recorded. Apparatus used for the study was "Eccovision Acoustic Pharyngometer". Subjects were asked to sit with their back straight and head straight, gazing at distant area and breathing normally. A disposable mouthpiece attached to wave tube was placed to stabilise the tongue as well as to get a reproducible bite position, with the mouth piece oriented horizontally to the ground. They were instructed to occlude the nostrils with their left hand to prevent air leak through the nose and breathe normally through the mouth. Once they were acquainted, subjects were asked to pause breathing and at end expiration, acoustic measurements of upper airway was made.

Pre Forsus, AP readings were recorded (T1) followed by placement of maxillary and mandibular components of Forsus FRD, enabling the complete compression of the springs till the satisfactory mandibular translation is achieved. Forsus FRD was continued until Angel's Class I, 1st molar relation with an optimum overjet of 2-3 mm as well as satisfactory improvement in soft tissue profile is achieved. Post Forsus, AP records were made at the end of functional therapy (T2). Pre and Post Forsus, pharyngogram (Figure 2) was measured between the oropharyngeal junction up to the glottis and compared for changes in airway volume and area. The total duration of the treatment was 6-8 months.

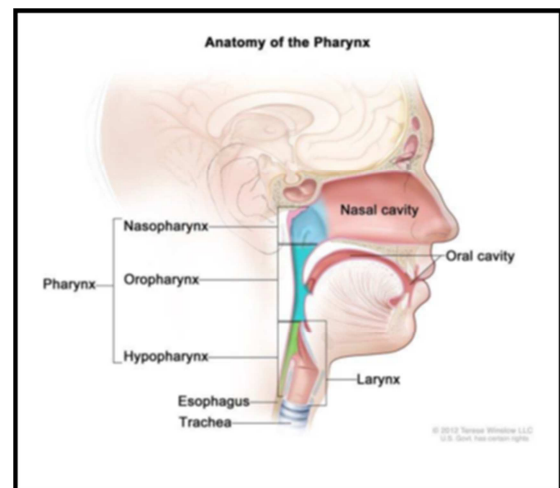


Figure 2. Pharyngeal airway parameters.

3. Statistical Data Analysis

The data collected for the study was in form of linear measurements recorded on lateral cephalograms at T1 and T2, along with area and volume of upper airway space calculated on AP at T1 and T2. The data on categorical variables are shown as n (% of cases) and the data on continuous variables are presented as Mean and Standard deviation (SD). The statistical significance of pair-wise difference of means of continuous variables tested using paired 't' test. Correlation analysis is done using Pearson's method. The underlying normality assumption was tested before subjecting the study variables to the 't' test and Pearson's correlation analysis. In the entire study, the p-values less than 0.05 was considered to be statistically significant. The entire data is statistically analysed using Statistical Package for Social Sciences (SPSS version 21.0, IBM Corporation, USA) for MS Windows.

4. Result

Post treatment airway assessment of the subjects depicts statistically significant improvement in upper airway parameters especially in the posterior airway spaces (PAS) in lateral cephalometry (Table 1) as well as in acoustic pharyngometry (Figure 1), indicating a definite improvement in airway patency along with correction of retrognathic mandible.

5. Discussion

Skeletal Class II malocclusion is the most prevalent malocclusion accounts for 19 – 20% of all malocclusion globally [12, 13]. Most common aetiology being the hypoplastic mandible in relation to cranial base structures [14] which tends to restrict the airway patency. Development of the orofacial structures are all genetically mediated, continues till 13-15 years [15]. Similarly the growth of nasopharyngeal structures continues till 14-16 years of age following which the plateau is achieved. According to Goncalves et al trend of growth of nasopharyngeal structures during puberty is greater in boys than girls in accordance to body height [16]. Adolescents with developing skeletal Class II malocclusion with mandibular retrognathism are associated with backward posture of soft palate and tongue which contributes to the constrictions of the oropharyngeal airway space [6, 17], (Figure 2) thus increasing the susceptibility for snoring and OSA [18]. Radiographic evaluation by Ozbek et al hypothesised that the functional orthopaedic treatment in adolescents with skeletal Class II malocclusion may increase the oropharyngeal airway dimensions which may reduce the risk of developing impaired respiratory functions in long term [19], in conclusion with the present study stating an early orthodontic intervention becomes warranted to prevent any developing serious airway conditions which may hamper day to day life and in turn effect their quality of life in future.

Taki et al [10] evaluated the effects of functional appliance (activator and Forsus) on the upper airway to conclude that there are no significant differences in the lateral cephalometric airway measurements i.e nasopharyngeal airway space (NAS), oropharyngeal airway space (PAS) and hypopharyngeal airway space (HAS) measured pre and post treatment. Meta-analysis by Xiang et al [20] concluded that functional appliance do produce positive changes especially in oropharyngeal region (PAS) by anterior bodily translation of mandible rather than influencing the growth of mandible. To explain the effects of FFA on airway more precisely Temani et al [21] evaluated the volumetric changes following fixed functional treatment in skeletal Class II case. Study concluded that

there was a definite increase in pharyngeal airway space especially in the oropharynx which may prevent developing OSA. CBCT study by Behrents et al [22] on patients diagnosed with mild – moderate OSA, also concluded that the use of mandibular anterior positioner appliance improved the airway and prevented the later development of OSA. This study also concurs that early intervention with Forsus FRD in skeletal Class II mandibular hypoplastic cases will definitely improve the airway to reduce any airway abnormalities (Figures 3, 4, 5) (Tables 1, 2).

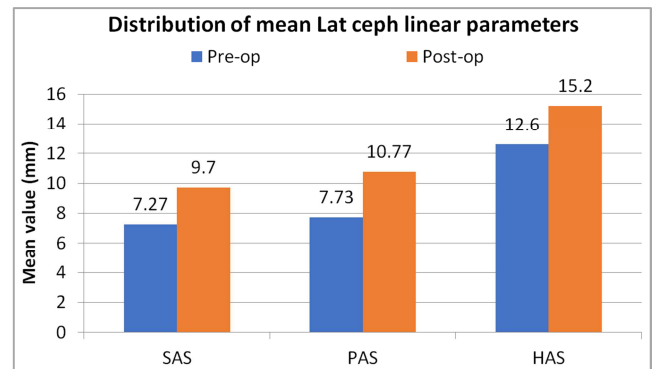


Figure 3. Distribution of mean pre-op and post-op distribution of lat ceph linear parameters.

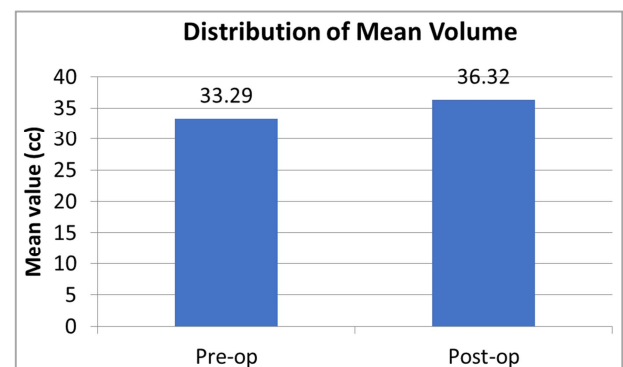


Figure 4. Distribution of mean pre-op and post-op mean volume.

Table 1. Comparison of mean pre-op and post-op lat ceph linear parameters.

Parameters	Pre-op (n=15)		Post-op (n=15)		Mean Difference (95% CI)	P-value
	Mean	SD	Mean	SD		
NAS (mm)	7.27	1.75	9.70	1.69	-2.43 [-3.03 to -1.83]	0.001***
PAS (mm)	7.73	2.25	10.77	2.79	-3.03 [-3.70 to -2.37]	0.001***
HAS (mm)	12.60	2.19	15.20	2.00	-2.60 [-3.38 to -1.82]	0.001***

P-values by Paired t test. P-value<0.05 is considered to be statistically significant. ***P-value<0.001.

Table 2. Comparison of mean pre-op and post-op acoustic pharyngometry parameters.

Parameters	Pre-op (n=15)		Post-op (n=15)		Mean Difference (95% CI)	P-value
	Mean	SD	Mean	SD		
Volume (cc)	33.29	7.26	36.32	8.39	-3.04 [-6.07 to -0.001]	0.050*
Area (cm ²)	3.33	0.72	3.63	0.84	-0.30 [-0.60 to -0.005]	0.047*

P-values by Paired t test. P-value<0.05 is considered to be statistically significant. ***P-value<0.001.

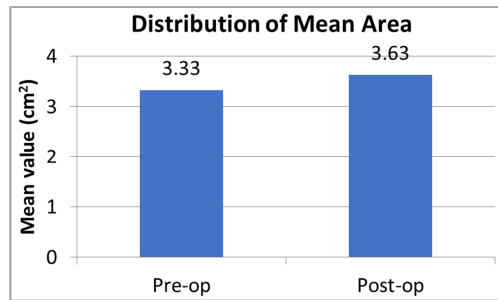


Figure 5. Distribution of mean pre-op and post-op mean area.

Santos et al [23] evaluated the mean airway volume and location of maximum constriction area (MCA) in different dentofacial deformities to suggest that, the MCA in skeletal Class II malocclusion is at the region of oropharynx. Launois et al [24] suggested the site of maximum constriction extends anteriorly from the base of the tongue/ base of the epiglottis to the walls of pharynx posteriorly termed as posterior airway space / oropharyngeal airway space (PAS) in lateral cephalograph. Study concluded that, PAS may be the prime indicator to determine the condition of OSA rather than mean volume or airway length. Abramson et al [25] suggested the correlation of OSA and MCA stating Poiseuille's law to depict the collapsing tendency of the pharynx due to decreased resistance of walls of the pharynx proportional to its length and inversely proportional to its radius. This study demonstrated the susceptibility to OSA due to resistance for the passage of air as the airway passage gets narrower. Bakker et al [26] located the exact location of MCA and the prognosis following functional therapy by depicting the improvement in constriction of passage using AP as highlighted in this study (Figure 6).

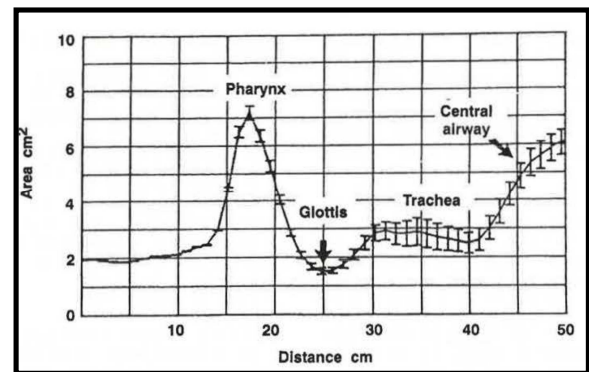


Figure 6. Oropharyngeal measured parameters depicted in ap.

Systemic review by Zimmerman et al [27] highlighted the variations in inter/intra examiner reliability while evaluating airway volume and area using CBCT. Study also recommended a word of caution while interpreting the marked areas of interest and the way of recording the dynamic and complex airway structure in a state of rest. AP used in this study is able to assess the complex upper airway in its dynamic state without the risk of radiation exposure without any examiners bias.

Martins et al [28] correlated the airway parameters in both 2D and 3D (CBCT) dimensions to conclude that the oropharynx which extends from the base of soft palate to the base of tongue as a useful guide to represent the airway. Present study evaluates the volume and area of the oropharynx using AP and correlating the 2D PAS value with AP parameters (volume and area) concludes that there is a significant change in the airway dimensions of oropharynx post Forsus treatment (Figures 7, 8) (Table 3).

Table 3. Correlation analysis between pre-op and post-op change in lat ceph linear parameter (pas) and pre-op and post-op change in acoustic pharyngometry parameters.

Pre-op and Post-op Lat ceph linear parameters	Pre-op and Post-op acoustic pharyngometry parameters			
	Volume		Area	
	r-value	P-value	r-value	P-value
PAS	0.853	0.001***	0.852	0.001***

Correlation analysis by Pearson's method. P-value<0.05 is considered to be statistically significant correlation. ***P-value<0.001.

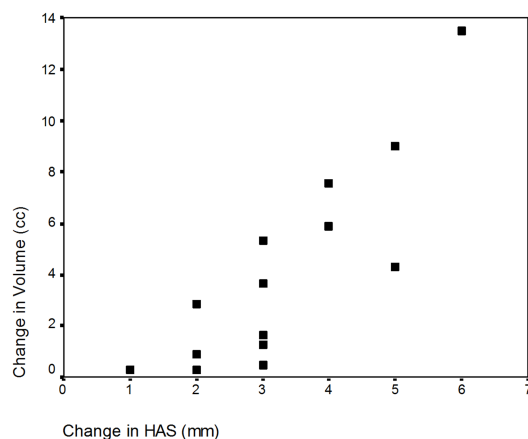


Figure 7. Scatter diagram depicting correlation analysis between 2d (pas) and 3d (volume) post treatment.

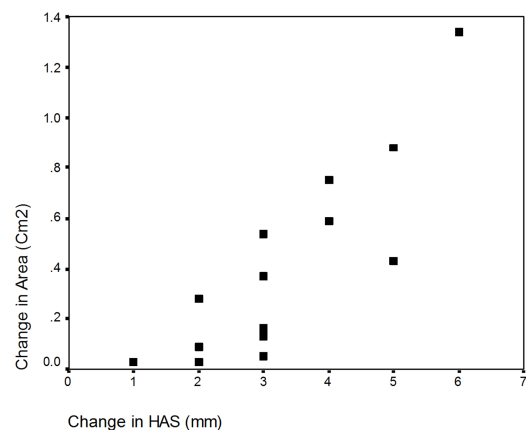


Figure 8. Scatter diagram depicting correlation analysis between 2d (pas) and 3d (area) post treatment.

6. Conclusion

Forsus FRD are the effective treatment modality to treat adolescent skeletal Class II non-compliant patients with mandibular hypoplasia. They bring about forward mandible translation along with adaptive changes in its structures and function results in definite improvement in volume and area of oropharynx during adolescent period. Acoustic Pharyngometer acts as a stand-alone test along with lateral cephalometric measurements for better evaluation of probable sites of airway obstruction in oropharynx and to assess the improvement following functional therapy in a dynamic state. This apparatus is fast, non-invasive, cost effective, reliable and reproducible depicted in the form of normal curves. However, long term implications of this treatment needs further consideration.

Conflict of Interest

All the authors do not have any possible conflicts of interest.

Ethical Committee Information

Letter no IEC/Oct/2017 dated 16 Oct 2017.

References

- [1] McNamara JA. (1981). Influence of respiratory pattern on craniofacial growth. *Angle Orthod*, 51, 269-00.
- [2] Martin O, Mueles L, Vinas M J. Nasopharyngeal cephalometric study of ideal occlusions. (2006). *Am J Orthod Dentofacial Orthop*, 130, 436-9.
- [3] Born J, Muth S, Fehm H L. (1988). The significance of sleep onset and slow wave sleep for nocturnal release of growth hormone and cortisol. *Psychoneuroendocrinology*, 13, 233-243.
- [4] Battagel J M, Johal A, Koetcha B. (2000). A cephalometric comparison of subjects with snoring and obstructive sleep apnoea. *Eur J Orthod*, 22, 353-365.
- [5] Resrepo, C., Santamaria, A., Palaez, S. and Tapias, A. (2011) Oropharyngeal airway dimension after treatment with functional appliances in Class II retrognathic children. *J Oral Rehabil*, 38 (8), 588-94.
- [6] Gunay, E. A. and Arun Talbantgil, D. (2011). Evaluation of the immediate dentofacial changes in late adolscnt patients treated with the Forsus FRD. *Eur J Orthod*, 5, 423-431.
- [7] GraberT, Vanarsdall Jr, Vig K. (2005). *Orthodontics current principles & techniques*. 6th ed. St Louis Missouri: Elsevier, 396-00.
- [8] Ritto AK, Ferreira AP. Fixed functional appliances—A classification. (2000). *Funct Orthod*, 17, 2–32.
- [9] Vogt W. (2006). The forsus fatigue resistant device. *J Clin Orthod*, 13, 368-76.
- [10] Taki AA, Ghaffarpasand A. (2015). Effects of functional appliance therapy on the depth of the pharyngeal airways: Activator vs Forsus. *J Dent Health Oral Disord Therapy*, 3, 1-7.
- [11] Urzo AD, Lawson VG, Vassal KP. (1987). Airway area by acoustic response measurements and computerized tomography. *Am Rev Respir Dis*, 125, 392-398.
- [12] Alhammadi MS, Halboubi E, Fayad MS, Labib A, Saidi CE. (2018). Global distribution of malocclusion traits: A systemic review. *Dent Press J Orthod*, 23, 1-10.
- [13] Siddegowda R, Satish RM. (2014). The prevalence of malocclusion and its gender distribution among school children: An epidemiological survey. *SRM J Res Dent Sci*; 5, 224-229.
- [14] McNamara JA Jr. (1981). Components of Class II malocclusion in children 8–10 years of age. *Angle Orthod*, 51, 177–202.
- [15] Krogman MR. (1967). The role of genetic factors in the human face, jaws and teeth. A review. *The Eugen Rev*, 59, 161-191.
- [16] Goncalves R C, Raveli D B, Pinto A S. (2011). Effect of age and gender on upper airway, lower airway and upper lip growth. *Braz Oral Res*, 25 (3), 241-7.
- [17] Muto T, Yamakazi A, Takeda S. (2008). A cephalometric evaluation of pharyngeal airway space in patients with mandibular retrognathia and prognathia and normal patients. *Int J Oral Maxillofac Sur*, 37 (3), 228-231.
- [18] Schwab R. (2003). Sleep apnoea is an anatomic disorder. *Am J Resp Crit Care Med*, 168, 270-271.
- [19] Ozbek MM, Memikoglu TU, Gogen H, Lowe AA, Baspinar E. (1998). Oropharyngeal airway dimensions and functional orthopedic treatment in skeletal Class II cases. *Angle Orthod*, 68 (4), 327-36.
- [20] Xiang ML, Hu B, Liu Y, Sun J, Song J. (2017). Changes in airway dimensions following functional appliances in growing patients with skeletal class II malocclusion: A systemic review and meta-analysis. *Intl J Ped Otolaryn*, 97, 170-180.
- [21] Temani P, Jain P, Rathee P, Temani R. (2016). Volumetric changes in pharyngeal airway in Class II division 1 patients treated with Forsus fixed functional appliance: A three-dimensional cone beam computed tomography study. *Contemp Clin Dent*, 7, 31-35.
- [22] Behrents, R. G., Shegikar, A. V., Conley, R. S., Mir, C. F., Hans, M., Levine, M., McNamara, J. A., Palomo, J. M., Pilska, B., Stockstill, J. W., Wise, J., Murphy, S., Nagel, N. and Hittner, J. (2019) Obstructive sleep apnoea and orthodontics: An American association of orthodontics white paper. *American Journal of Orthodontics and Dentofacial Orthopedics*, 156, 13-28.
- [23] Santos L, Albright D, Dutra V, Bhamidipall SS. (2020). Is there a correlation between airway volume and maximum constriction area location in different dentofacial deformities. *J Oral Maxfacial Surg*, 78 (8), 112-115.
- [24] Launois SH, Feroah TR, Campbell WN, Issa FG, Morrison D, Whitlaw WA. (1993). Site of pharyngeal narrowing predicts outcome of surgery of obstructive sleep apnoea. *Am Rev Respir Dis* 1993, 147, 182-189.

- [25] Abramson Z, Susarla S, August M, Troulis M, Kaban L. (2010). Three dimensional computed tomographic analysis of airway anatomy in patients with OSA. *J Oral Maxillofac Surg*, 68, 354-362.
- [26] De Young, Bakker J P, Anwar S B, Connolly J G, Butler J P, Malhotra A. (2013). Acoustic Pharyngometry measurement of minimal cross sectional airway area is a significant independent predictor of moderate to severe obstructive sleep apnoea. *J Clin Sleep Med*, 9 (11), 1161-1164.
- [27] Zimmerman J, Lee J, Pliska B. (2016). Reliability of upper pharyngeal airway assessment using dental CBCT: a systematic review. *Eur J Ortho*, 1-8.
- [28] Martins LS, Liedke GS, Silveria HL, Silveria PF, Arus NA, Ongkosuwita EM, Vizzotto MB. (2018). Airway volume analysis: is there a correlation between two and three dimensions? *Eur J Orthod*, 262-267.