



# Contrastive Characteristic Analysis of Mandibular First Molar Alveolar Bone Between Li Nationality and Han Nationality

Haiou Zhang<sup>1</sup>, Si Yu Tao<sup>2,3</sup>, Wan Yun Lin<sup>2,3</sup>, Xiang Guo<sup>2,3</sup>, Hong Yuan Tian<sup>2</sup>, Jia Jia Tan<sup>4</sup>, Diwas Sunchuri<sup>5</sup>, Zhu Ling Guo<sup>2,3,\*</sup>

<sup>1</sup>The 928<sup>th</sup> Hospital of People's Liberation Army Joint Logistic Support Force, Haikou, PR China

<sup>2</sup>School of Dentistry, Hainan Medical University, Haikou, PR China

<sup>3</sup>Department of Dentistry, the First Affiliated Hospital of Hainan Medical University, Haikou, PR China

<sup>4</sup>College of Veterinary Medicine, Southwestern University, Chongqing, PR China

<sup>5</sup>School of International Education, Hainan Medical University, Haikou, PR China

## Email address:

604569033@qq.com (Zhu Ling Guo)

\*Corresponding author

## To cite this article:

Haiou Zhang, Si Yu Tao, Wan Yun Lin, Xiang Guo, Hong Yuan Tian, Jia Jia Tan, Diwas Sunchuri, Zhu Ling Guo. Contrastive Characteristic Analysis of Mandibular First Molar Alveolar Bone Between Li Nationality and Han Nationality. *International Journal of Clinical Oral and Maxillofacial Surgery*. Vol. 7, No. 2, 2021, pp. 36-39. doi: 10.11648/j.ijcoms.20210702.14

**Received:** November 23, 2021; **Accepted:** December 3, 2021; **Published:** December 11, 2021

**Abstract:** Background/purpose: The present study was performed to compare the ethnic features of alveolar bone of Li and Han nationality in Hainan province. Methods: The lower first permanent mandibular molar tooth (L6) from patients with Li nationality and Han nationality were chosen. Cone-beam computed tomography (CBCT) examination technology was used to measure the vertical height of the middle point of the crown of L6 along the long axis of the tooth from the crest of alveolar bone to the inferior alveolar nerve canal (IANC), and the buccolingual width of alveolar ridge in the direction of this site. The vertical height and buccolingual width between Li nationality and Han nationality were compared. Results: The vertical height between the crest of alveolar bone to IANC of L6 in Li nationality was farther than that in Han nationality and the difference was statistically significant. There was no significant difference in the buccolingual width of alveolar ridge. At the same time, the comparison of the same gender group shows that the difference between the two indicators remains unchanged. Conclusion: Ethnicity-related variations exist in terms of the length of alveolar crest to IANC in the mandible. Longer implants could be considered in the restoration of L6 loss in Li nationality.

**Keywords:** Inferior Alveolar Nerve Canal (IANC), Buccolingual Width, Alveolar Ridge, Dental Implant, Li Nationality

## 1. Introduction

The lower first permanent mandibular molar tooth (L6) erupts firstly in the permanent dentition and bears the largest masticatory force in life. Due to the high incidence tooth-missing of L6, the preferred professional repair method is implant restoration especially in recent decades [1]. The presence of adequate bone height and width is vital for long-term stability of implant restorations. In the process of implant restoration, the vertical height between the alveolar ridge to the inferior alveolar nerve canal (IANC) and the

buccolingual width of alveolar ridge are the most important indexes for the selection of implant system and surgical method [2-4].

The changes of masticatory organs largely reflect the changes of human living environment and the development of culture [5]. Li nationality is the earliest indigenous people and the main minority in Hainan Province. Due to the influence of living environment, migration and intermarriage, the genetic characteristics of masticatory organs have unique national characteristics. There is no report on the measurement of masticatory organs related to Li nationality

in China. The purpose of this article is to offer guidance to dental clinicians for oral clinical mandibular surgery and dental implant surgery.

## 2. Materials and Methods

### 2.1. Research Methods

This retrospective study reviewed 198 CBCT scans of patients from the dental clinic of the 928<sup>th</sup> hospital of People's Liberation Army Joint Logistic Support Force from 2010 to 2021 with an age rang from 20 to 40 years old. The exclusion criteria were those patients with abnormal jaw development, those with dentition defect or loss, and those who had obvious periodontal disease. The study participants were divided into Group A and Group B. Group A: Li nationality grandparents, maternal grandparents and parents; Group B: Han nationality grandparents, maternal grandparents and parents. CBCT was used to measure the vertical height between the alveolar ridge to IANC and alveolar buccolingual width of L6 of Li and Han nationality. The IANC was stained and marked on the CBCT, and the middle of the crown of the L6 was also marked.

### 2.2. Statistical Analyses

The data were stored as standard DICOM3.0 CT image data. The data were analyzed by SPSS14.0 software including descriptive system analysis and t-test, the difference was statistically significant ( $P < 0.05$ ).

## 3. Results

The vertical height between the alveolar ridge crest and the upper edge of the IANC along the long axis and alveolar buccolingual width of L6 of Li nationality and Han nationality were compared and recorded under the sagittal plane of CBCT (Figure 1). The mean vertical height between the alveolar ridge crest and the upper edge of the IANC of L6 site was statistically significant in the Li nationality and the Han nationality ( $P < 0.05$ ). The mean vertical height between the alveolar ridge crest and the upper edge of the IANC of L6 of Li nationality was greater than Han nationality. The difference in buccolingual width of this site between two groups was statistically insignificant ( $P > 0.05$ ) (Table 1).

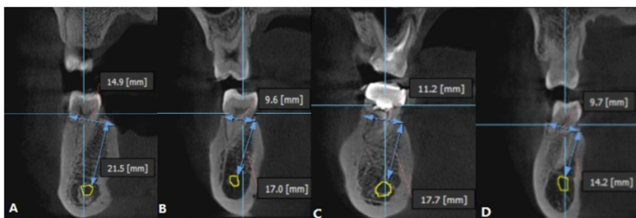


Figure 1. Schematic diagram of cross-sectional CBCT image.

Sagittal section showing the canal crest distance and alveolar ridge buccolingual width in different genders of Li nationality and Han nationality. (A) Li nationality male. (B) Li nationality female. (C) Han nationality male. (D) Han nationality female.

In the same gender, the average of vertical height between alveolar ridge crest and the upper edge of the IANC at L6 site in the Li nationality was also greater than that in the Han nationality, and the difference was statistically significant ( $P < 0.05$ ). There was no statistical difference in alveolar ridge width at L6 site between Li nationality and Han nationality in the same gender ( $P > 0.05$ ) (Figure 2).

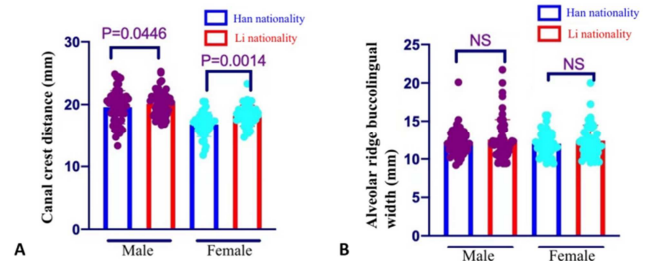


Figure 2. (A) Comparison of different gender of canal crest between Li nationality and Han Nationality. (B) Comparison of different gender of alveolar ridge buccolingual width between Li nationality and Han Nationality. Blue line denotes the Han nationality; and red one denotes the Li nationality

Table 1. Comparison of canal crest distance and alveolar ridge buccolingual width at L6 sites between Li and Han nationality.

	n	Canal crest distance	Alveolar ridge buccolingual width
Li nationality	99	19.14±2.64	12.47±2.42
Han nationality	99	18.37±2.14	12.14±1.66
T-value		2.46	1.07
P-value		0.02*	0.29

\*  $P < 0.05$ .

## 4. Discussion

Li nationality is one of the ethnic minorities with more than one million people in China. More than 90% of them live in Hainan Island and are the aborigines of Hainan Island, except for a few distributed in Guizhou and other provinces [6]. Because of the barrier in Qiongzhou Strait, the speed of social progress is obviously lower than mainland, and the eating habits of Li nationality are quite different from Han nationality. The diet of Li nationality is less refined than that of Han nationality. We speculate that Li nationality's mandible had its own characteristics in measurable and non-measurable traits before Qin Shihuang immigrated to Hainan Island in 221 BC.

Jaw bone is the most complex and exquisite part of human craniofacial bones [7]. It is helpful to understand human physique, physiological state, living environment and culture at that time by studying the jaw bone [8]. The longitudinal researchers mainly focuses on the unearthed bones. However, the maxillary is more osteoporotic, and there are few intact specimens after excavation. Therefore, the study of the jaw mainly focuses on the mandible. The study of craniofacial bone morphology is divided into linear measurement and nonlinear measurement [9]. Non-measurable traits often refer to some subtle bone morphological variations, including pores, tubes and grooves through blood vessels and nerves,

reflecting the direction and branching style of blood vessels and nerves. Non-measurable traits are less affected by natural environment, social and economic conditions, and are mainly controlled by genetics. The frequency of variation has different distribution in various human groups or regions in the world, so non-measurable traits always play a leading role in anthropological research [10, 11].

The inferior alveolar nerve (IAN) enters the mandible from the lingual (medial side of the ramus of the mandible) and passes through the IANC before exiting the mental foramen. These IAN branches form the network of nerve fibers known as the inferior dental plexus that supplies the teeth with sensory innervation [12]. Pre-operative evaluation of the location and proximity to the inferior alveolar nerve canal (IANC) is essential for placing dental implants and extraction of impacted third molars to avoid nerve paraesthesia and other potential complications [13]. If we know the average vertical height between the alveolar crest and IANC, then the available implant length can be estimated by physically measuring the entire length of the mandible in that area [14]. Besides, an insufficient ridge width prevents the placement of implants in a prosthetically desirable position.

With 3D scans, clinicians can precisely diagnose and formulate a treatment plan involving dental implants. CBCT has been recommended as a necessary imaging method in implant restoration because of its advantages of noninvasive, low radiation and accurate measurement [15]. Therefore, CBCT is often used to measure the vertical height between the alveolar ridge to the IANC and the width of the alveolar ridge. In this study, oral CBCT is used to measure and analyze the vertical height between the alveolar ridge to IANC and the buccolingual width of alveolar ridge at L6 site of Li and Han nationality.

A total of 198 CBCT images were compared. Among the two indicators investigated in this study, the vertical height between the alveolar ridge crest and the upper edge of the IANC between the two nationalities is different. However, there is no difference in the buccolingual width of alveolar ridge between Li and Han. In the comparison of the average canal crest distance of different ethnic groups in the same gender group, the results still showed that the average canal crest distance of Li ethnic group was larger than that of Han ethnic group in the same gender, but there was no statistical difference in the alveolar crest width between Li nationality and Han nationality. This result may owing to the continuous ethnic integration and the gradual elimination of the differences in eating habits. Therefore, the possible difference between Li nationality and Han nationality has disappeared in the linear measurement index of mandible. The direction and branch of IANC between jaws are largely controlled by genetics, so there are differences between the two nationalities in the index of the distance of alveolar ridge crest to the upper edge of the IANC.

## 5. Conclusion

This retrospective study observed and analyzed canal crest

distance and alveolar ridge buccolingual width of L6 of Li nationality and Han nationality by CBCT. The results showed that the average canal crest distance of Li population was further than that of Han population. However, there was no significant difference in alveolar ridge buccolingual width between Li nationality and Han nationality. Thus, we consider that longer implants could be considered in the restoration of L6 loss in Li nationality. Besides, there was no difference in the choice of implant diameter between Li nationality and Han nationality.

## Conflicts of Interest

The authors declare that they have no competing interests.

## Acknowledgements

Fund: This research was funded by High-level Talents Project of Hainan Natural Science Foundation (821RC687), Research Project of Education Department of Hainan Province (Hnjg2021-60), Course Construction Project of Hainan Medical University (HYJW202117), Educational Scientific Research of Hainan Medical University (HYYB202014), Research Project of Hainan Provincial Humanities Medical Research Base (QRYZH201811 YB).

## References

- [1] Soni R, Priya A, Yadav H, Mishra N and Kumar L. Bone augmentation with sticky bone and platelet-rich fibrin by ridge-split technique and nasal floor engagement for immediate loading of dental implant after extracting impacted canine. *Natl J Maxillofac Surg* 2019; 10: 98-101.
- [2] Ketabi AR, Zelka A, Lauer HC and Hassfeld S. The comparison of roof visibility of the mandibular canal between cone-beam computed tomography scans and panoramic radiograph images as dependent on the cortical bone thickness of the mandible. *Int J Implant Dent* 2021; 7: 39.
- [3] Sghaireen MG, Srivastava KC, Shrivastava D, Ganji KK, Patil SR, Abuonq A, Mousa MA, Dar-Odeh N, Sghaireen GM, Kamal MA, Alam MK. A CBCT Based Three-Dimensional Assessment of Mandibular Posterior Region for Evaluating the Possibility of Bypassing the Inferior Alveolar Nerve While Placing Dental Implants. *Diagnostics (Basel)*. 2020 Jun 14; 10 (6): 406.
- [4] de Elío Oliveros J, Del Canto Díaz A, Del Canto Díaz M, Orea CJ, Del Canto Pingarrón M and Calvo JS. Alveolar Bone Density and Width Affect Primary Implant Stability. *J Oral Implantol* 2020; 46: 389-395.
- [5] Oxilia G, Menghi Sartorio JC, Bortolini E, Zampirolo G, Papini A, Boggioni M, Martini S, Marciani F, Arrighi S, Figus C, Marciani G, Romandini M, Silvestrini S, Pedrosi ME, Mori T, Riga A, Kullmer O, Sarig R, Fiorenza L, Giganti M, Sorrentino R, Belcastro MG, Cecchi JM and Benazzi S. Exploring directional and fluctuating asymmetry in the human palate during growth. *Am J Phys Anthropol* 2021; 175: 847-864.

- [6] Song M, Wang Z, Zhang Y, Zhao C, Lang M, Xie M, Qian X, Wang M and Hou Y. Forensic characteristics and phylogenetic analysis of both Y-STR and Y-SNP in the Li and Han ethnic groups from Hainan Island of China. *Forensic Sci Int Genet* 2019; 39: e14-e20.
- [7] Wen Y, Mingquan Z, Pengyue L, Guohua G, Xiaoning L and Kang L. Craniofacial Reconstruction Method Based on Region Fusion Strategy. *Biomed Res Int* 2020; 2020: 8835179.
- [8] Ridel AF, Demeter F, Liebenberg J, L'Abbé EN, Vandermeulen D and Oettlé AC. Skeletal dimensions as predictors for the shape of the nose in a South African sample: A cone-beam computed tomography (CBCT) study. *Forensic Sci Int* 2018; 289: 18-26.
- [9] Sejrsen B, Lynnerup N and Hejmadi M. An historical skull collection and its use in forensic odontology and anthropology. *J Forensic Odontostomatol* 2005; 23: 40-44.
- [10] Takahashi D, Teramine T, Sakaguchi S and Setoguchi H. Relative contributions of neutral and non-neutral processes to clinal variation in calyx lobe length in the series *Sakawanum* (Asarum: Aristolochiaceae). *Ann Bot* 2018; 121: 37-46.
- [11] Butterfield BJ, Holmgren CA, Anderson RS and Betancourt JL. Life history traits predict colonization and extinction lags of desert plant species since the Last Glacial Maximum. *Ecology* 2019; 100: e02817.
- [12] Jepsen S, Schwarz F, Cordaro L, Derks J, Hämmerle CHF, Heitz-Mayfield LJ, Hernández-Alfaro F, Meijer HJA, Naenni N, Ortiz-Vigón A, Pjetursson B, Raghoobar GM, Renvert S, Rocchietta I, Roccuzzo M, Sanz-Sánchez I, Simion M, Tomasi C, Trombelli L, Urban I. Regeneration of alveolar ridge defects. Consensus report of group 4 of the 15<sup>th</sup> European Workshop on Periodontology on Bone Regeneration. *J Clin Periodontol*. 2019 Jun; 46 Suppl 21: 277-286.
- [13] Tadinada A, Schneider S, Yadav S. Evaluation of the diagnostic efficacy of two cone beam computed tomography protocols in reliably detecting the location of the inferior alveolar nerve canal. *Dentomaxillofac Radiol*. 2017 Jul; 46 (5): 20160389.
- [14] Kumar SR, Patil PG, Choy CS, Veerakumarasivam A. The location of the inferior alveolar nerve in the Malaysian population: Implications for dental implant planning. *Indian J Dent Res*. 2020 Mar-Apr; 31 (2): 197-202.
- [15] Huang Z, Chen LL, Wang CY, et al. Three-year follow-up results for non-surgical root canal therapy of idiopathic external root resorption on a maxillary canine with MTA: a case report. *Int J Clin Exp Pathol*. 2014; 7 (6): 3338-3346.