

Case Report

A Case of Recurrent Spontaneous CSF Rhinorrhoea with Meningoencephalitis

Shweta Pandey, Rajarshi Chakraborty*

Department of Neurology, King George Medical University, Lucknow, India

Email address:

shwetapandey@kgmcindia.edu (S. Pandey), satyalung@gmail.com (R. Chakraborty)

*Corresponding author

To cite this article:Shweta Pandey, Rajarshi Chakraborty. A Case of Recurrent Spontaneous CSF Rhinorrhoea with Meningoencephalitis. *Clinical Neurology and Neuroscience*. Vol. 5, No. 4, 2021, pp. 124-128. doi: 10.11648/j.cnn.20210504.18**Received:** November 18, 2021; **Accepted:** December 6 2021; **Published:** December 24, 2021

Abstract: Cerebrospinal fluid (CSF) rhinorrhoea is the leakage of CSF from the subarachnoid space into the nasal cavity. A cerebrospinal fluid leak from intracranial cavity to nasal respiratory tract has the potential to produce fulminant meningitis because of the risk of an ascending infection. Recurrent spontaneous CSF rhinorrhoea is definitely a life-threatening entity that can be preventable with timely intervention. This case report describes the clinical course of a 51 year old obese female with recurrent episodes of spontaneous CSF rhinorrhoea presenting with high grade fever, vomiting, headache and new-onset seizure. She was evaluated for meningoencephalitis and CSF culture revealed growth of *Staphylococcus arlettae*. Patient improved with ceftriaxone, vancomycin and levetiracetam and was advised for early surgical repair. A longer duration of nasal discharge of CSF has greater risk of morbidity/mortality due to ascending CNS infection. The episodes of spontaneous CNS rhinorrhoea can pass by unnoticed and can also be missed for rhinosinusitis. A high suspicion of diagnosis can lead to early detection of this condition and better outcome. Treatment decisions should be dictated by the severity of neurological decline during the emergency period and the presence/absence of associated intracranial lesions. The emphasis for timely surgical repair should be advocated for better outcome.

Keywords: CSF Rhinorrhea, Meningoencephalitis, *Staphylococcus Arlettae*

1. Introduction

Cerebrospinal fluid (CSF) rhinorrhoea or liquorrhoea is the leakage of CSF present within the meningeal subarachnoid space into nasopharynx and nasal cavity. CSF rhinorrhoea can be congenital or it can be acquired via trauma (iatrogenic or non-iatrogenic), neoplasm, or spontaneously. Spontaneous fistula can be further subdivided basically into primary cases, where there is no determinable underlying cause, and secondarily due to intracranial pathology (normal or high intracranial pressure). High pressure leaks include tumours (extracranial or intracranial tumors, cholesteatoma, or tuberculoma that can cause bony erosions directly), benign intracranial hypertension and hydrocephalus. [1] Normal pressure leaks can be due to brain tumours, congenital defects, infection, arachnoid granulations, meningoencephaloceles and at times it is idiopathic. It is found that 80-90% of CSF

leaks are traumatic, 10% postoperative and only 3-4% of leaks are spontaneous. [2, 3] A cerebrospinal fluid leak from intracranial cavity into nasopharynx has the potential to produce fulminant meningitis because of the risk of ascending infections. CSF fistulae persisting for > 7 days are seen to have a significantly increased risk of developing meningitis. [4, 5] Patients with spontaneous CSF leaks are generally mid-aged obese women (67%) of 4th decade of life with skull base defects with empty sellar space [6, 7]. The diagnosis of CSF rhinorrhea is made by clinico-laboratorial examination with radiological confirmation. Detection of b-2-transferrin in nasal discharge is diagnostic of CSF. The gold standard for diagnosis of CSF rhinorrhea is CT cisternography which detects the leaks. Treatment decisions should be dictated by the severity of neurological decline during the emergency

period and the presence/absence of associated intracranial lesions. CSF rhinorrhoea causes a potential risk of ascending infection, which mandates early surgical repair and aggressive management. The timing for surgery and CSF drainage procedures is very crucial and it must be decided with utmost care and with a clear strategy. Reparative surgery should be done in every cases of spontaneous leaks, recurrent leaks, leaks that do not stop after conservative management and cases with previous history of meningitis. In this report we present the case of 51 year old obese lady with recurrent spontaneous CSF rhinorrhea with first time meningoencephalitis having first-time seizure. The CNS infection was caused by *Staphylococcus arlettae* which gained access due to defect in the cribriform plate.

2. Case Description

This 51 year old lady presented with severe headache, vomiting, fever and neck pain for 3 days along with nasal discharge for last 7 days. The headache was holocranial with severe intensity, lasting for 8 hours, relieved with medication gradually over 7 days, not associated with nausea, photophobia/phonophobia/aura. Vomiting was intermittent, more in morning and during episodes of headache of nonprojectile nature without passage of blood. She had high grade fever of intermittent nature with chill and rigor, which was relieved over 4-5 days with medication. She also complained of passage of watery discharge from the right side of her nose for last 7 days prior to headache and it was associated with postural variability. She had 2 episodes of generalized seizures with spontaneous recovery during 8th day of her hospital stay. There was no history of diplopia, blurring of vision, weakness, paresthesia, bowel/bladder abnormality, memory loss, behavioural abnormality, joint pain, photosensitivity, rash, redness of eye, ear discharge. She gives no history suggestive of hypertension, diabetes mellitus, trauma, cardiac disease, thyroid dysfunction. However, she had 3 episodes of passage of similar nasal discharge from her right nostril in the last 8 months which resolved spontaneously within 4 to 5 days. She also gives history of bilateral tonsillectomy at 8 years of age due to recurrent tonsillitis. There is no significant drug history and there is no history of any high risk behavior. Her menstrual history was uneventful and she has attained menopause 8 years back. On general examination, her pulse was 118/min, regular, normal volume and character with no delays, blood pressure was 130/72 mm Hg, respiratory rate was 14/m regular, temperature of 100 degree F, no rash, lymphadenopathy, pallor, cyanosis, icterus, clubbing, oedema without any tenderness over para-nasal sinuses with a BMI of 32. Her nervous system examination showed normal higher function with GCS of 15, MMSE 30, normal speech and language, normal memory, normal cranial nerve functions including fundus, normal motor, sensory and cerebellar functions, with presence of neck rigidity without Kernig and Brudzinski sign and her peripheral nerves were not palpable. Her blood investigations showed hemoglobin of 10

g/dL, initial WBC count of 17500 cell/mm³ (9800 cells/mm³ at discharge) with predominant neutrophilia 87%, platelet count 1.81 lac cells/mm³, sugar 97 mg/dL, lactate 1.3 mmol/L, chloride 98 mmol/L, creatinine 1.01 mg/dL, urea 36.65 mg/dL, bilirubin 0.61 mg/dL, Aspartate Transaminase 11.12 IU/L, Alanine Transaminase 18.12 IU/L, Alkaline phosphatase 342.44, random blood glucose of 173.6 mg/dL, sodium 135.8 mmol/L, ionic calcium of 4.13 mg/dL, potassium of 2.45 mmol/L, magnesium of 2.07mg/dL, 25-OH- vitamin D3 2.5 ng/ml (20-40), HbsAg non reactive, HCV non reactive, HIV I and II non reactive. Her cerebrospinal fluid examination revealed 150 cells, 10% neutrophil and 90% lymphocytes, protein 184.3mg%, sugar 48.2 mg % (corresponding sugar 161.3 mg%), which was repeated after 14 days of antibiotics to find 10 cells, all lymphocytes, protein 80.9 mg%, sugar 55.7 mg%. CSF Gram stain negative, AFB stain was negative, CBNAAT was not detected, KOH mount and Cryptococcal antigen negative. The culture sensitivity of CSF detected *Staphylococcus arlettae* sensitive to levofloxacin, ciprofloxacin, clindamycin, amikacin, gentamycin, cefoxitin and resistant to penicillin and intermediate sensitivity to erythromycin. Her CT Cisternography detected extravasation of contrast in sphenoid and ethmoidal sinuses of right side of nose along with mild deviation of nasal septum and mild mucosal thickening in ethmoid air cells [figure 1: a, b]. Her MRI brain revealed focal CSF loculations with enhancing septations showing restriction in DWI over bilateral high frontal regions of brain with thick pachymeningeal enhancement, ventriculitis with collection in occipital horns of bilateral lateral ventricles and partially empty sellar space [figure 2: i (a, b, c, d, e), ii ((a, b, c, d, e), iii, iv]. The patient was treated with ceftriaxone, vancomycin, levetiracetam, calcium, potassium and vitamin D supplementation, naproxen during hospitalization and planned for surgical repair after full course of antibiotics for meningoencephalitis. She was advised for gradual weight reduction in view of her obesity.

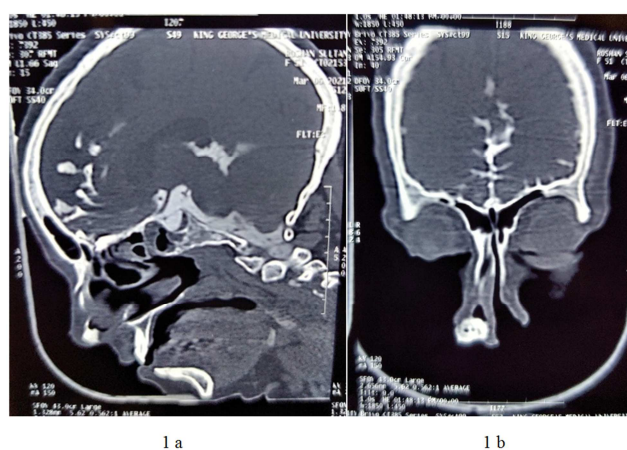


Figure 1. CT CISTERNOGRAPHY.

1: a sagittal view (break in cribriform plate with CSF leak into right nostril)
1: b coronal view (streak of dye and its soakage into cotton placed in right nostril)

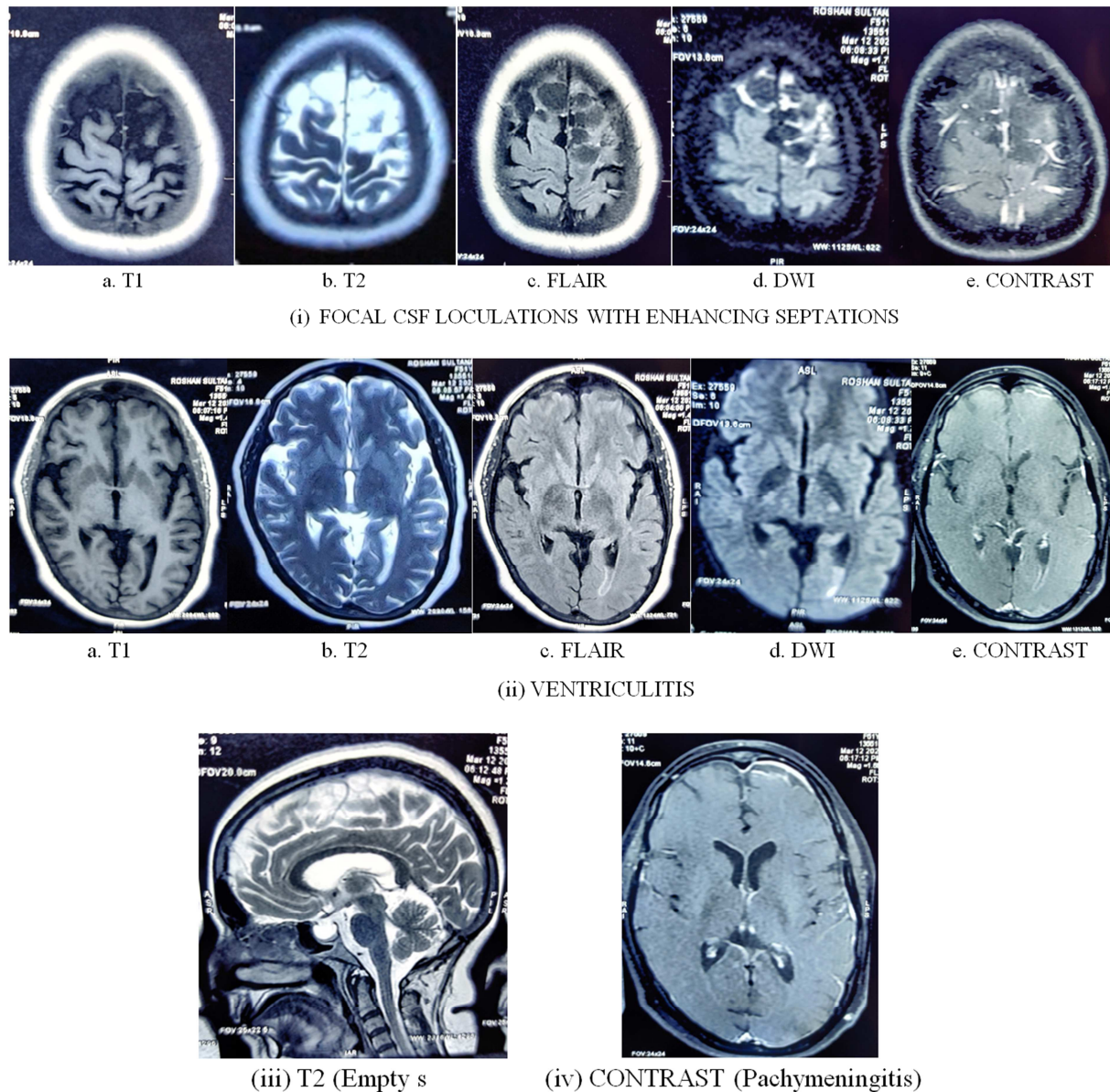


Figure 2. MRI BRAIN.

3. Discussion

This case report describes the clinical course of a 51 year old obese female with recurrent episodes of spontaneous CSF rhinorrhoea presenting with high grade fever, vomiting, headache and new-onset seizure. The term ‘spontaneous’ CSF rhinorrhea refers to nasal discharge of CSF unrelated to surgery, trauma, tumour, malformation, tumour or previous radiation therapy. [8-11] Spontaneous CSF rhinorrhea was reported as pathologic clinical entity by Thomsen in 1899 which was previously been considered to be a physiologic phenomenon by Galen since 200 B.C [12, 13]. Spontaneous CSF leaks are related to benign intracranial hypertension or pseudotumor cerebri. [14, 15] Pulsatile-increased hydrostatic pressure can erode bone over years. [9, 16] For the CSF to communicate outside the meninges, the creation

of ‘osteodural defect’ is the key concept that develops at pneumatized parts of skull leading to communication of subarachnoid space to sinonasal space. These communication sites include cribriform plate, craniopharyngeal canal, sella, and sphenoid-synchondrosis. Arachnoid granulations in proximity to ethmoid and sphenoid sinus are implicated as precursors of osteodural leaks. [9] The cribriform area is very much vulnerable to such leaks because of maldevelopments that can communicate the subarachnoid space to the nose via foramina of the cribriform plate. The dura of anterior cranial base is usually subjected to wide variations in CSF pressure due to normal arterial and respiratory fluctuations and Valsalva like manoeuvres during nose blowing or straining. Elevated ICP results in bone remodeling and thinning due to the pressure exerted ultimately forming the defect that leads to formation of a meningocele or an encephalocele,

depending upon its size. Other non-traumatic causes include focal atrophy, rupture of arachnoid projections that accompany the fibers of olfactory nerve, and persistence of an embryonic olfactory lumen. CSF rhinorrhoea is diagnosed by clinico-biochemical examination with radiological confirmation. Beta-2 transferrin is a carbohydrate-free (desialated) isoform of transferrin, first described by Irjala et al in 1979 and which is exclusively found in CSF. Beta-2 transferrin is not present in blood, nasal mucus, tears or mucosal discharge. Beta-2 transferrin is reported to have a sensitivity of near 100% and specificity of about 95% in a large retrospective study. [17] It provides an easy, accurate, non-invasive method to establish the diagnosis of an active CSF leak but does not provide information on the site of the leak. However, testing nasal secretions for beta-2 transferrin is a specific and sensitive technique with low chances of false positive and false negative. Radionuclide isotope cisternography and CT cisternography have overall sensitivity in 66% of patients in diagnosis, 85% in presence of active leaks. [10, 18] However, present day CT and MR imaging techniques have a much improved sensitivity, 93% for high-resolution CT and for MR cisternography to 89% and 93.6% even in patients with inactive leaks. [18-20] Persistent CSF rhinorrhoea is potentially fatal and may complicate into meningitis in 50% of patients. [21] This entity is often misdiagnosed as rhinosinusitis or upper respiratory infection. Endoscopic endonasal repair of defect is safe and also has a success rate of 85–95%, and it has almost completely replaced the intracranial approach. [2] It is observed in two studies that CSF fistulae persisting for > 7 days had a significantly increased risk of developing meningitis which collaborated with our case. [5, 22] In our report we found growth of *Staphylococcus arlettae*, a Coagulase negative *Staphylococcus* in cerebrospinal fluid that responded with antibiotics, which is a rarely described bacteria in CSF rhinorrhea.

4. Conclusion

Recurrent spontaneous CSF rhinorrhoea is definitely a life-threatening entity that can be preventable with timely intervention. A longer duration of nasal discharge of CSF has greater risk of morbidity/mortality due to ascending CNS infection. The episodes of spontaneous CNS rhinorrhoea can pass by unnoticed and can also be missed for rhinosinusitis. A high suspicion of diagnosis can lead to early detection of this condition and better outcome. The emphasis for surgical repair should be advocated. There is scope for further research into aetiopathogenesis and microbial study of such type of meningoencephalitis in patients suffering from recurrent CSF rhinorrhea in future in this emerging era of infections.

Conflict of Interest

The authors declare that they have no competing interests.

References

- [1] Ozveren MF, Kaplan M, Topsakal C, Bilge T, Erol FS, Celiker H et al. Spontaneous cerebrospinal fluid rhinorrhea associated with chronic renal failure--case report. *Neurol Med Chir* 2001; 41: 313-7.
- [2] Lopatin AS, Kapitanov DN, Potapov AA. Endonasal endoscopic repair of spontaneous cerebrospinal fluid leaks. *Arch Otolaryngol Head Neck Surg* 2003; 129: 859-63.
- [3] Iffenecker C, Benoudiba F, Parker F, Fuerxer F, David P, Tadie M et al. The place of MRI in the study of cerebrospinal fluid fistulas. *J Radiol* 1999; 80: 37-43.
- [4] Abuabara A. Cerebrospinal fluid rhinorrhoea: diagnosis and management. *Med Oral Patol Oral Cir Bucal* 2007; 12: E397-400.
- [5] Brodie HA, Thompson TC. Management of complications from 820 temporal bone fractures. *Am J Otol* 1997; 18: 188-97.
- [6] Berhanu AE, et al. *BMJ Case Rep* 2014. doi: 10.1136/bcr-2014-206133.
- [7] Shah Nishit, Shukla Sunita Chhapola. Spontaneous Recurrent CSF Rhinorrhoea: A Rare Case and Review of Literature. *Indian J Otolaryngol Head Neck Surg* (July–Sept 2017) 69 (3): 420-424.
- [8] Garcia-Urra J, Carrillo R, Serrano P, et al. Empty sella and rhinorrhea. A report of eight treated cases. *J Neurosurg* 1979; 50: 466-71.
- [9] Gacek RR, Gacek MR, Tart R. Adult spontaneous cerebrospinal fluid otorrhea: diagnosis and management. *Am J Otol* 1999; 20: 770-76.
- [10] Stone JA, Castillo M, Neelon B, et al. Evaluation of CSF leaks: high-resolution CT compared with contrast-enhanced CT and radionuclide cisternography. *AJNR Am J Neuroradiol* 1999; 20: 706-12.
- [11] Shetty PG, Shroff MM, Fatterpekar GM, et al. A retrospective analysis of spontaneous sphenoid sinus fistula: MR and CT findings. *AJNR Am J Neuroradiol* 2000; 21: 337-42.
- [12] Ommaya AK, Di Chiro G, Baldwin M, et al. Non-traumatic cerebrospinal fluid rhinorrhea. *J Neurol Neurosurg Psychiatry* 1968; 31: 214-25.
- [13] Obrador S. Primary non-traumatic spontaneous cerebro-spinal fluid rhinorrhea with normal cerebro-spinal fluid pressure. *Schweizer Arch Neurol Neurochir Psychiatr* 1972; 11: 369-76.
- [14] Schlosser RJ, Woodworth BA, Wilensky EM, et al. Spontaneous cerebrospinal fluid leaks: a variant of benign intracranial hypertension. *Ann Otol Rhinol Laryngol* 2006; 115: 495-500.
- [15] Owler BK, Allan R, Parker G, et al. Pseudotumour cerebri, CSF rhinorrhea and the role of venous sinus stenting in treatment. *Br J Neurosurg* 2003; 17: 79-83.
- [16] Carrau RL, Snyderman CH, Kassam A. The management of cerebrospinal fluid leaks in patients at risk for high-pressure hydrocephalus. *Laryngoscope* 2005; 115: 205-12.
- [17] Skedros DG, Cass SP, Hirsch BE, Kelly RH. Sources of error in use of beta-2 transferrin analysis for diagnosing perilymphatic and cerebral spinal fluid leaks. *Otolaryngol Head Neck Surg* 1993; 109: 861-4.

- [18] Chow JM, Goodman D, Mafee MF. Evaluation of CSF rhinorrhea by computerized tomography with metrizamide. *Otolaryngol Head Neck Surg* 1989; 100: 99–105.
- [19] Shetty PG, Shroff MM, Sahani DV, et al. Evaluation of high-resolution CT and MR cisternography in the diagnosis of cerebrospinal fluid fistula. *AJNR Am J Neuroradiol* 1998; 19: 633–39.
- [20] Eberhardt KW, Hollenbach HP, Deimling M, et al. MR cisternography: a new method for the diagnosis of CSF fistulae. *Eur Radiol* 1997; 7: 1485–91.
- [21] Kuo W-M, Lin C-R, Shen K-H. Spontaneous CSF rhinorrhea. *J Med Sci* 2003; 23: 355–8.
- [22] Allan Abuabara. Cerebrospinal fluid rhinorrhoea Cerebrospinal fluid rhinorrhoea: diagnosis and management. *Med Oral Patol Oral Cir Bucal* 2007; 12: E397–400.