

Case Report

Orthostatic Jaw Tremor, a Diagnostic Challenge for Neurologists

Rafaela Magalhães Britto Pacheco de Moraes^{1,*}, Fernando José de Souza¹,
João Felipe Santos Tatsch¹, Livia Souza Santos², José Furtado Alves Junior³,
Maria Sheila Guimarães Rocha¹

¹Department of Neurology, Hospital Santa Marcelina, São Paulo, Brazil

²Department of Neuropsychiatry, Hospital Santa Marcelina, São Paulo, Brazil

³Department of Neurophysiology, Hospital Santa Marcelina, São Paulo, Brazil

Email address:

rafamagtto@gmail.com (R. M. B. P. de Moraes), fernando7sousa@hotmail.com (F. J. de Souza), joaotatsch@gmail.com (J. F. S. Tatsch),
livia91a@gmail.com (L. S. Santos), josefurtadojr@yahoo.com.br (J. F. A. Junior), msrocha@uol.com.br (M. S. G. Rocha)

*Corresponding author

To cite this article:

Rafaela Magalhães Britto Pacheco de Moraes, Fernando José de Souza, João Felipe Santos Tatsch, Livia Souza Santos, José Furtado Alves Junior, Maria Sheila Guimarães Rocha. Orthostatic Jaw Tremor, a Diagnostic Challenge for Neurologists. *Clinical Neurology and Neuroscience*. Vol. 4, No. 3, 2020, pp. 61-65. doi: 10.11648/j.cnn.20200403.14

Received: June 27, 2020; **Accepted:** July 22, 2020; **Published:** August 31, 2020

Abstract: Jaw tremor is usually associated with tremor or other abnormal involuntary movements affecting additional body parts, but isolated jaw tremor is a rare clinical presentation. A 40-year-old man presented with history of paroxysmal jaw tremor for 3 years with no other neurological symptoms, psychiatric conditions, or a family history of neurological disorders. The tremor occurred only in the resting jaw position, with 10 episodes per day on an average, and lasted from 10 minutes to hours. It disappeared with any voluntary activation of the masseter muscle and did not change (in amplitude or frequency) with distraction maneuvers. The remainder of neurologic examination was unremarkable. The patient underwent extensive testing, including contrast-enhanced brain magnetic resonance imaging, blood tests and neuropsychiatric evaluation by two different neuropsychiatrists which failed to reveal the underlying cause. The needle electromyography examination revealed involuntary, intermittent, and synchronized muscular contractions in both masseter muscles, at a frequency of 13 to 14 Hz. No changes were discovered in the other muscles. He was treated with propranolol, primidone, valproic acid, diazepam, and amitriptyline, but the response was not significant. Injection of 25 units of botulinum toxin type A in the masseter muscle on both sides of the face was effective five days after the injection. No adverse effects or masseter weakness were observed.

Keywords: Paroxysmal Isolated Jaw Tremor, Primary Orthostatic Tremor, Botulinum Toxin

1. Introduction

Jaw tremor can be found both in normal individuals and as a component of various neurological disorders. This cranial tremor has classically been associated with Parkinson's disease (PD) [1], but also described in patients with essential tremor (ET), dystonia, branchial myoclonus, hereditary geniospasm, task-specific tremor, and Whipple's disease, as well as in normal situations such as shivering,

and subclinical physiological jaw tremor. In most of these conditions, associated neurological findings may help distinguish these disorders. Jaw tremor is usually associated with tremor or other abnormal involuntary movements affecting additional body parts, although its precise prevalence is unclear. However, isolated jaw tremor is a rare clinical presentation [2-9].

2. Case Report

We described the case of a 40-year-old man with history of jaw tremor for 3 years. The tremor was paroxysmal, lasted from 10 minutes to hours, with 10 episodes per day on an average, and occurred only in the resting jaw position. It never occurred during sleep, and he could make it stop by speaking, clenching his teeth, or any other voluntary jaw movement. The movements were not altered by the consumption of alcoholic beverages and did not affect the voice or swallowing. He reported no other neurological symptoms, psychiatric conditions, or a family history of neurological disorders.

Rapid rhythmic jaw movements were observed on examination (see Figure 1), when the jaw was fully relaxed. The tremor disappeared on voluntary activation of the masseter muscle, such as clenching of the teeth, talking, or opening the mouth. The rapid rhythmic movement reappeared immediately, when the patient returned the jaw to the resting position (see Figure 2).

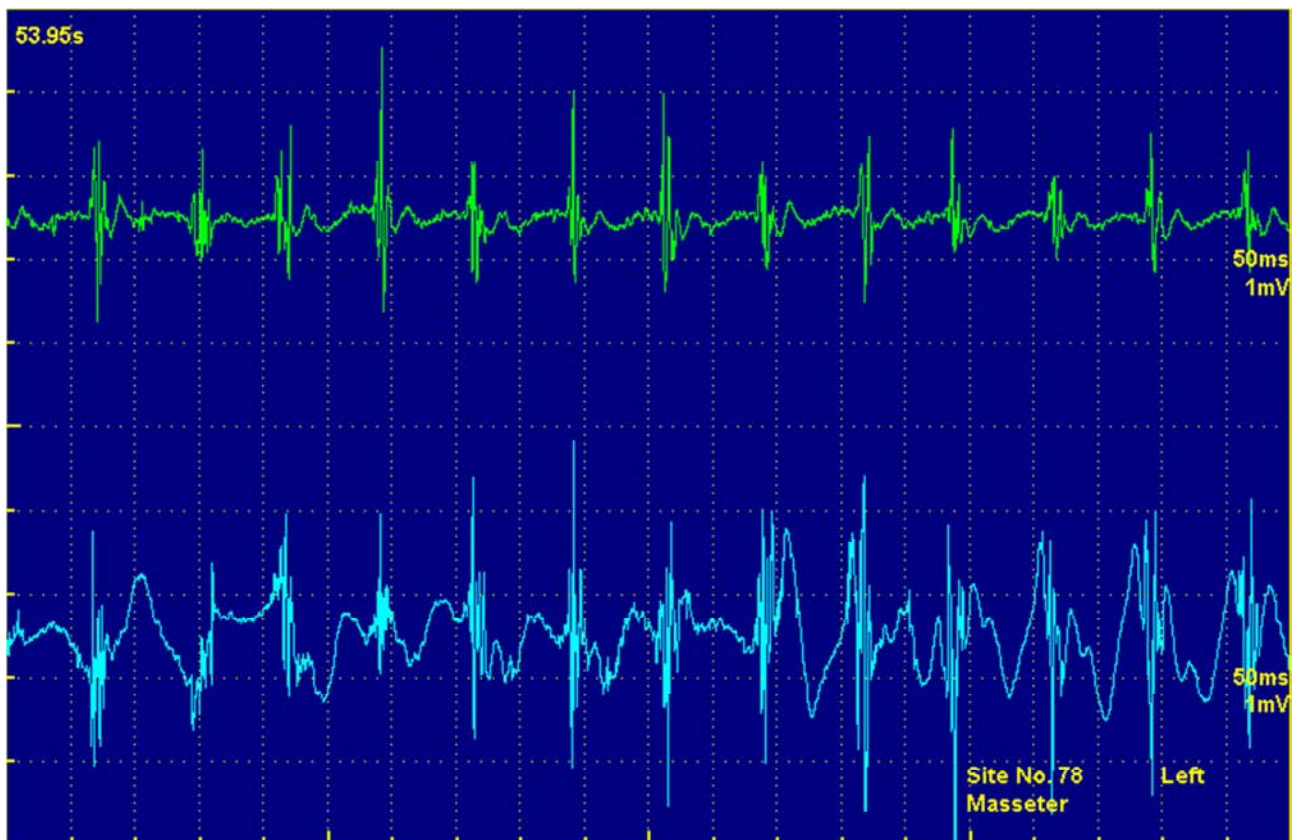
The abnormal movements did not change (in amplitude or frequency) with distraction maneuvers, such as repetitive tapping tasks. The remainder of neurologic examination was unremarkable. No other tremors or involvement of other facial muscles were observed. The patient underwent extensive

testing, which included contrast-enhanced brain magnetic resonance imaging, serum electrolyte evaluation, liver, thyroid and renal function tests, and complete blood count, which failed to reveal the underlying cause.

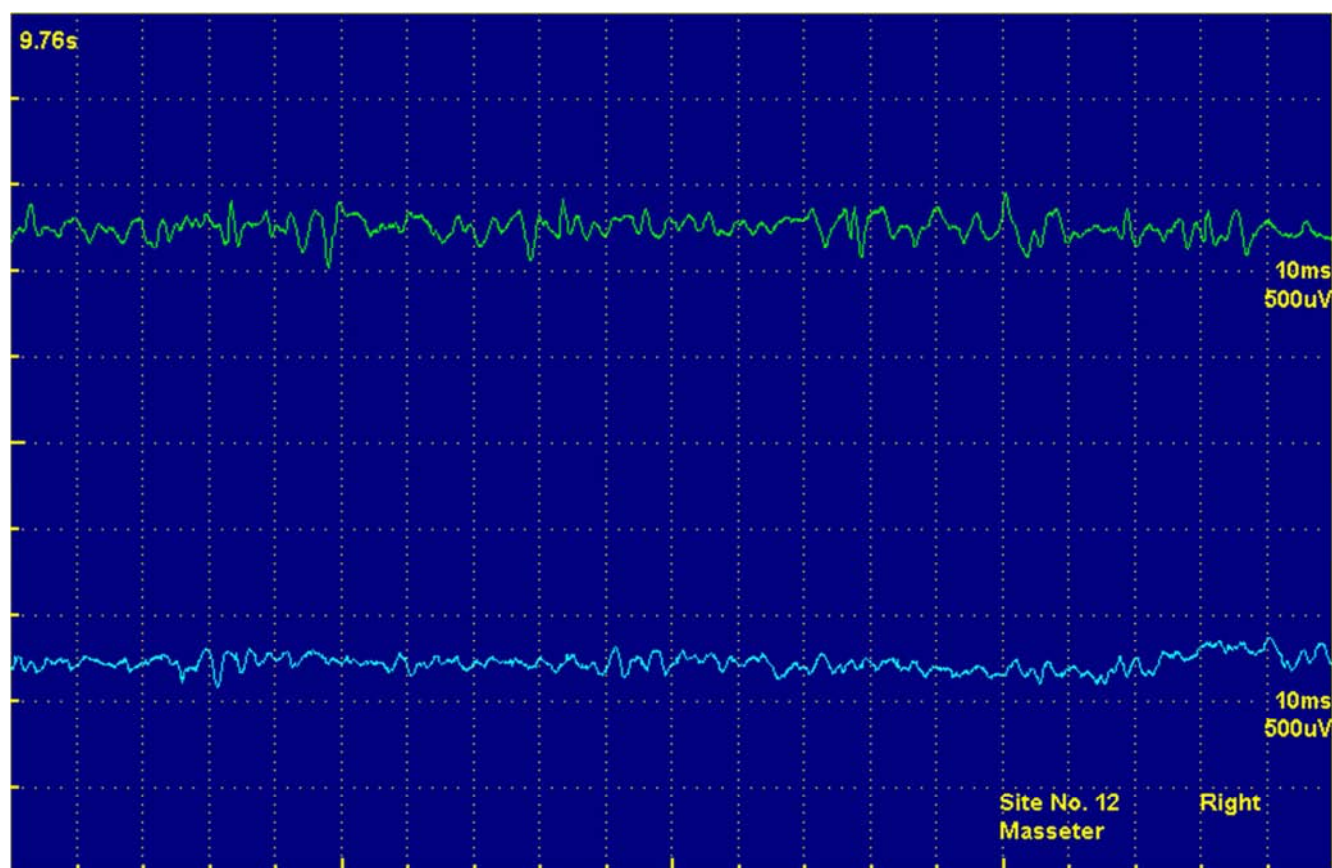
Needle electromyography examination revealed involuntary, intermittent, and synchronized muscular contractions in both masseter muscles. No changes were discovered in the other muscles (cervical region and limbs).

Power spectrum analysis of Electromyography (EMG) using MATLAB [10], which is used for detecting periodicities hidden in the background signals, showed only one peak at around 13 Hertz (Hz) (Figure 3).

We attempted to treat the condition with propranolol, primidone, valproic acid, diazepam, and amitriptyline, but the response was not significant and failed to alter the results of the needle electromyography examination. Based on a previous report of high frequency jaw tremor [1], injection of 25 units of botulinum toxin type A in the masseter muscle on both sides of the fac was eventually effective. The tremor gradually resolved and completely disappeared five days after the injection. The tremor was not detected on electromyography (Figure 1 and Figure 2). No adverse effects or masseter weakness were observed. The tremor progressively returned, and it was necessary to repeat the injections, four months after treatment.



(a)



(b)

Figure 1. Needle electromyography of both masseters, (a): before treatment with botulinum toxin injection, (b): after treatment with botulinum toxin injection.



Figure 2. QR Code - Video of the patient before and after botulinic toxin A injection for both masseter muscles.

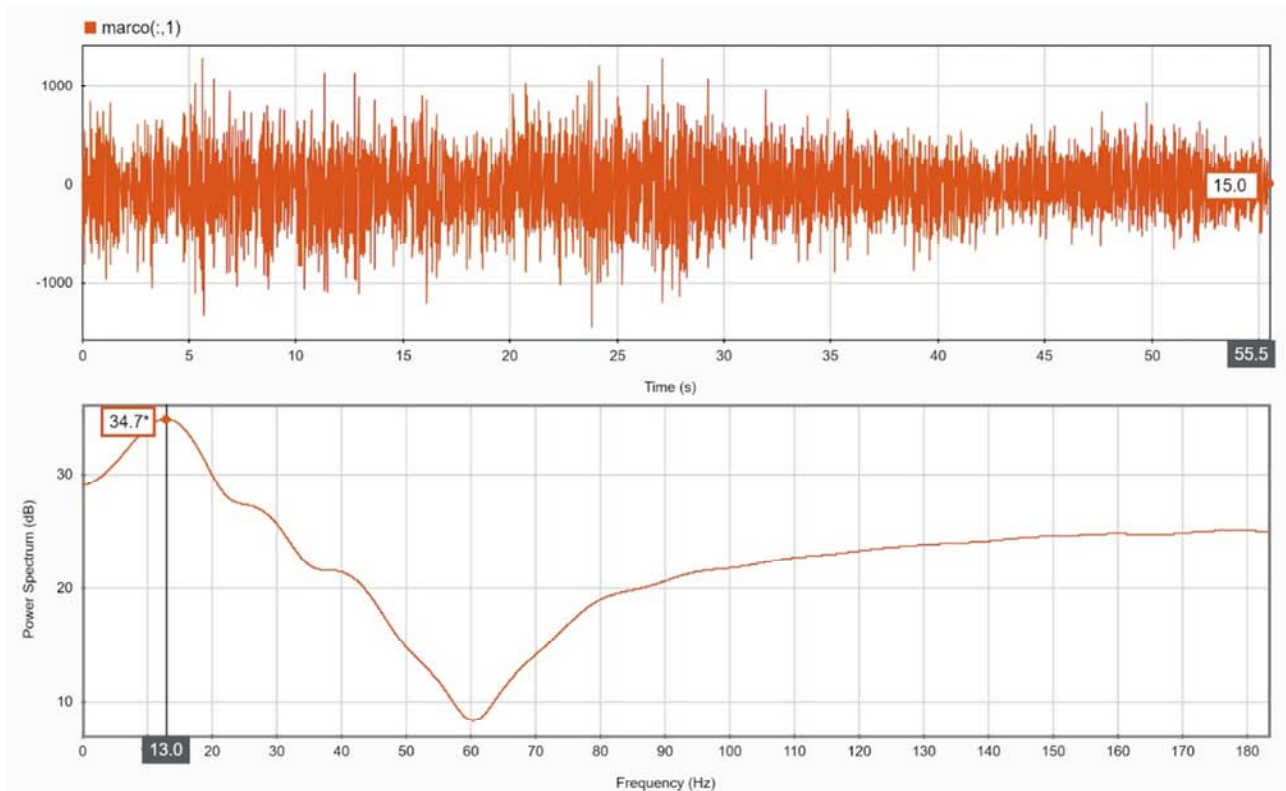


Figure 3. Spectrum analysis of EMG shows only a peak at around 14 Hz.

3. Discussion

Physiological jaw tremor is associated with the resting tone in the jaw and occurs at a frequency around 6-7 Hz, while that of physiological tremor of the limbs is around 8 to 12 Hz [3, 8, 9, 11-13]. The amplitude of this tremor increases during voluntary jaw movements, but the frequency does not change. Most types of pathological jaw tremors have a frequency lower than 12 Hz (see Figure 4), and are commonly associated with abnormal involuntary movements in other body parts, such as Parkinson's disease, physiological jaw tremor, essential tremor, dystonia etc. [1, 3-9].

The distinction of the tremor is based on the activating conditions, clinical characteristics and associated neurologic and systemic signs, some diseases can even have some overlapping clinical features. For instance, jaw tremor in PD manifests typically as a rest tremor (voluntary muscle activity is absent), accompanied by a triad of cardinal motor symptoms such as rigidity, bradykinesia, and tremor. Thus, this abnormal movement seen in our patient did not correspond to a PD.

In ET, the tremor is associated with a postural tremor (when holding a body part against gravity) or kinetic tremor (voluntary movement). In addition, it is more frequently related to older age, increased severity of action tremor in the arms, the presence of head and voice tremor and association between rest tremor in the arms [6].

A functional tremor is characterized by irregularity and distractibility, with variable frequency (from 6 to 11Hz), and

amplitude, as well as co-activation of antagonist muscles at the onset of tremor [13-16]. Suggestion and placebo could also exacerbate or relieve tremor. In relation to the location of the functional tremors, the most common body parts are the right hand, followed by legs, generalized, left arm, and hand [15]. It is described that functional tremors of face are distinctly uncommon [15].

Type of tremor	Frequency range
Parkinson tremor	4 – 6 Hz
Essential tremor	4 – 12 Hz
Orthostatic tremor	13 – 18 Hz
Functional tremor	Inconsistent, incongruent, variable, and never as high as 13Hz
Rubral tremor	Less than 4 Hz

Figure 4. Types of tremor and frequency range.

As the patient had no other neurological findings, a high-frequency tremor (13 Hz) with constant frequency, no co-activation of other muscles, no variation when the patient was ordered to perform tasks or with distraction, as well as no psychiatric comorbidities, the hypothesis of a functional tremor was discarded. Vial et al. [13] also states that “A

functional tremor will never have a frequency as high as 13–18 Hz, thus there is no risk of confusing it with an orthostatic tremor”.

A high-frequency tremor is classically observed in primary orthostatic tremor. It is a rare condition that occurs mainly in the lower limb during postural muscle activity [12]. Since the masseter is an anti-gravity muscle, jaw tremors with similar frequencies have been described in patients with this disease. It occurs while standing and disappears while sitting or walking, it depends on the body posture adopted by the patient [3, 4, 11].

The characteristics of this tremor were similar to those of primary orthostatic tremor, because of the high frequency (13-14 Hz), and the appearance or disappearance particularly, when the patient is in a specific position.

4. Conclusion

There are only two reports of isolated jaw tremor with characteristics similar to those of primary orthostatic tremor at a frequency of more than 13 Hz, leading us to believe that this is a focal variant of primary orthostatic tremor [2-5]. The excellent response of the jaw tremor to botulinum toxin type A treatment is worth reiterating.

References

- [1] M. A Thenganatt, E. D. Louis. Distinguishing essential tremor from Parkinson's Disease: beside tests and laboratory evaluations. *Expert Rev Neurother* 2012; 12 (6): 687–696.
- [2] P. Gonzalez-Alegre, P. Kelkar, T. L Rodnitzky. Isolated high-frequency jaw tremor relieved by botulinum toxin injections. *Mov Disord* 2006; 21: 1049–1050.
- [3] P. F. Sowman, P. D. Thompson, T. S. Miles. Investigation of an unusual, high-frequency jaw tremor with coherence analysis. *Mov Disord* 2008; 23: 441–443.
- [4] Koster B, Lauk M, Timmer J, et al. Involvement of cranial muscles and high intermuscular coherence in orthostatic tremor. *Ann Neurol* 1999; 45: 384–388.
- [5] A. Schrag, K. Bhatia, P. Brownm C. D. Marsden. An unusual jaw tremor with characteristics of primary orthostatic tremor. *Mov Disord* 1999; 14: 528–530.
- [6] E. D. Louis, E. Rios, L. M. Applegate, N. C. Hernandez, H. F Andrews. Jaw tremor: prevalence and clinical correlates in three essential tremor case samples. *Mov Disord* 2006; 21: 1872–1878.
- [7] S. A. Schneider, K. P Bhatia. The entity of jaw tremor and dystonia. *Mov Disord* 2007; 22: 1491–1495.
- [8] Ure RJ, Dhanju S, Lang AE, et al. Unusual tremor syndromes: know in order to recognise. *Journal of Neurology, Neurosurgery & Psychiatry* 2016; 87: 1191–1203.
- [9] D. Junge, J. R Rosenberg, D. M Halliday. Physiological tremor in human jaw-muscle system. *Arch Oral Bio* 1998; 43: 45–54.
- [10] MATLAB. version 9.4.0.813654 (R2018a). Natick, Massachusetts: The MathWorks Inc.; 2018.
- [11] P. F. Sowman, KS. Turker. Methods of time and frequency domain examination of physiological tremor in the human jaw. *Hum Mov Sci* 2005; 24: 657–666.
- [12] K. M. Heilman. Orthostatic tremor. *Arch Neurol* 1984; 41: 880–881.
- [13] S. Jaberzadeh, P. Brodin, S. C Flavel, N. J O'Dwyer, M. A Nordstrom, T. S Miles. Pulsatile control of the human masticatory muscles. *J Physiol* 2003; 547 (Pt. 2): 613–620.
- [14] F. Vial, P. Kassavetis, S. Merchant, D. Haubenberger, M. Hallett. How to do an electrophysiological study of tremor. *Clin Neurophysiol Pract* [Internet]. 2019; 4: 134–42. Available from: <https://doi.org/10.1016/j.cnp.2019.06.002>.
- [15] Hess CW, Pullman SL. Tremor: Clinical Phenomenology and Assessment Techniques. *Tremor and Other Hyperkinetic Movements*. 2012; 2 (0): 02.
- [16] Pal PK. Electrophysiologic Evaluation of Psychogenic Movement Disorders. *J Mov Disord* [Internet]. 2011 Apr 30; 4 (1): 21–32. Available from: <http://e-jmd.org/journal/view.php?doi=10.14802/jmd.11004>.
- [17] D. M. M Mehndiratta, D. M Kumar, D. S Pandey. Tremor Differentiation on Surface Electromyography. *IOSR J Dent Med Sci* [Internet]. 2016 Jul; 15 (07): 23–9. Available from: <http://iosrjournals.org/iosr-jdms/papers/Vol15-Issue 7/Version-12/E1507122329.pdf>.