

# Comparison of Hemodynamic Significant Coronary Stenosis Using Artificial Intelligence and Conventional Cross Sectional Area in CT Coronary Angiography

Atul Kapoor\*, Goldaa Mahajan, Aprajita Kapoor

Department of Radiology, Advanced Diagnostics and Institute of Imaging, Amritsar, India

## Email address:

Masatulak@aim.com (A. Kapoor), Goldaamahajan@gmail.com (G. Mahajan), Aprajitakapur9@gmail.com (A. Kapoor)

\*Corresponding author

## To cite this article:

Atul Kapoor, Goldaa Mahajan, Aprajita Kapoor. Comparison of Hemodynamic Significant Coronary Stenosis Using Artificial Intelligence and Conventional Cross Sectional Area in CT Coronary Angiography. *Cardiology and Cardiovascular Research*.

Vol. 6, No. 1, 2022, pp. 22-31. doi: 10.11648/j.ccr.20220601.14

Received: February 4, 2022; Accepted: February 24, 2022; Published: March 3, 2022

---

**Abstract:** *Objectives:* This study was designed to compare the accuracy of estimation of coronary stenosis in patients with stable coronary artery disease using artificial intelligence based technique and conventional cross sectional area method using hemodynamically significant stenosis based on CTFFR as the gold standard for significant ischemia. *Background:* Although detection of degree of stenosis on coronary angiography as well as Computed tomographic angiography (CTA) forms the backbone of management plan of a patient with suspected coronary artery disease there is a discordance in the results between both the techniques for estimation of stenosis as well as 20-30% interobserver variation in the results in the stenosis estimation based on conventional angiography method. So a more robust method is needed using modern techniques like artificial intelligence to address this problem. *Methods:* CTA's of 100 consecutive patients of stable coronary artery disease were evaluated for coronary stenosis on per vessel and per patient basis using conventional cross section method and using artificial intelligence with hemodynamic significant stenosis using CT FFR < 0.8 as the gold standard for ischemia and the results compared. *Results:* Cross sectional area method revealed significant stenosis > 50% in 184 (61.2%) vessels per vessel basis and in 65% on per patient basis while the AI method showed significant stenosis in all the 232 (77.2%) per vessels and in 89% per patient basis out of which 81% were hemodynamically significant. 18% of cases were not assessable by cross section method due to heavy vessel calcifications. Sensitivity and specificity on per patient basis by cross section method and AI method were 80%, 57% and 98% and 90% respectively with a false negative and positive of 19%, 42% by cross section method and 1.3%, 10% by AI method respectively with overall accuracy of 76% and 97% respectively of the two methods. *Conclusion:* AI method of estimation of coronary stenosis is more accurate and robust than conventional area estimation method in clinical practice especially when patients have higher vessel coronary calcium.

**Keywords:** CT Angiography, Conventional Angiography, CTFFR

---

## 1. Introduction

Rapid advances in Computed tomography have evolved Coronary CT angiography (CTA) into a robust technique for evaluation of coronary vessels. As per NICE 2019 guidelines CTA is the investigation of choice for patients with stable chest pain [1]. The diagnosis and evaluation of patients with suspected stable coronary artery disease may be guided by anatomical or functional evaluation with the latter being preferred by many studies [2, 3]. Traditionally detection of

anatomical stenosis by conventional coronary angiography has been the backbone of the management plan of patients with chest pain. A similar approach was applied for the use of CTA in the evaluation of these patients with suspected coronary artery disease. The common methods used for stenosis calculation were: visual estimation of stenosis, minimal residual luminal diameter and cross sectional area of stenosis. Those with stenotic vessels were then subjected to

stress myocardial perfusion techniques like Thallium 201 imaging to detect ischemia in a that narrowed vessel to decide the reperfusion procedure. With advances in imaging newer techniques use a single test for not only detecting anatomic stenosis but also give hemodynamic evaluation, i.e. coronary flow or myocardial perfusion assessment by combining CTA with CTFFR or CT myocardial perfusion and the estimation of vessel cross section area is currently the preferred method the visual method or the diameter evaluation [4-6]. Although improvements in the CTA technology has shown high sensitivity and specificity in detection of coronary artery disease but issues of discordance in the results of stenosis estimation by CTA still remain due to inherent weaknesses in both CTA and conventional angiography e.g: visual estimation method of stenosis is still the most popular method in clinical practice for stenosis estimation on conventional angiography which has a high interobserver variation and high variation with cross section and luminal diameter estimation method [4]. Differences of  $\pm 20\%$  for intermediate grade (40% to 70%) stenosis have been seen amongst various readers in different studies. [7, 8]. In one study, visual estimates of moderate to severe stenosis were on average 30% greater than actual percentage diameter stenosis [9]. In another study the vessels with stenosis  $> 50\%$  were overestimated by visual reading, whereas  $< 50\%$  stenosis were underestimated [10]. These variations can thus lead to significant biases in making decisions whether or not to proceed with coronary revascularization [11]. Yet conventional angiography continues to be the backbone modality to decide management plan of patients with suspected coronary artery disease. Therefore there is a need to evaluate a robust method of evaluation of stenosis. With the availability of methods using artificial intelligence we designed a study comparing stenosis estimation of coronary arteries in stable coronary artery disease patients on CTA using AI and compared conventional cross sectional area estimation of stenosis and kept hemodynamic evaluation as the gold standard for ischemia to label as significant stenosis using CT FFR.

## 2. Material and Methods

A retrospective study of 100 patients of clinically suspected stable coronary artery disease was done from blinded data of patients of coronary artery disease from the hospital archives after approval from local ethics committee. The demographic parameters of all patients, that is, age, sex, body mass index (BMI) along with history of disease, coexisting morbidities like hypertension, diabetes and hyperlipidemias were recorded.

### 2.1. CTA Protocol

Calcium scoring followed by contrast coronary CT angiography was done on was done on a dual-energy CT 128 scanner (Siemens Go-Top, Forchheim, Germany) using standard protocol. After preparation with oral 50-mg metoprolol 1 hour before the examination and sublingual 0.5

mg nitrate. Scan was done using retrospectively gated ECG triggered spiral (pitch 0.3) CT acquisition with a rotation time of 0.33 ms using tube voltage of 70 KV along with automated tube current modulation using CARE Dose 4D. 35 ml of intravenous iodinated contrast iomeprol 400 (Iomeron Bracco UK Ltd.) of 35 mL was injected using bolus tracking software with dual head injector (MEDRAD, Stellant, Bayers, Munich, Germany) followed by 20mL saline. Image reconstruction using iterative reconstruction (SAFIRE, Siemens healthineers level 3) was done with reconstruction kernel of BV36.

### 2.2. Image Analysis

Was done on a Siemens Syngo via workstation. Post processing involved both multi planar and volume rendering projections. Vessel stenosis was calculated using vessel cross section area method at the site of stenosis and expressed in percentage stenosis by second author (G. M.) [figure 1]. This author was blinded to the results of stenosis calculated using Artificial intelligence method by using CTFFR (version 3.2.5) software on separate workstation. A machine learning algorithm was used in the latter and the results read by first author (A. K.). The technique involved vessel centre line delineation of all major coronary arteries and their branches uptill 1.5mm diameter which are extracted as a coronary tree. This is followed by luminal contouring. Last step involves a machine learning based algorithm to estimate cross sectional area of lumen and marking of site of stenosis [figure 2].

### 2.3. Statistical Analysis

All descriptive analyses was shown as a (percentage) for categorical variables, and as mean  $\pm$  standard deviation for continuous variables. Correlation between these variables was made using Pearson's correlation. The agreement was determined by Bland-Altman analysis. Hemodynamic stenosis was defined as vessels with reduced CTFFR  $\leq 0.8$ . Sensitivity, specificity, positive predictive value (PPV) and negative predictive value (NPV) of both techniques was calculated and the results compared for statistical significant differences with p value  $< 0.05$  being significant.

## 3. Results

100 patients of clinically stable coronary artery disease were evaluated in the study. The clinical demographics are shown in [table 1]. There were 80 males and 20 female patients with mean age of 58.5 years  $\pm$  2.5 years. 89% patients in the study had obstructive coronary artery disease i.e. significant stenosis  $> 50\%$  out of which 81% were hemodynamically significant and showed reduced FFR  $< 0.80$ ) [table 2]. Calcium score was high in our study with a mean of 245  $\pm$  18.5. Cross sectional area method revealed significant stenosis  $> 50\%$  in 184 (61.2%) vessels per vessel basis and in 65% on per patient basis while the AI method

showed significant stenosis in all the 232 (77.2%) per vessels and in 89% per patient basis out of which 81% were hemodynamically significant [table 3] [Figure 3]. There were 18% and 23.6% cases per patient and per vessel wise with high calcifications which were not assessable by cross section method [figures 3-5] and 42% showed false positive with overestimation of stenosis due to blooming of calcium [figures 6, 7]. Sensitivity and specificity on per patient basis was 80% and 57% with a false negative of 19% and false positive of 42% with negative and positive predictive value of 42% and 89% and an accuracy of 76% by cross section area method. AI method showed a 98% sensitivity and 90% specificity with a false negative of 1.3% and a false positive 10% respectively with negative and positive predictive value 94.7% and 97.3% with overall accuracy of 97% [tables 4, 5] [figures 8-10]. Statistical analysis done using Pearson correlation test showed moderate correlation of  $r=0.30$  between two methods while a weak agreement with  $r=-0.29$  was seen by Bland Altman test; the differences being statistically significant  $p=0.002$  [figure 11]. AUC of both methods showed an AUC of 1.0 and 0.78 by AI and cross section methods with threshold stenosis of 50% and CTFRR

$< 0.8$  [figure 12]. When the threshold of hemodynamic significant stenosis was fixed at  $> 70\%$  stenosis the sensitivity of cross section method fell to 52% as 32/81 patients with hemodynamic significant stenosis were not detected by cross section method alone with increase in false negatives of 47.8% from 19%.

**Table 1.** Patient Demographics.

Sno	Parameters	Stable CAD	
		n=100	95%CI
1	Age	52	50.8-53.2
2	SEX		
	Males	80	
	Females	20	
3	BMI	28.2	28-29
4	Hypertension	76	
5	Diabetes	51	
6	Smoking	7	
7	Dyslipidemia	68	
8	Family H/o CAD	55	
9	Sedentry	76	

**Table 2.** Distribution of stenotic lesions by AI, Cross section area methods-PATIENT wise.

Percentage stenosis	AI method	Cross section	FFR $> 0.8$	FFR $< 0.8$
Stenosis $< 50\%$	11 (11%)	17 (17%)	11 (11%)	0 (0%)
Stenosis 50-69%	21 (21%)	30 (30%)	6 (6%)	15 (15%)
Significant stenosis $> 70\%$	68 (68%)	35 (35%)	2 (2%)	66 (66%)
Not assessable	0 (0%)	18 (18%)	X	X

**Table 3.** Distribution of stenotic lesions by AI, Cross section area and visual method-PER VESSEL wise.

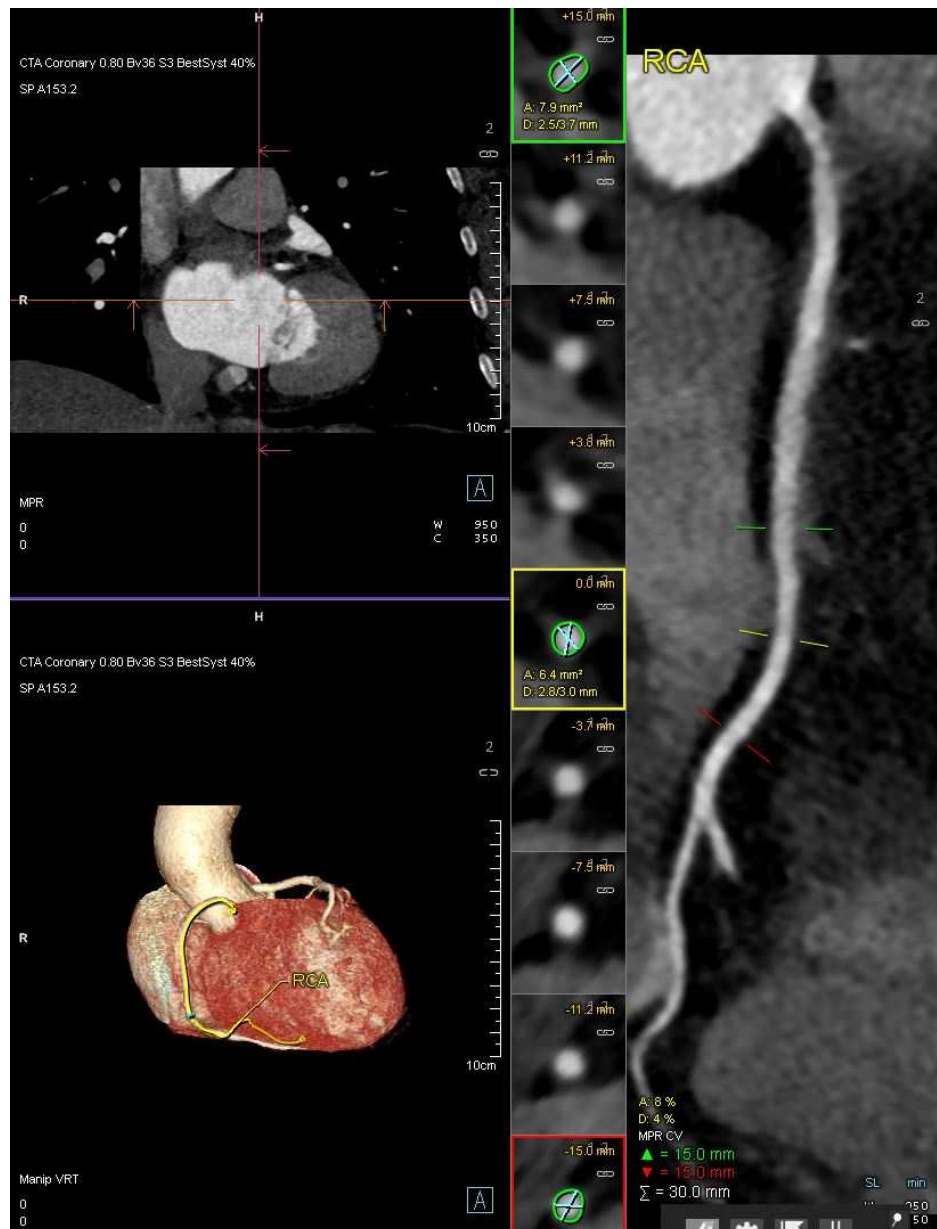
Percentage stenosis	AI method	Cross section
Stenosis $< 50\%$	68 (22.6%)	45 (15%)
Stenosis 50-69%	110 (36.6%)	89 (29.6%)
Significant stenosis $> 70\%$	122 (40.6%)	95 (31.6%)
Not assessable	0 (0%)	71 (23.6%)

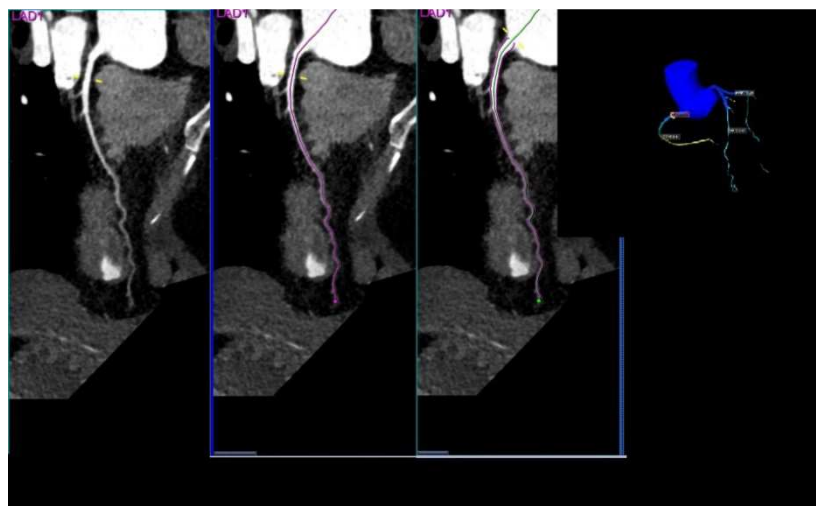
**Table 4.** Sensitivity, Specificity of cross sectional (CS) area method.

CS with FFR $< 0.8$	n		100
	Abnormal+	Normal-	Total
Abnormal +	65	8	73
Normal-	16	11	27
Total	81	19	100
Sample Prevalence	0.810		
	95%CI		
Sensitivity- TP Proportion	0.802	0.699 to 0.883	
Specificity-TN Proportion	0.579	0.335 to 0.797	
FP Proportion	0.421	0.203 to 0.665	
FN proportion	0.198	0.117 to 0.301	
Likelihood ratio (+)	1.91		
Likelihood ratio (-)	0.34		
At sample Prevalence			
Correct Classification	0.760	0.664 to 0.840	
Miss Classification	0.240	0.160 to 0.336	
Positive predictive value	0.890	0.795 to 0.951	
Negative predictive value	0.407	0.224 to 0.612	

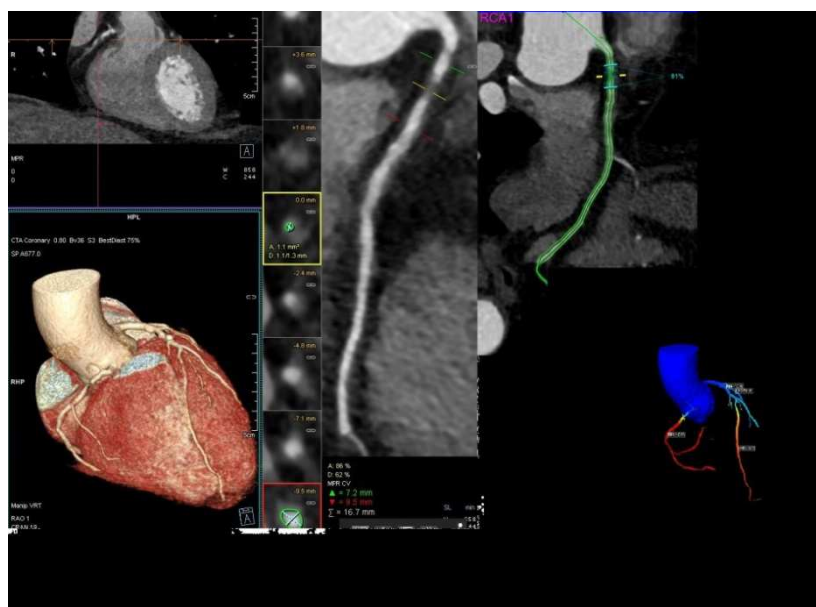*Table 5. Sensitivity, Specificity analysis by AI method with CTFFR < 0.8.*

STENOSIS FFR < 0.8 (n= 100)			
CTA	Abnormal+	Normal-	Total
Abnormal +	79	2	81
Normal-	1	18	19
Total	80	20	100
Sample Prevalence	0.800		
		95%CI	
Sensitivity- TP Proportion	0.988	0.932 to 1.000	
Specificity-TN Proportion	0.900	0.683 to 0.988	
FP proportion	0.100	0.012 to 0.317	
FN proportion	0.013	0.000 to 0.068	
Likelihood ratio (+)	9.88		
Likelihood ratio (-)	0.01		
At sample Prevalence			
Correct Classification	0.970	0.915 to 0.994	
Miss Classification	0.030	0.006 to 0.085	
Positive predictive value	0.975	0.914 to 0.997	
Negative predictive value	0.947	0.740 to 0.999	

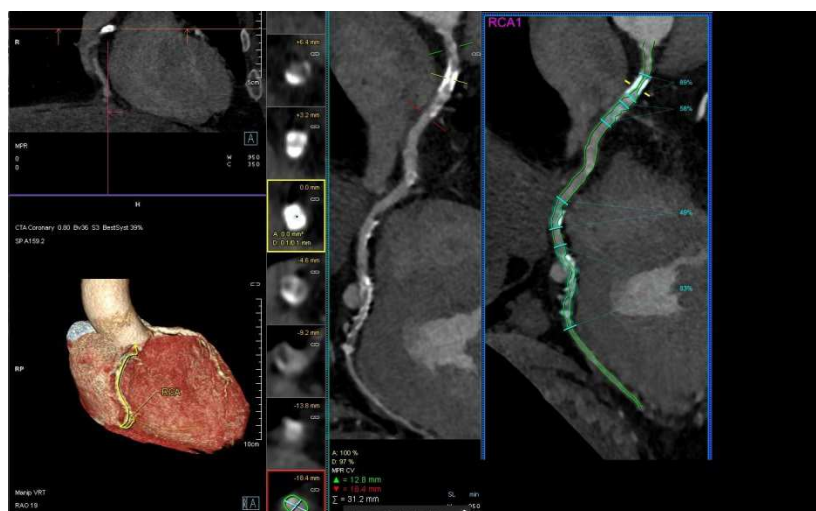
*Figure 1. Estimation of stenosis by cross sectional method.*



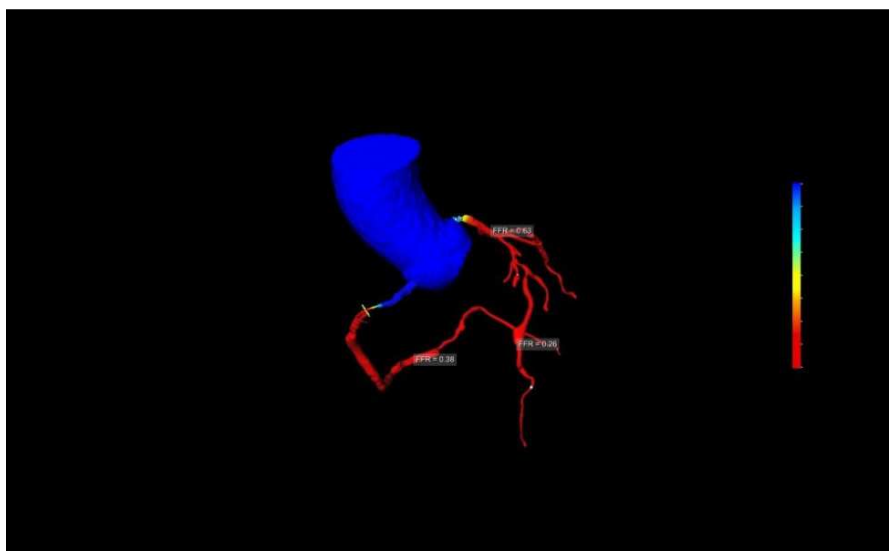
**Figure 2.** Steps of centre line extraction, luminal tracing by AI method with CT FFR.



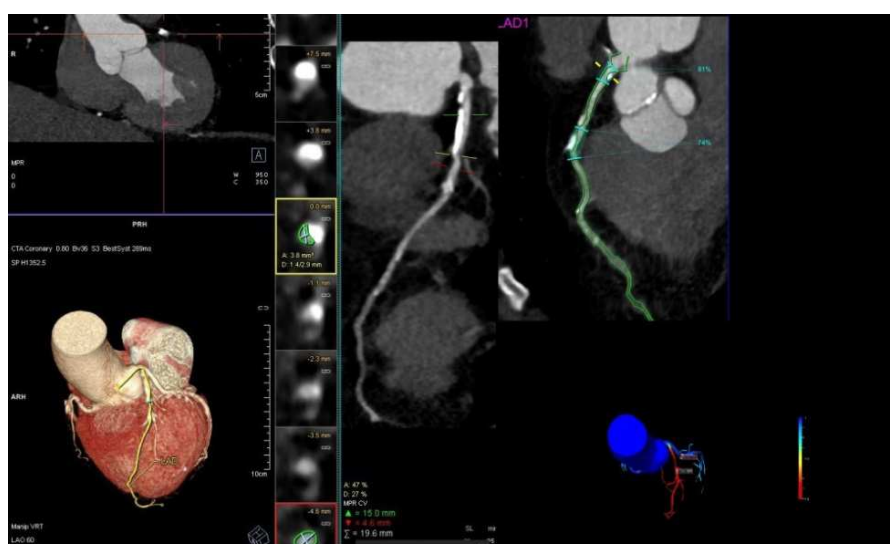**Figure 3.** Showing 88% stenosis by cross section method and concordant 91% stenosis by AI method with reduced CT FFR in left anterior descending artery.



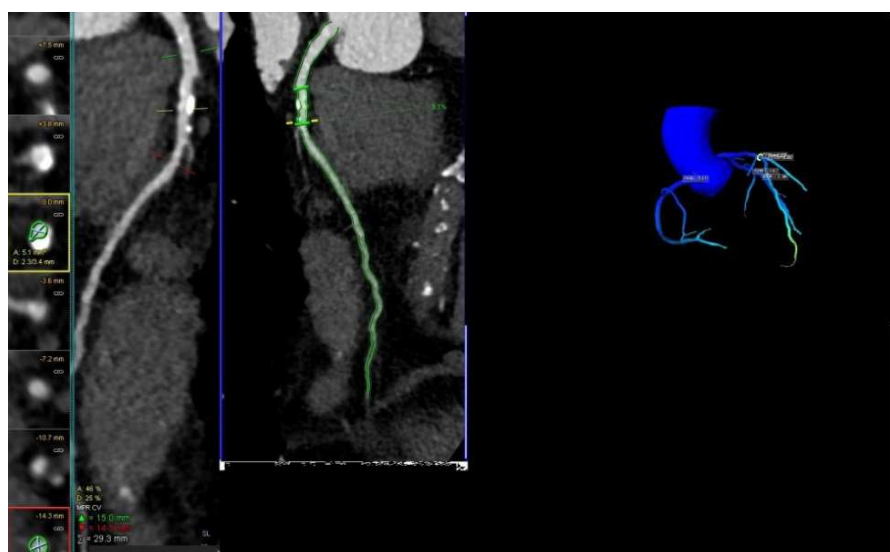
**Figure 4.** Cross sectional method showing 100% stenosis in proximal right coronary artery with calcifications in proximal and distal segments while AI method showing 89% and 83% stenosis in proximal and distal segments.



**Figure 5.** CT FFR in same patient showing reduced FFR.

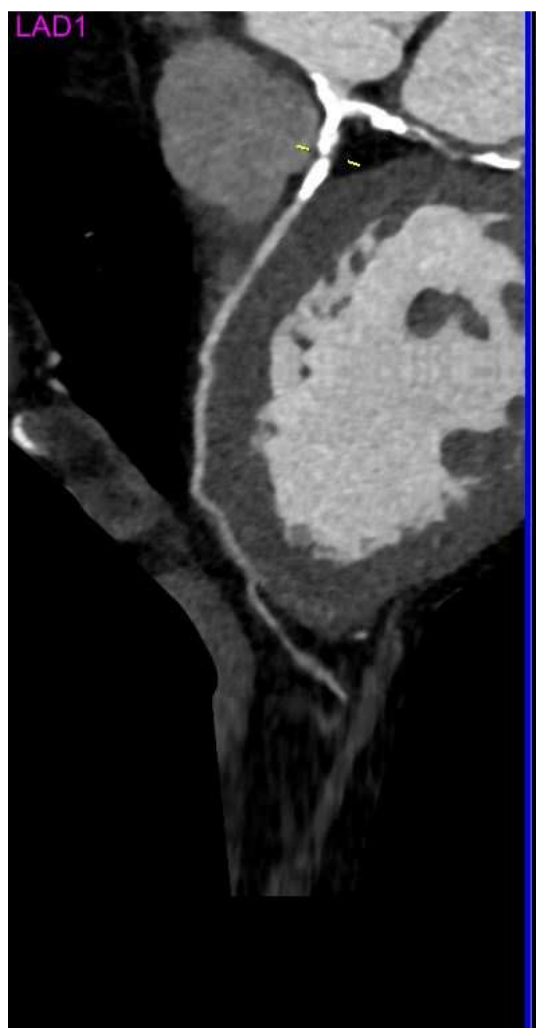


**Figure 6.** Cross sectional method showing 47% stenosis in proximal Lt anterior descending coronary with calcified plaque while AI method showing tandem 81% and 74% stenosis with reduced FFR.

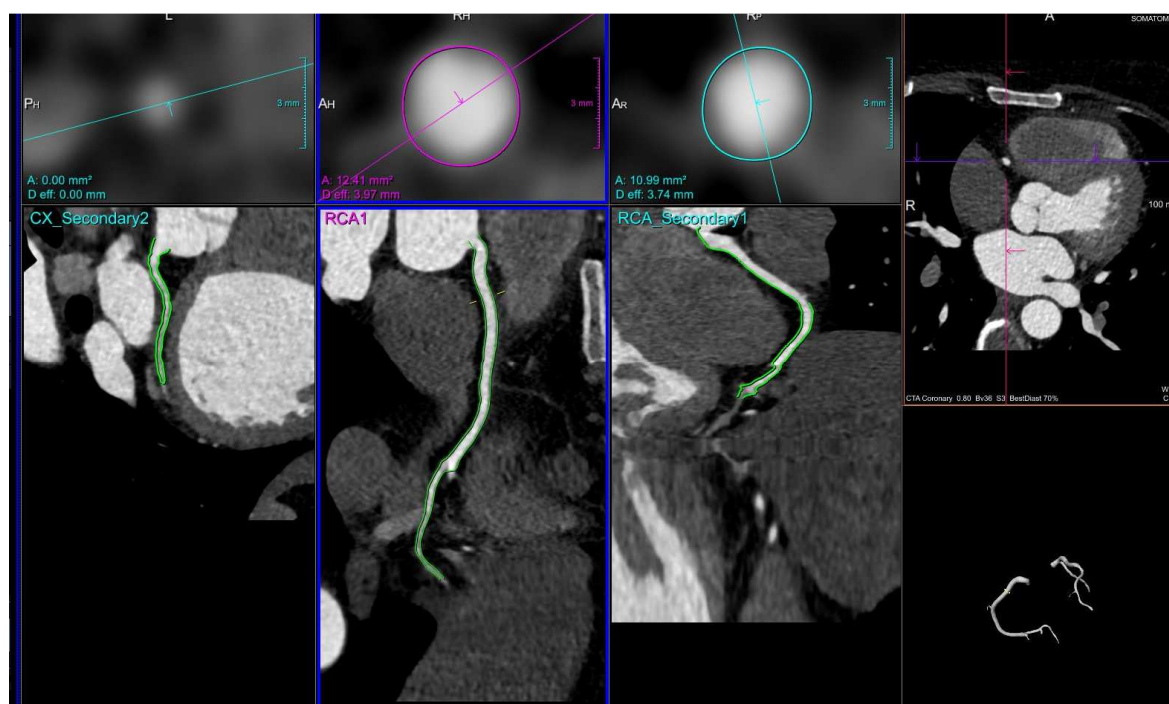


**Figure 7.** Cross sectional method showing mild grade stenosis 47% with calcification while AI method showing no stenosis with normal FFR.

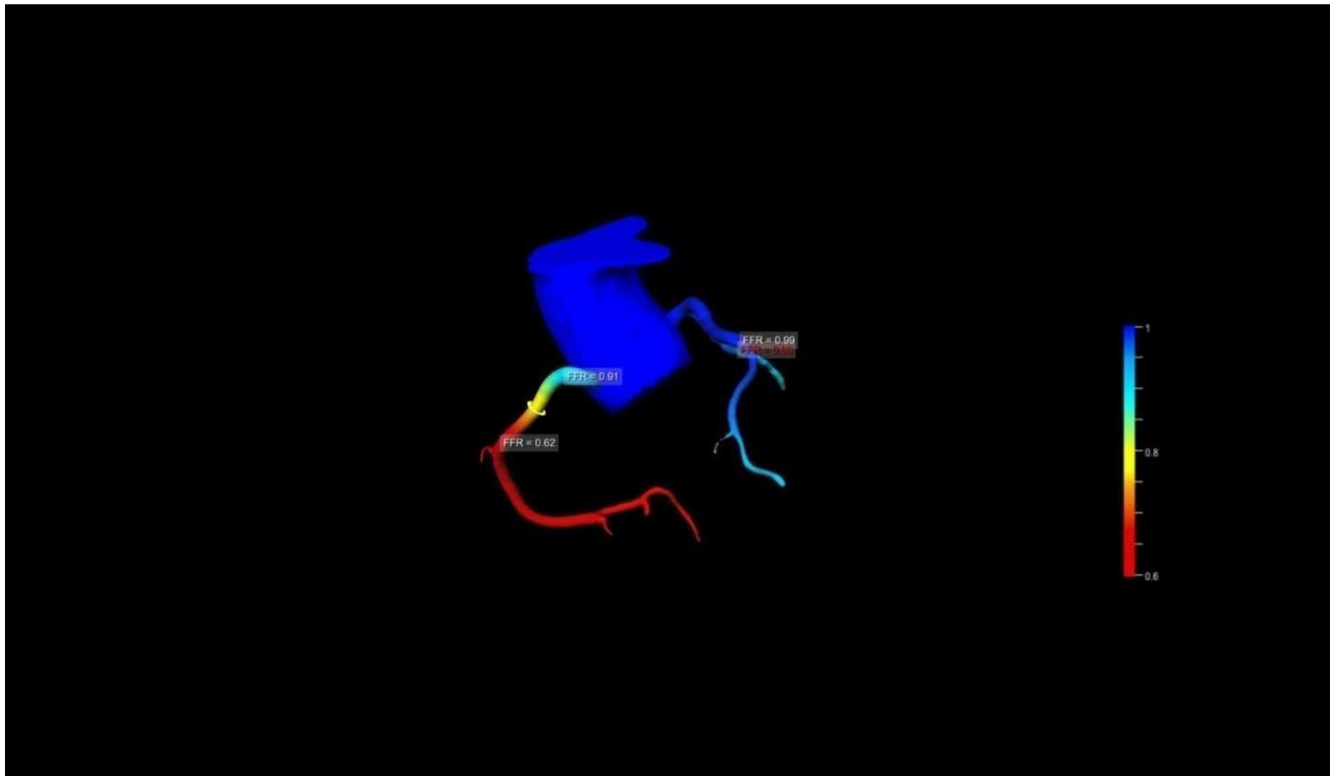




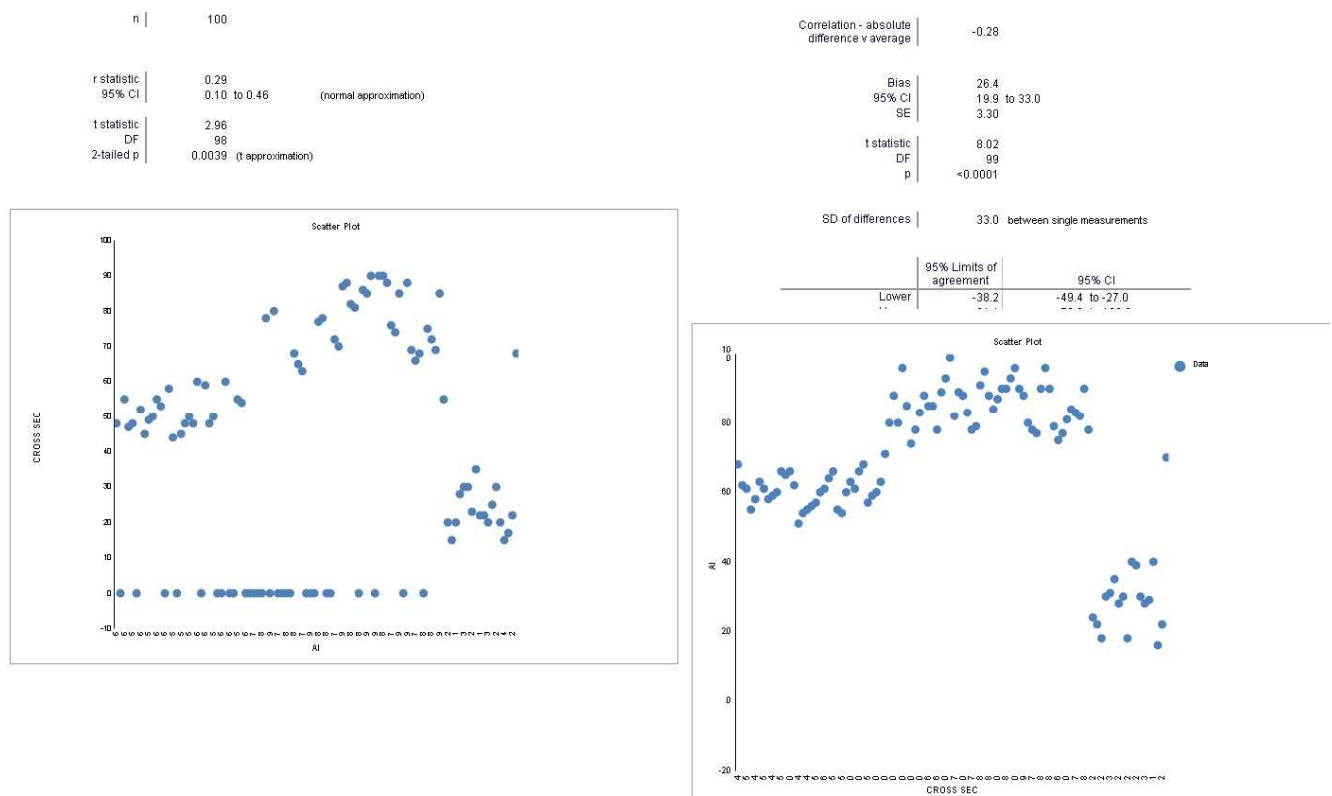
**Figure 8.** CT angiogram showing heavy calcification in left main and proximal left anterior descending artery with non assessable lumen.



**Figure 9.** CT angiogram showing false negative ischemia in a normal caliber right coronary artery in a patient with non obstructive ischemia.



**Figure 10.** CTFFR showing reduced FFR < 0.8 in mid and distal right coronary artery of same patient.



**Figure 11.** Pearson correlation and Bland Altman agreement scatter charts between Cross section and AI methods.



STENOSIS		n
Absent		19
Present		81

Test	Area	95% CI	SE	STENOSIS = Present
AI	1.00	- to -	0.000	have higher values
CROSS	0.78	0.69 to 0.87	0.046	have higher values

Contrast	Difference	95% CI	SE	Z	p
AI v CROSS	0.22	0.13 to 0.31	0.046	4.77	<0.00

$H_0$ : Difference between areas = 0.  $H_1$ : Difference between areas  $\neq$  0.

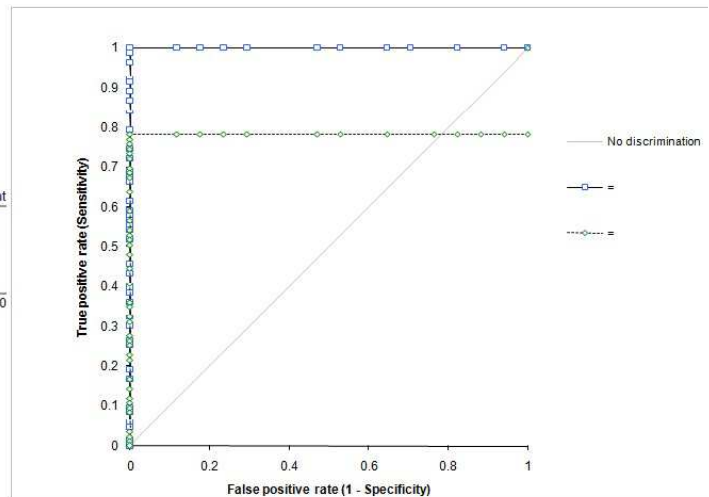


Figure 12. Area under curve plot for AI and cross section methods.

## 4. Discussion

The most common causes for disagreement between CTA and conventional angiography are the presence of coronary vessel calcifications, the technique of estimation of stenosis and motion related degradation of image quality [13]. If good quality images are obtained then the other two causes become most significant reasons for discordant results.

In CTA stenosis is typically overestimated in areas where heavily calcified plaques are present or the lumen may not be assessable at all as was seen in 42% patients in this study by cross sectional luminal estimation method. In the study by Qi et al [14] a significant decrease in specificity, positive predictive value, and accuracy of CTA was seen for evaluating coronary stenosis was seen when vessel calcifications were greater than 50% of the luminal diameter and the CTA accuracy fell to 76% from 99%. Similar results are seen in our study which had accuracy of 76% for hemodynamic stenosis with sensitivity of 89% and specificity of 57%. Sensitivity for cross section method reduced further in our study when the threshold stenosis was fixed at  $> 70\%$  and there were increased false negatives of 35%. The reasons for reduced sensitivity for cross sectional method in our study were due to high prevalence of calcified plaques which made luminal assessment inaccurate and many of these vessels were labeled as non assessable in our study. Our study therefore suggests that cross sectional area estimation method alone is not robust enough to determine the selection of vessels requiring percutaneous intervention when there is presence of heavy calcification in the vessels. This was not the case with the use of AI method which showed a high sensitivity and specificity 91% and 100% respectively with an accuracy of 92%.

Dodd et al [15] also compared various techniques of stenosis estimation on CTA and found that the cross-sectional area technique had the highest correlation with quantitative coronary angiography and showed smallest inter observer variability but they did not account for the presence of vessel

calcifications which cause significant differences in stenosis estimation as seen in our study in which there was a high prevalence [72%] of calcifications and 23.6% vessels which were heavily calcified were non assessable by cross sectional methods. In the AI technique the steps of centre line extraction and lumen tracing were valuable in delineating true vessel course and lumen. We observed that these two steps were also invaluable in those arteries where there was less contrast however there were 11% of patients in AI method who required manual visual verification with correction of line tracing of vessels before luminal extraction. Our results varied from recently done CLARIFY trial [16] who showed high correlation of  $r=0.73$  between two methods while our study had a weak correlation of  $r=0.23$ . The likely cause for difference in results was that in our study all vessels with presence of heavy calcifications were labeled non assessable by cross sectional method for stenosis estimation thus diminishing its sensitivity. The CLARIFY trial [16] however does not mention about the status of vessel calcifications. It is possible that they might not have included patients with high CACS and thus showed an improved correlation between the two techniques. Had we included these heavily calcified vessels as evaluable in our study these would have been labelled falsely positive by cross section method and reduced positive predictive value of the study. Many of the other researchers who showed similar results of overall sensitivity and specificity of 90%, 92% for CTA compared with coronary angiography but had lower positive predictive values due to inclusion of calcified vessel segments as falsely positive [17, 18]. While these studies compared severity of stenosis on anatomical basis alone or with conventional angiography to show higher specificity and sensitivity our study fixed hemodynamic stenosis as the gold standard based on CTFFR of  $< 0.80$  which was more robust standard of ischemia.

## 5. Conclusion

To conclude our study shows that the use of AI estimated

method for coronary stenosis has a higher accuracy of 97% as compared to accuracy of 76% by conventional cross sectional method. AI method is more robust in clinical practice of evaluation of patients with stable coronary artery disease especially when there is higher coronary calcium and thus better identifies patients with hemodynamic significant stenosis with reduced FFR who are candidates for coronary interventions. The induction of AI method along with visual analysis and cross sectional area methods thus improves the accuracy of CTA in triaging patients to further management plan. The AI method is quick in stenosis estimation and is onsite and has the potential to improve vessel analysis of CTA.

## References

- [1] <https://www.nice.org.uk/guidance/cg95/resources/2019-surveillance-of-chest-pain-of-recent-onset-assessment-and-diagnosis-nice-guideline-cg95-pdf-8944464078277>.
- [2] Tonino PAL, De Bruyne B, Pijls NHJ, Siebert U, Ikeno F, van Veer M, Klauss Y, et al. Fractional flow reserve versus angiography for guiding percutaneous coronary intervention. *N Engl J Med*. 2009; 360 (3): 213-24. doi: 10.1056/NEJMoa0807611.
- [3] Nielsen LH, Ortner N, Norgaard BL, Achenbach S, Leipsic J, Abdulla J. et al. The diagnostic accuracy and outcomes after coronary computed tomography angiography vs. conventional functional testing in patients with stable angina pectoris: a systematic review and meta-analysis. *Eur Hear J – Cardiovasc Imaging*. 2014; 15 (9): 961-71. doi: 10.1093/ehjci/jeu027.
- [4] D. G. Harrison, C. W. White, L. F. Hiratzka, *et al.* The value of lesion cross-sectional area determined by quantitative coronary angiography in assessing the physiologic significance of proximal left anterior descending coronary arterial stenosis *Circulation*, 69 (1984), pp. 1111-1119.
- [5] W. Wijns, P. W. Serruys, J. H. Reiber, *et al.* Quantitative angiography of the left anterior descending coronary artery: correlations with pressure gradient and results of exercise thallium scintigraphy *Circulation*, 71 (1985), pp. 273-279.
- [6] A. Takagi, Y. Tsurumi, Y. Ishii, K. Suzuki, M. Kawana, H. Kasanuki Clinical potential of intravascular ultrasound for physiological assessment of coronary stenosis: relationship between quantitative ultrasound tomography and pressure-derived fractional flow reserve *Circulation*, 100 (1999), pp. 250-255.
- [7] J. Detre, E. Wright, M. L. Murphy, T. Takaro Observer agreement in evaluating coronary angiograms *Circulation*, 52 (1975), pp. 979-988.
- [8] L. M. Zir, S. W. Miller, R. E. Dinsmore, J. P. Gilbert, J. W. Harthorne Interobserver variability in coronary angiography *Circulation*, 53 (1976), pp. 627-632.
- [9] R. M. Fleming, R. L. Kirkeeide, R. W. Smalling, K. L. Gould Patterns in visual interpretation of coronary arteriograms as detected by quantitative coronary arteriography *J Am Coll Cardiol*, 18 (1991), pp. 945-951.
- [10] L. L. Leape, R. E. Park, T. M. Bashore, J. K. Harrison, C. J. Davidson, R. H. Brook Effect of variability in the interpretation of coronary angiograms on the appropriateness of use of coronary revascularization procedures *Am Heart J*, 139 (2000), pp. 106-113.
- [11] D. Keane, J. Haase, C. J. Slager, *et al.* Comparative validation of quantitative coronary angiography systems: results and implications from a multicenter study using a standardized approach *Circulation*, 91 (1995), pp. 2174-2183.
- [12] Muzzarelli S, Suerder D, Murzilli R, et al. Predictors of disagreement between prospectively ECG-triggered dual-source coronary computed tomography angiography and conventional coronary angiography. *Eur J Radiol*. 2016 Jun. 85 (6): 1138-46.
- [13] Qi L, Tang LJ, Xu Y, et al. The diagnostic performance of coronary CT angiography for the assessment of coronary stenosis in calcified plaque. *PLoS One*. 2016. 11 (5): e0154852.
- [14] Dodd JD, Rieber J, Pomerantsev E, et al. Quantification of nonculprit coronary lesions: comparison of cardiac 64-MDCT and invasive coronary angiography. *AJR Am J Roentgenol*. 2008 Aug. 191 (2): 432-8.
- [15] Choi AD, Marques H, Kumar V, Griffin WF, Rahban H, Karsberg RP, Zeman R, Katz RJ, Earls JP. CT Evaluation by artificial intelligence for atherosclerosis, stenosis and vascular morphology (CLARIFY): A multi-centre, international study. *J of cardiovascular Tomography* 15 (2021) 470-476.
- [16] Bettencourt N, Rocha J, Carvalho M, Leite D, Toshke AM, Melica B, Santos L, Rodrigues A, Goncalves M, Braga P, Teixeira M, Simoes L, Rajagopalan S, Gama V (2009) Multislice computed tomography in the exclusion of coronary artery disease in patients with presurgical valve disease. *Circ Cardiovasc Imaging* 2: 306–313.
- [17] Scheffél H, Leschka S, Plass A, Vachenaue R, Gaemperli O, Garzoli E, Genoni M, Marincek B, Kaufmann P, Alkadhi H (2007) Accuracy of 64-slice computed tomography for the preoperative detection of coronary artery disease in patients with chronic aortic regurgitation. *Am J Cardiol* 100 (4): 701 – 706.
- [18] Meijboom WB, Mollet NR, Van Mieghem CA, Kluin J, Weustink AC, Pugliese F, Vourvouri E, Cademartiri F, Bogers AJ, Krestin GP, de Feyter PJ (2006) Preoperative computed tomography coronary angiography to detect significant coronary artery disease in patients referred for cardiac valve surgery. *J Am Coll Cardiol* 48 (8): 1658–1665.