

Modified Bascom Cleft Lift Procedure for Management of Sacrococcygeal Pilonidal Sinus Disease: A Prospective Study

Mohamed Abdelshafy Mohamed¹, Abdallah Mohamed Taha^{1,*}, Mahmoud Abdelhameid¹,
Mostafa Mohamoud Sayed², Hamdy M. Hussein¹, Ayman Kamal³

¹General Surgery Department, Faculty of Medicine, South Valley University, Qena, Egypt

²General Surgery Department, Faculty of Medicine, Assuit University, Assiut, Egypt

³General Surgery Department, Faculty of Medicine, Helwan University, Helwan, Egypt

Email address:

abdallahsurgery@yahoo.com (A. M. Taha)

*Corresponding author

To cite this article:

Mohamed Abdelshafy Mohamed, Abdallah Mohamed Taha, Mahmoud Abdelhameid, Mostafa Mohamoud Sayed, Ayman Kamal. Modified Bascom Cleft Lift Procedure for Management of Sacrococcygeal Pilonidal Sinus Disease: A prospective Study. *Advances in Surgical Sciences*. Vol. 6, No. 2, 2018, pp. 50-55. doi: 10.11648/j.ass.20180602.12

Received: July 29, 2018; **Accepted:** August 17, 2018; **Published:** September 25, 2018

Abstract: Background: Many options are available for treatment sacrococcygeal pilonidal sinus disease either surgical or medical, but surgery is preferred. There are many techniques for surgical treatment but there is controversy about the best technique. Until now there is no single procedure is superior in all aspects. The aim of this study was to evaluate modified Bascom Clift lift procedure in management of. Patients and methods: From April 2014 to July 2018, 150 patients with pilonidal sinus were treated with Clift lift procedure and followed. Data collected tabulated and analyzed included complications, recurrence, post-operative hospital stay, days-off work, postoperative aesthetic appearance and patient's satisfactions. Results: There were 150 patients, 129 male and 21 females with M:F ratio. Their ages ranges from 16 to 45 year, with mean age 22.55 ± 8.5 year. Fifteen patients (10%) had previous operation for pilonidal sinus (recurrent). After operation all patient were mobilized at first day, mean postoperative pain VAS score were about 2(1-3) and discharged from hospital at 2nd day and were returned to daily activities after mean 7 day (6-12 days), return to work at mean (12.5) days with good healing within 10 days, postoperative wound infection had occurred only in three patients (2%). Patients satisfaction score were very good. No recurrence was observed during follow up period. Conclusion: Modified Bascom natal cleft lift is associated with good outcome, it is simple procedure and easy to learn, with early mobilization, short hospital stay early return to daily activities and work, and good patients satisfaction and to somewhat accepted post-operative scar. More studies with larger group of patients are needed especially in recurrent cases to come to consensus.

Keywords: Modified Bascom Clift Lift, Pilonidal Sinus Disease, Sacrococcygeal

1. Introduction

Pilonidal sinus disease (PND) is a common chronic, disease occurs mainly in young adults. Although it may occurs in many sites but, it is usually seen in the sacrococcygeal region and it has negative impact on the quality of life [1]. Although it was first described as a congenital disease, it is currently known to be an acquired condition [1]. The term pilonidal is derived from the Latin words pilus

(hair) and nidus. It is occurs mainly between the ages of 15-25 and affect males more than females and it is rare to see it before puberty or after the age of 40 years [2]. Its incidence is 26 per 1,00,000 people and observed at a rate of 0.7% in the general population [3]. It present as an abscess, cyst or sinus tracts with or without purulent discharge in the pre-sacral region [4]. The main complaint of the patients is painless, continuous or periodic discharge. However, with a carefully taken medical history, a large percentage will reveal previously experienced abscesses [5].

According to Karydakís [6], the pathogenesis of pilonidal sinus may attributed to three main factors which are necessary to cause pilonidal disease [1]. Loose hairs invading intergluteal cleft, which may fall from the back or neck [2], some force lead to hair insertion, for example riding in a jeep [3], the loss of barrier function of the skin in a deep and wet natal cleft with maceration and bacterial colonization. This barrier function is also lost in a surgical scar in this region [6, 7].

The ideal method of pilonidal sinus treatment should have a low recurrence rate with minimum excision, a short hospitalization stay, and patient return to his normal life rapidly with small scar [2, 8].

There is controversy about the best method for treatment of sacrococcygeal pilonidal sinus disease. There are many surgical and conservative options had been used for treatments. The Surgical methods are varying from the simple incision, drainage, unroofing, curettage and spontaneous secondary healing to excision-flap sliding, Karydakís, Bascom, and MacFee methods. The main basis of surgical treatment of pilonidal sinus treatment including surgical excision of the sinus tracts, followed by either primary closure after excision or left open the wound for secondary healing. These are the most commonly used surgical method. Conservative methods including phenol solution, the crystallized phenol method, cauterization and alcohol injection have also been used [9]. However, among these treatment methods, an optimal treatment type has not been described yet [10].

There are Cochrane review done by McCallum et al., [2] and they found that a consensus for treatment of pilonidal disease has never been formed [2, 11, 13]. As regarding comparison of wound healing time between the open and closed surgical methods, many authors conclude that there is no clear benefit demonstrated for one of both techniques and off-midline closing techniques had better results than midline closing techniques, however, data was limited [2, 13].

The aim of this present study is to evaluate one of the new off- midline procedures which named modified Bascom cleft lift procedure regarding complications, postoperative pain and mobilization, post-operative hospital stay return to daily activity, healing time, days-off work, recurrence, postoperative aesthetic appearance and patient's satisfactions.

2. Patients and Methods

This prospective observational study included patients with pilonidal sinus admitted to general surgery departments, Faculties of Medicine at Qena, Assiut and Helwan University hospitals, as well as, in private hospitals, and managed by the authors, between April 2014 and July 2018.

2.1. Patients

This study included **150** patients with diagnosed pilonidal sinus disease. Patients with active infection and patients with chronic medical disease that affects healing process, such as diabetes mellitus, renal failure, or immune-suppression were

excluded from the study.

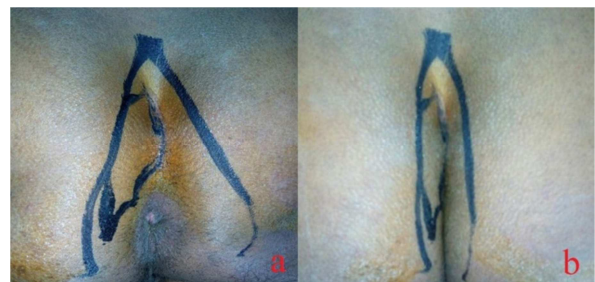2.2. Preoperative Management

All patients were subjected to careful history taking, clinical examination regarding number and site of pits and sinuses and preoperative routine laboratory investigation. Patients was counseled and fully informed in the outpatient's clinic before operation about nature of the disease and nature of procedure and possible complications, Informed consent obtained from all patients after explanation of nature of disease, and possible treatment.

Prophylactic antibiotics (500mg Metronidazole and 1gm third generation cephalosporin sodium) was given intravenously before shifting the patient to operative room.

2.3. Procedure

The procedure was carried out under spinal anesthesia, in jack knife position, fifteen patients request general anesthesia. Shaving of sacrococcygeal region extended to periphery of the thigh on both sides was done, then cleaning the area with Povidone Iodine 7.5%. The buttocks pushed together before surgery and the contact area between buttocks was marked (*Figure 1*).



a: Buttocks pulled apart b: Buttocks in normal position

Figure 1. Marking buttocks contact area and skin ellipse to be excised.

Methylene blue dye didn't used to avoid discoloring of tissues and false tracts. Then the buttock were pulled apart wide and fixed with plastic strips.

Skin ellipse about 4cms wide adjusted more to the left side was marked then, excised including all the openings of the sinuses but keeping the subcutaneous tissues including the abscess cavity which is curetted with gauze (*Figure 2*).

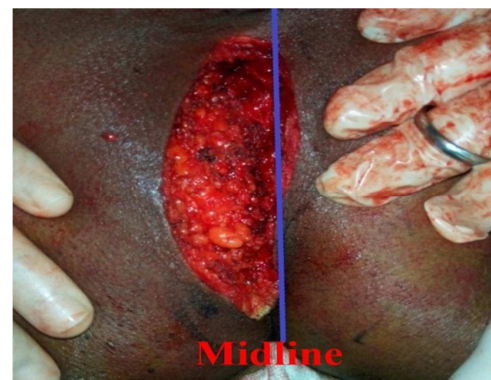


Figure 2. Excised skin ellipse adjusted more to the left side.

Asymmetrical excision created a flap, which is pulled past the natal cleft to the contralateral side. Skin flap is freed from the right side and advanced across the midline to be sutured to the other, and suction drain was fixed under subcutaneous tissues. Subcutaneous tissue were closed with sutures with Vicryl 3/0, skin was closed by interrupted 3/0 Prolene sutures or subcuticular Vicryl 3/0 in some cases (*Figure 3*).

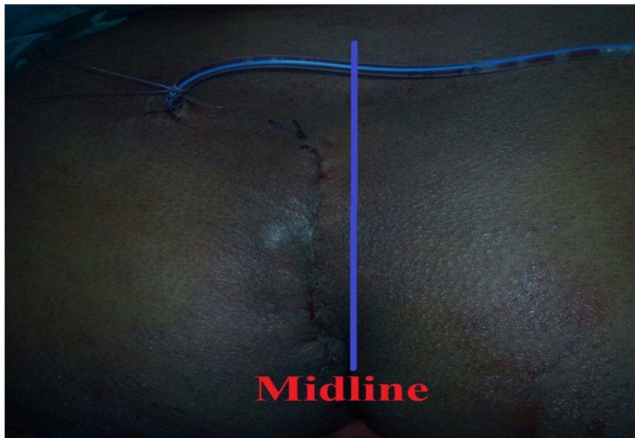

Figure 3. Skin closure after cleft lift procedure and releasing of right skin flap. (The Wound is to the left of midline and not under tension).

2.4. Postoperative Management

Postoperative management included post-operative antibiotics, analgesics, daily dressing. Patient's ambulation and sitting began immediately after recovery, VAS (visual analogue scale) score for pain was recorded for every patient, and first toilet seat without pain was recorded, suction drain which usually removed after 2-3 days (when volume less than 10 /ml). And IV antibiotic 2 doses in the first postoperative day and oral antibiotic on discharge after 24 hours if no complications were noticed. Follow up in surgery outpatient clinic weekly for one month, then on 3, 6 months and 12 month following surgery. The sutured were removed in the third visit.

2.5. Satisfaction Score

Patients were asked a standard question, are you satisfied with outcome of your surgical treatment? Answers were scored in a discrete ordinal scale from 1 to 4 with 4 for excellent, 3 good, 2 fair, and 1 poor.

2.6. Data Collection

Data of patients was collected tabulated and analyzed. Patient data included gender and age, location of sinus pits, post-operative complications, postoperative pain and mobilization, post-operative hospital stay return to daily activity, healing time, days-off work, recurrence, postoperative aesthetic appearance and patient's satisfactions.

2.7. Statistical Analysis

SPSS was used to analyze data (Statistical Package for the Social Sciences ver. 20, SPSS Inc., Chicago, Illinois, USA)

computer software for Statistical analysis. For all statistical analyses, $p > 0.05$ was considered significant.

3. Results

There were 150 patients, 129 male and 21 females. Their ages ranges from 16 to 45 year, with mean age 22.55 ± 8.5 year. Fifteen patients (10%) had previous operation for pilonidal sinus (recurrent).

Duration of symptoms until day of admission ranged from 2.5 to 3 years with mean of duration 12.5 month. Main complains was pain in 117 patients (78%) and recurrent discharge in 105 patients (70%).

Table 1. Patient's clinical parameters.

Patients Parameters	Result
Mean age	22.55
M: F ratio	129/21 (6.2:1)
Mean duration of symptoms	12.5
Recurrent to denovo pilonidal sinus	1:10
Main Complaint	
Pain	78%
Discharge	70%
Site	
Midline single	30 patients (20%)
Midline multiples	105 patients (70%)
Para-midline	15 patients (10%)
Obesity	
Average BMI <25	27 patients (18%)
Overweight (BMI 25-29.9)	87 patients (58%)
Obese (BMI 30-39.9)	33 patients (22%)
Morbidly obese (BMI X 40)	3 patients (2%)

Mean operative time was 40 ± 5 minutes (ranged from 25 - 60 minutes). All patients early mobilized in first day and discharged from hospital in 2nd postoperative day usually. Dressings were once daily till the first postoperative outpatient's clinic visit after 3 (2-5) days where suction usually removed. Healing was by first intention in all patients except, wound infection was only in one patients and only need one stitch removal and healed by secondary intentions, no wound dehiscence happened in any patients, wound healed in periods range from one week to 14 days with mean healing time 10 days.

Patients returned to usual normal daily activities immediately after stitches removal on 6 to 12 days (Mean 7 days) and returned to work on 10 to 15 days with mean 12, 5 days. The postoperative follow up from 12 to 30 months and no recurrences were developed in the follow up period.

As regarding complications, seroma only in three patients was mild after drain suction removed and treated conservatively and stopped after 3 days, three patients developed only mild wound infection treated by one stitch removal and antibiotic and successfully healed.

Table 2. Postoperative results and complications.

Parameter	Result
Suction drainage time (in days)	2.5(2-5)
First mobilization day	Day 1
Length of hospital stay (in days)	1.5 (1-3)
Healing time (in days)	10(7-14)
Time to return to normal daily activities (in days)	7(6-12)
Time to return to work (in days).	12.5(10-15)
Pain VAS score	2(1-3)
Painless toilet seating time (in days)	1(1-2)
Toilet seat (in days)	8(6-12)
Patient satisfaction score	3.2 \pm 0.66
Follow up (in months)	20 (15-30)
Complications:	
Wound infection	3 patients (2%)
Seroma formation	3 patients (2%)
Flap oedema	0
Flap partial ischemia	0
Flap necrosis	0
Partial wound dehiscence	3 patients (2%)
Total wound Dehiscence	0
Recurrence rate	0
Irregular scar formation	3 patients (2%)

4. Discussion

Although pilonidal sinus disease was first described by *Anderson* in 1847 and by *Hodges* in 1880 [13, 14], but until now there are a controversy about the ideal method for treatment.

Pilonidal as a word means "a nest of hair". Pilonidal sinus disease PSD is a benign chronic condition start with localized inflammation with abscess formation causing sinus, fistula, and chronic Inflammation, chronic or intermittent discharges and may occur in many sites as axilla and umbilicus, interdigital, but it is usually seen in the sacrococcygeal region (natal cleft), although it is chronic but often presented with acute exacerbations [15]. In the past, it was thought to be a congenital disease but recently it is more accepted to be an acquired condition [16].

Pilonidal sinus disease is usually present in young adults more common in males more than females. Because it is a chronic condition with acute exacerbations, occurred in adulthood from puberty to forties, which considered the main productive years in life and its related morbidity affecting the quality of life and financial state of the persons and economy of the country especially days-off work during acute exacerbations [2].

Hospital admission of these patients for the treatment of pilonidal disease, and follow up visits and days-off work resulted in a loss of productivity, a loss of earning, and a interruption of education [17, 18].

The etiology and pathogenesis of pilonidal sinus is still a matter of debate. According to *Karydakis* [6], the pathogenesis of pilonidal sinus may attributed to three main factors which are necessary to cause pilonidal disease including loose hairs invading intergluteal cleft, which may fall from the back or neck, some force leads to hair insertion, for example riding in a jeep, and loss of barrier function of

the skin in a deep and wet natal cleft with maceration and bacterial colonization. This barrier function is also lost in a surgical scar in this region [6, 7]. Also *Bascom* showed that the pilonidal sinus disease starts as a midline pit or pits which result in inflamed or infected hair follicles and deep natal cleft lead to creation of moist anaerobic environment whereas the motion of buttocks and sitting pressure helps in bursting the distended hair follicle in the subcutaneous fat causing an acute abscess [18]. The repetition of this process at subacute level leads to chronic pilonidal sinus disease. *Miocinovic et al.*, explained why sacrococcygeal pilonidal disease occurs in the midline or recurrent after midline scar, as increased depth of the intergluteal sulcus leads to an anaerobic media and increased anaerobic bacterial content, also, the vacuum effect that present between heavy buttocks is thought to play an additional role in pilonidal disease development because it sucks the anaerobic bacteria, hair, and debris into the subcutaneous fat tissue [19]. If these factors responsible for the development of the disease eliminated, this will lead to decrease recurrence rates. So, most of authors thinking that the most important factor in development or recurrences of sacrococcygeal pilonidal sinus disease is the deepness of natal cleft and if the surgeon makes natal cleft more shallow and post-operative scars away from midline this decrease recurrence rates.

Although, there are many surgical and nonsurgical treatment methods have been described for treatment of pilonidal sinus disease but, the ideal treatment method has not yet been established. There are Cochrane review done by *McCallum et al.*, [2] and they found that a consensus for treatment of pilonidal disease has never been formed [2, 11, 12]. Complete excision of the sinus is widely practiced, but still remains a controversy about what to do with the wound after excision. Excision and packing (to leave it heal by secondary intention) excision and marsupialization to decrease healing time, excision and primary closure, and flap techniques are surgical procedures that have been developed for treatment of pilonidal sinus.

Despite the controversy about the best surgical technique for the treatment of pilonidal sinus, an ideal operation should simple to perform, inflict minimal pain, with early mobilization and early return to daily activities and short hospital stay, minimize financial cost for the community, allow patients to return earlier to work, rapid healing with a low recurrence rates, good postoperative cosmetic appearance, good patients satisfactions, and easy to learn [20, 21].

Less invasive procedures such as simple incision with curettage or excision with primary closure lead to faster convalescence, but also result in a midline scar in a persistent deep natal cleft, potentially leading to high recurrence rates [9, 22]. In order to avoid median recurrences and flatten the natal cleft, surgeons have developed numerous procedures such as the *Karydakis* technique [3, 23, 24], *Bascom* procedure, modified *Bascom* [18, 25] and other asymmetrical closing techniques [26, 27] such as rhomboid excision with *Limberg* [28, 29] or *Dufourmentel* flap closure [30], Z-plasty

[31] or rotation flap. In general, results of these asymmetrical closure and flap techniques seem better than results of open technique or primary midline closure techniques, although the surgical trauma is more extensive, and cosmetic results are not always optimal and require long operative time and long hospital stay and with complications like loss of the graft or flap [32].

Excision and primary closure although it has advantages of rapid healing and relative early return to work 3-4 week but there are high recurrences rates reported in literature from 7-42% which is relatively high [33, 34]. Rhomboid excision and Limberg flap procedure have low recurrences rates 0f 0-3% but also have unfavorable cosmetic appearance after healing [5, 35, 36].

Although most of recent surgical procedure has a low recurrence rates but most of them lack of a complete patients satisfaction regarding postoperative pain, healing time, early mobilization, hospital stay, return to daily activities and days-off work and post-operative scar appearance.

So quality of life is the main goal for patients with pilonidal disease. Recently, Bascom and Bascom [18] described modification for Karydakias and Kitchen procedure [24], which will be presented in this study. Cleft lift technique differ from Karydakias [18] and Kitchen [24] as this technique avoid removal of all deep inflamed tissue and use of thick flaps of fat attached to skin, so shift skin alone, it reduces the depth of the natal cleft. It relocates the healing line, moving it out to the surface without division or mobilization of muscle and fascia. This technique requires resection of the pilonidal sinus flattening the raphe of the natal cleft and tension-free asymmetrical closure, avoiding a scar in the midline. In contrast to other flap techniques, the contour of the buttocks is hardly severed, resulting in a good to excellent cosmetic result, it also minimizes the days-off work, deviation from normal activities, and cost. There is also reduction in healing time in modified Bascom natal cleft lift and improvement in quality of life

This study prospectively evaluated this new procedure in treatment of pilonidal sinus either de novo or recurrent, regarding postoperative pain and mobilization, healing time, hospital stay, patients satisfactions and if it improve quality of life after operation or not.

The mean age were 22.55 ± 8.5 year and this similar to which reported in literature that pilonidal sinus disease occurs frequently between the ages of 15 years and 25 years, and is rare both before puberty and after the age of 40 years [37], so it occurs in the main productive age. Regarding operative and post-operative results, all patients mobilized at first day, with mean hospital stay 1.5 days, and all patients were returned to daily activities within mean one week and the mean healing time was 10 days. Patients can return to work after mean time 12.5 days (10-15days). Days-off work were much lower than that reported in other flap procedure with good to excellent patients satisfaction score and to somewhat accepted postoperative scars appearance.

As regarding recurrence rates, recurrence was defined as the presence of any persistent purulent or blood stained

discharge from the previously operated or the nearby area during the follow-up. No recurrence was observed in all patients during flow up period. This may be attributed to that the number of cases was not so much and follow up period was to somewhat short, and most of cases were denovo not recurrent.

By comparing study results with other studies and series that have shown wound complications and recurrence rates, we found that in study by *El-Sayed M. et al.*, on 24 patients on recurrent pilonidal sinus diseases, he hadn't observed any recurrences in a short mean follow-up period of 20 months, all patients tolerated the procedure well, with minimal to moderate postoperative discomfort, full return to duty was possible in three weeks after surgery, but there were 3 patients of limited primary healing failure and he hadn't observed any recurrences have developed in a short mean follow-up period of 20 months [38]. In study by *Theodoropoulos et al*, all left tissues in place as we did in this study, with similar success [39].

In A retrospective study on 62 patients study by *R. Dudinkl et al.*, [40] to compare between Secondary healing versus midline closure and modified Bascom natal cleft lift for pilonidal sinus disease, they found that modified Bascom technique showed a significantly reduced wound healing time (29 days) compared to primary closure (52 days, $p < 0.01$) and secondary healing (62 days, $p < 0.01$). The duration of this modified procedure was significantly longer (49, 33 and 24 minutes respectively, $p < 0.01$), and they concluded that on the basis of the data presented in their study that the modified Bascom natal cleft lift is associated with better outcome than both midline closure and secondary wound healing techniques.

5. Conclusion

Modified Bascom natal cleft lift is associated with good outcome, it is simple procedure and easy to learn, with early mobilization, short hospital stay early return to daily activities and work, and good patients satisfaction and to somewhat accepted post-operative scar. More studies with larger group of patients are needed especially in recurrent cases to come to consensus.

References

- [1] Hull TL, Wu J. Pilonidal disease. *Surg Clin North Am* 2002; 82: 1169-1185.
- [2] McCallum I, King PM, Bruce J: Healing by primary versus secondary intention after surgical treatment for pilonidal sinus. *Cochrane Database Syst Rev* 2007 Oct 17;(4).
- [3] Aslam MN, Shoaib S, Choudhry AM. Use of Limberg flap for pilonidal sinus-a viable option. *J Ayub Med Coll Abbottabad*. 2009; 21(4):31-3.
- [4] Onder A, Girgin S, Kapan M, Toker M, Arikanoğlu Z, Palancı Y, et al. Pilonidal sinus disease: risk factors for postoperative complications and recurrence. *Int Surg* 2012; 97:224-9.

- [5] Eryilmaz R, Sahin M, Alimoglu O, Dasiran F. Surgical treatment of sacrococcygeal pilonidal sinus with the Limberg transposition flap. *Surgery* 2003; 134:745–9.
- [6] Karydakakis GE: Easy and successful treatment of pilonidal sinus after explanation of its causative process. *Aust N Z J Surg* 1992 May; 62(5):385–389.
- [7] Da Silva JH: Pilonidal cyst: cause and treatment. *Dis Colon Rectum* 2000 Aug; 43(8):1146–1156.
- [8] Bayhan, Z., Zeren, S., Duzgun, S. A., Ucar, B. I., AlparslanYumun, H. N., Mestan, M. (2016) Crystallized phenol application and modified Limberg flap procedure in treatment of pilonidal sinus disease: A comparative retrospective study. *Asian J. Surg.* 39, 172–177.
- [9] Girgin M, Kanat BH. The results of a one-time crystallized phenol application for pilonidal sinus disease. *Indian J Surg* 2014; 76:17-20.
- [10] Kayaalp C, Olmez A, Aydin C, Piskin T, Kahraman L. Investigation of a one-time phenol application for pilonidal disease. *Med Princ Pract* 2010; 19:212-5.
- [11] Lund JN, Leveson SH: Fibrin glue in the treatment of pilonidal sinus: results of a pilot study. *Dis Colon Rectum* 2005 May; 48(5):1094-1096.
- [12] Dogru O, Camci C, Aygen E, et al: Pilonidal sinus treated with crystallized phenol: an eight-year experience. *Dis Colon Rectum* 2004 Nov; 47(11):1934–1938.
- [13] Anderson AW. Hair extracted from an ulcer. *Boston Med Surg J.* 1847; 36:76.
- [14] Hodges RM (1880) Pilonidal sinus. *Boston Med Surg J* 103:485–486.
- [15] Surrell JA: Pilonidal disease. *Surg Clin North Am.*, 1994; 74(6): 1309-1315.
- [16] McCallum IJ, King PM, Bruce J. Healing by primary closure versus open healing after surgery for pilonidal sinus: systematic review and meta analysis. *BMJ.* 2008; 336(7649):868-71.
- [17] Sondenaa K, Andersen E, Nesvik I, Søreide JA. Patient characteristics and symptoms in chronic pilonidal sinus disease. *Int J Colorectal Dis* 1995; 10(1):39–42.
- [18] Bascom J, Bascom T. Failed pilonidal surgery: new paradigm and new operation leading to cures. *Arch Surg* 2002; 137(10): 1146–1150.
- [19] Miocinovic M, Horzic M, Bunoza D. The prevalence of anaerobic infection in pilonidal sinus of the sacrococcygeal region and its effect on the complications. *Acta Med* 2001; 55:87–90.
- [20] Kayaalp C, Aydin C. Review of phenol treatment in sacrococcygeal pilonidal disease. *Tech Coloproctol* 2009; 13(3):189–193.
- [21] Lee SL, Tejirian T, Abbas MA. Current management of adolescent pilonidal disease. *J Pediatr Surg* 2008;43(6):1124–1127.
- [22] Dalenback J: Prospective follow-up after ambulatory plain midline excision of pilonidal sinus and primary suture under local anaesthesia-efficient, sufficient, and persistent. *Colorectal Dis* 2006 Jan; 8(1):73–74.
- [23] Morden P, Drongowski RA, Geiger JD, et al: Comparison of Karydakakis versus midline excision for treatment of pilonidal sinus disease. *Pediatr Surg Int* 2005 Oct; 21(10):793–796.
- [24] Kitchen PR: Pilonidal sinus: experience with the Karydakakis flap. *Br J Surg* 1996 Oct; 83(10):1452–1455.
- [25] Bascom JU: Repeat pilonidal operations. *Am J Surg* 1987 Jul; 154(1):118–122.
- [26] Menten O, Bagci M, Bilgin T, et al: Management of pilonidal sinus disease with oblique excision and primary closure: results of 493 patients. *Dis Colon Rectum* 2006 Jan; 49(1):104–108.
- [27] Lord PH, Millar DM: Pilonidal sinus: a simple treatment. *Br J Surg* 1965 Apr; 52:298–300.
- [28] Cihan A, Ucan BH, Comert M, et al: Superiority of asymmetric modified Limberg flap for surgical treatment of pilonidal disease. *Dis Colon Rectum* 2006 Feb;49(2):244–249.
- [29] Akca T, Colak T, Ustunsoy B, et al: Randomized clinical trial comparing primary closure with the Limberg flap in the treatment of primary sacrococcygeal pilonidal disease. *Br J Surg* 2005 Sep; 92(9):1081–1084.
- [30] Dufourmentel C, Mouly R, Baruch J, et al: Sacrococcygeal cysts and fistulas. Pathogenic and therapeutic discussion. *Ann Chir Plast* 1966 Sep; 11(3):181–186.
- [31] Monro RS, McDermott FT: The elimination of causal factors in pilonidal sinus treated by z-plasty. *Br J Surg* 1965 Mar;52:177–181.
- [32] Zieger K. Complications after surgery for pilonidal cyst. An introduction to a new debate on a “costly” disease. *UgeskrLaeger* 1999;161(44):6056 – 58.
- [33] Khaira HS, Brown JH. Excision and primary closure of pilonidal sinus. *Ann R CollSurgEngl*1995; 77:242–4.
- [34] Iesalnieks I, Furst A, Rentsch M, Jauch KW. Primary midline closure after excision of a pilonidal sinus is associated with a high recurrence rate. *Chirurg*2003; 74:461–8.
- [35] Menten BB, Leventoglu S, Cihan A, Tatlicioglu E, Akin M, Oguz M. Modified Limberg transposition flap for sacrococcygeal pilonidal sinus. *Surg Today* 2004; 34:419–23.
- [36] Azab AS, Kamal MS, el Bassyoni F. The rationale of using the rhomboid fasciocutaneous transposition flap for the radical cure of pilonidal sinus. *J DermatolSurgOncol*1986; 12:1295–9.
- [37] Keighley MRB, Williams N. Pilonidal sinus. Surgery of the Anus, Rectum and Colon. 2nd ed. London: WB Saunders; 1999:539e563.
- [38] El- Sayed M. Abel- Razek. Cleft Lift Operation for Recurrent Pilonidal Sinus Repair. Two Years Experience Egypt, *J. Plast. Reconstr. Surg.*, Vol. 30, No. 1, January: 7-11, 2006.
- [39] Theodoropoulos G. E., Vlahos K., Lazaris A. C., TahterisE. And Panoussopoulos D.: Modified Bascom’s asymmetric midgluteal cleft closure technique for recurrent pilonidal disease: early experience in a military hospital: *Dis. Colon. Rectum.* Sep., 46 (9): 1286-91, 2003.
- [40] Dudink1, J. Veldkamp2, S. Nienhuijs1, J. Heemskerk3 Secondary healing versus midline closure and modified Bascom natal cleft lift for pilonidal sinus disease. *Scandinavian Journal of Surgery* 100: 110–113, 2011.