

Combined effect of curcumin and vitamin E against CCl₄ induced liver injury in rats

Venkatanarayana Gangarapu¹, Sudhakara Gujjala², Rajeswaramma Korivi³, Indira Pala^{1,*}

¹Department of Zoology, Sri Krishnadevaraya University, Anantapur.

²Department of Biochemistry, Sri Krishnadevaraya University, Anantapur

³Department of Chemistry, Sri Venkateswara University, Tirupati

Email address:

palaindira@yahoo.com (Indira P.), venkat.abhi54@gmail.com (Venkatanarayana G.), gsudhasu@gmail.com (Sudhakara G.),
rajivenkat74@gmail.com (Rajeswaramma K.)

To cite this article:

Venkatanarayana Gangarapu, Sudhakara Gujjala, Rajeswaramma Korivi, Indira Pala. Combined Effect of Curcumin and Vitamin E against CCl₄ Induced Liver Injury in Rats. *American Journal of Life Sciences*. Vol. 1, No. 3, 2013, pp. 117-124.
doi: 10.11648/j.ajls.20130103.17

Abstract: The present study was aimed to investigate the combined effect of curcumin[CMN] and vitamin E against CCl₄ induced oxidative stress and liver toxicity in rats. The toxicant CCl₄ was used to induce liver toxicity at a dose of 1ml/kg as 1: 1 (v/v) mixture with liquid paraffin twice weekly for 8 weeks and silymarin was used as a standard drug to compare hepatoprotective effects of CMN and vitamin E. The antifibrotic effects of CMN and vitamin E were assessed directly by hepatic histology and indirectly by measuring levels of the aspartate transaminase (AST), alanine transaminase (ALT), alkaline phosphatase (ALP) and lipid profile (total cholesterol and triglycerides) in serum. Further, we investigated lipid peroxidation (TBARS), enzymatic antioxidants (catalase, superoxide dismutase, glutathione peroxidase, glutathione-S-transferase, glutathione reductase) and non-enzymatic antioxidant glutathione (GSH) were estimated in the liver samples. Oral administration of CMN(100mg/kg daily for 8 weeks) and in combination with vitamin E (40mg/kg thrice weekly for 8 weeks) showed significant hepatoprotection by decreasing elevated serum markers and lipid profile. In addition significantly decreased the hepatic lipid peroxidation as well as recovered the activities of antioxidant enzymes and GSH levels in the liver. Histopathological studies confirmed the biochemical observations. This study reveals CMN in combination with vitamin E possesses strong antioxidant and hepatoprotective activity than CMN alone.

Keywords: Curcumin, Carbon Tetrachloride, Oxidative Stress, Vitamin E, Silymarin

1. Introduction

Liver fibrogenesis is common to various types of chronic liver disease [1,2]. The possible consequences of fibrogenesis include liver cirrhosis or hepatocellular carcinoma [3-7]. There are increasing evidences that free radicals and reactive oxygen species play a crucial role in the various steps that initiate and regulate the progression of liver diseases independently of the agent in its origin [8, 9]. Various xenobiotics are known to cause hepatotoxicity one among them is carbon tetrachloride (CCl₄) [10]. Reductive dehalogenation of CCl₄ by the P450 enzyme system to the highly reactive trichloromethyl radical initiates the process of lipid peroxidation which is considered to be the most important mechanism in the pathogenesis of liver damage induced by CCl₄ [11]. Trichloromethyl radical can even react with sulfhydryl

groups of glutathione (GSH) and protein thiols. In addition, CCl₄ also alters the antioxidant profile of the liver including the antioxidant enzymes like superoxide dismutase (SOD), catalase (CAT), glutathione peroxidase (GPx), glutathione reductase (GR), and glutathione transferase (GST) [12, 13].

Antioxidants are vital substances which possess the ability to protect the body from damage caused by free radical induced oxidative stress [14,15]. There is an increasing interest in natural antioxidants, e.g. polyphenols, present in medicinal and dietary plants, which might help prevent oxidative damage. In treatment of these diseases, antioxidant therapy has gained an immense importance. Current research is now directed towards finding naturally occurring antioxidants of plant origin [16]. Curcumin(1,7-bis (4-hydroxy-3-methoxyphenyl)-1,6-heptadiene-3,5-dione, 1) is a naturally occurring phenolic compound

isolated as a yellow pigment from turmeric (dry rhizomes of *Curcumin longa*) which is commonly used as a spice and food colorant [17]. This compound has been reported to possess a variety of biological and pharmacological activities, including antioxidant [18-22], anti-inflammatory [23], anticarcinogenic [24-26] and anti-HIV [27].

Liver disease is a worldwide problem. Conventional and synthetic drugs used in the treatment of liver diseases are sometimes inadequate and can have serious adverse effects. It is therefore necessary to search for alternative drugs for the treatment of liver diseases to replace currently used drugs of doubtful efficacy and safety [28, 29]. However, No study has so far examined on the protective effects of curcumin along with vitamin E on CCl₄ induced liver damage. Therefore, in continuation of the search for potential modulators of CCl₄-mediated hepatic damage, we have investigated the combined effects of curcumin, a naturally occurring polyphenol and vitamin E on experimentally induced CCl₄ hepatic oxidative stress in rats.

2. Materials and Methods

2.1. Chemicals and Drugs

Carbon tetrachloride was purchased from MERK India Ltd., Curcumin and α -Tocopherol [Vitamin E] purchased from Sigma chemicals Co. St Louis. Silymarin suspension purchased from Micro labs, Bangalore.

2.2. Animals

Adult male albino rats Wistar strain weighing 190 ± 30 g procured from Sri Raghavendra Animal Supplier, Bangalore, Karnataka, were used for the study after the clearance from Institutional Animal Ethical Committee (CPCSEA) REGD. No. 470/01/a/ CPCSEA, DT. 24th Aug 2001. They were kept in cages under standard laboratory conditions ($23 \pm 2^\circ\text{C}$, 12 h dark/light) and were fed with commercial rat feed supplied by SaiDurga Feeds and Foods, Bangalore and water *ad libitum*. Before use prior to the experimentation they were allowed to laboratory conditions for ten days.

2.3. Experimental Protocol

Animals were randomly assigned into seven groups of six each. Group 1 served as normal control and received Phosphate Buffer Saline (p.o daily for 8 weeks). Group 2 CMN control (100 mg/kg p.o daily for 8 weeks). Group 3 CMN (100 mg/kg p.o daily for 8 weeks) + Vitamin E (40 mg/ kg p.o thrice weekly for 8 weeks). Group 4 received CCl₄ (1ml/kg 1:1 in liquid paraffin p.o., twice weekly for 8 weeks). Group 5 CCl₄ + CMN (100 mg/ kg p.o for 8 weeks). Group 6 CCl₄ + CMN (100 mg/ kg p.o daily, Vitamin E 40 mg/ kg weekly thrice p.o for 8 weeks). Group 7 CCl₄ + Silymarin (50 mg/ kg p.o daily for 8 weeks).

2.4. Selection of Dose

The dose of CCl₄ (1ml/ kg Wt) [30, 31], the dose of curcumin 100 mg/ kg wt. [32] and the dose of Vitamin E [33] were selected with minor modifications.

2.5. Sacrifice of Animals and Collection of Blood and Liver

At the end of experimentation and 24 h after the last dose of CCl₄, rats were sacrificed by cervical dislocation. Just before sacrifice, the animals were anesthetized with pentobarbital [0.6 ml/ kg] and the blood collected by heart puncture and transferred into eppendorf tubes, allowed to clot for 30 min. Serum was separated by centrifugation at 2500rpm for 15 min and used for biochemical estimations.

After sacrifice, immediately liver was removed and washed thoroughly with ice-cold 0.9 % sodium chloride solution [saline] and cut in to micro pieces fixed in 10 % formalin for histological examinations.

2.6. Biochemical Analysis

2.6.1. Serum Biochemical Analysis

The activities of serum aspartate transaminase (AST) alanine transaminase (ALT) and alkaline phosphatase (ALP) were estimated by using kits obtained from Erba diagnostics Mannheim, Baddi, H.P., India and Aspen laboratories, Baddi, H.P., India (for ALP). Lipid profile (TC and TGLs) was estimated by using kits obtained from Excel Diagnostics Pvt. Ltd, Hyderabad, India.

2.6.2. Assessment of Hepatic Lipid Peroxidation

Ten percent tissue homogenate was prepared in 0.15 M potassium chloride using by using potter-elvehjem homogenizer at 0°C . Lipid peroxidation was estimated by method of Utely *et al.* (1967) [34]. The whole homogenate was used for estimation of glutathione and lipid peroxidation. Briefly to 1.0 ml of the liver homogenate, 2.0 ml of TCA and 4.0 ml of TBA were added, heated in water bath for 30 minutes. After cooling and centrifugation, the absorbance of the supernatant was read at 535 nm. A reagent blank was prepared using water instead of tissue homogenate. The extent of lipid peroxidation was expressed as nmol MDA formed/mg protein, using a molar extinction co-efficient of MDA as $1.56 \times 10^5 \text{ M}^{-1} \text{ cm}^{-1}$.

2.6.3. Assessment of Hepatic GSH

Total reduced glutathione (GSH) content was measured following the method of Ellman's (1959) [35]. Briefly 0.5 ml of liver tissue homogenate was deproteinized with 3.5 ml of 5% TCA and centrifuged. To 0.5 ml of the supernatant, 3.0 ml phosphate buffer and 0.5 ml of Ellman's reagent were added and the yellow colour developed was read at 412 nm. A series of standards (4-20 μg) were treated in a similar manner along with blank. Values expressed as μg GSH/mg protein.

2.6.4. Antioxidant Enzyme Assays

Ten percent homogenate of liver was prepared by using potter-elvehjem homogenizer at 4°C in 0.15 M KCl. The homogenate was centrifuged (12,000 rpm for 45 min at 0-4°C) in Remi(C24-BL) cooling centrifuge. To remove the debris and supernatant was used for enzyme assays. Glutathione peroxidase(GPx) activity was estimated by Rotsruck(1973)and Ellman's(1959) method [36, 35] and specific activity was expressed as µg of GSH consumed/min/mg protein. Glutathione reductase(GR) activity was estimated by Pinto and Bartley (1969)method[37],activity is expressed as µmol of NADPH oxidized/min/mg protein using an extinction coefficient for NADPH of 6.22 cm-1 mmol-1. Glutathione-S-transferase(GST) activity was estimated by Habig et al. (1974) method [38] and activity was calculated using an extinction coefficient of CDNB-GSH conjugate as 9.6 mM-1 and expressed as µmoles of CDNB-GSH conjugate formed/min/mg protein. Catalase (CAT) activity was estimated by Beers and Seizer (1952) method [39]and

activity was expressed as n moles of H₂O₂ decomposed/min/mg protein. Superoxide dismutase (SOD) activity was estimated by Marklund and Marklund(1974)was adopted as followed by Soon and Tan (2002) method, activity was expressed as units/min/mg protein [40, 41]. Detailed procedures published in our previous studies [42].

Protein concentration of the supernatant was estimated by Lowry et al. (1951) using crystalline BSA standard [43].

2.6.5. Histopathology of Liver

The histological sections of the liver of rats were taken by adopting the procedure as described by Humason(1972)[44].

2.6.6. Statistical Analysis

The results were expressed as mean ± S.D. The results were analyzed using DMR test (Duncann's Multiple Range Test). P<0.05 was considered as statistically significant [45].

Table 1. Effect of curcumin and vitamin E on body weight (BW) and relative liver weight/100 gm BW of different treated groups

Name of the parameter	Group 1	Group 2	Group 3	Group 4	Group 5	Group 6	Group 7
Initial BW (0 days)							
Mean	189.16 a	195 a	200.33 a	189.56 a	196.66 a	210 a	215.66a
S.D	± 18.12	± 14.6	± 15.45	± 12.82	± 14.42	± 11.18	± 15.45
Final BW (60 days)							
Mean	280.83 a	267.5 a	262.33 a	209.16 b	257.5 a	259 a	262.5 a
S.D	± 10.05	± 11.45	± 15.06	± 15.06	± 12.88	± 15.54	± 16.77
Relative liver weight/ 100 gm BW							
Mean	2.88c	2.76 c	2.67c	4.49a	3.52 b	3.1 c	3.06 c
S.D	± 0.22	± 0.27	± 0.29	± 0.33	± 0.26	± 0.09	± 0.29

Values are mean ± S.D (n=6) (CMN-Curcumin)

Values with different superscripts with in a column are significantly different at P<0.05 (Duncan's Multiple Range Test). Group 1: Normal control; Group 2: CMN control; Group 3: CMN + vitamin E control; Group 4: CCl₄ treated alone; Group 5: CCl₄ + CMN; Group 6: CCl₄ + CMN along with vitamin E; Group 7: CCl₄ + silymarin.

Table 2.Effect of Curcumin and vitamin E on serum marker enzyme activities of different treated groups

Name of the parameter	Group 1	Group 2	Group 3	Group 4	Group 5	Group6	Group7
AST (IU/L)							
Mean	55.15d	54.89 d	55.41 d	223.68a	65.52b	60.35c	59.75c
S.D	± 0.7	± 0.82	± 0.52	± 1.39	± 0.33	± 0.53	± 0.49
ALT (IU/L)							
Mean	27.73d	27.3d	26.77d	113.97a	34.4b	29.97c	29.8c
S.D	± 0.71	± 0.56	± 0.47	± 0.59	± 0.62	± 0.54	± 0.52
ALP (IU/L)							
Mean	17.08d	17.18d	17.12d	105.27a	19.25b	18.16c	18.1c
S.D	± 0.44	± 0.34	± 0.21	± 0.33	± 0.52	± 0.44	± 0.35

Values are mean ± S.D (n=6) (CMN-Curcumin)

Values with different superscripts with in a column are significantly different at P<0.05 (Duncan's Multiple Range Test). Group 1: Normal control; Group 2: CMN control; Group 3: CMN + vitamin E control; Group 4: CCl₄ treated alone; Group 5: CCl₄ + CMN; Group 6: CCl₄ + CMN along with vitamin E; Group 7: CCl₄ + silymarin.

Table 3. Effect of Curcumin and vitamin E on antioxidant enzyme activities (μg or $\mu\text{mol}/\text{min}/\text{mg}$ protein) of different treated groups

Name of the parameter	Group 1	Group2	Group3	Group4	Group5	Group6	Group7
GPx (μg of GSH/ min/mg protein)							
Mean	12.57 a	12.71 a	12.62 a	7.15d	9.61 c	11.37b	11.63b
S.D	± 0.58	± 0.21	± 0.42	± 0.21	± 0.33	± 0.44	± 0.51
GR ($\mu\text{M}/\text{min}/\text{mg}$ protein)							
Mean	5.33a	5.34a	5.33a	2.32d	4.01 c	4.71b	4.78b
S.D	± 0.14	± 0.15	± 0.15	± 0.21	± 0.05	± 0.04	± 0.05
GST ($\mu\text{M}/\text{min}/\text{mg}$ protein)							
Mean	0.136a	0.135a	0.135a	0.053d	0.111c	0.125b	0.127b
S.D	± 0.001	± 0.0007	± 0.0009	± 0.001	± 0.0052	± 0.0032	± 0.0039
CAT (μM H ₂ O ₂ / min/mg protein)							
Mean	66.211a	66.347 a	66.371a	27.265d	60.532c	62.932b	63.189b
S.D	± 0.367	± 0.38	± 0.485	± 0.244	± 0.332	± 0.382	± 0.152
SOD (U/mg/ min/mg protein)							
Mean	12.44a	12.12a	12.36 a	4.18d	9.57c	10.97b	11.08b
S.D	± 0.25	± 0.11	± 0.29	± 0.17	± 0.22	± 0.31	± 0.22

Values are mean \pm S.D (n=6) (CMN-Curcumin)

Values with different superscripts with in a column are significantly different at $P < 0.05$ (Duncan's Multiple Range Test). Group 1: Normal control; Group 2: CMN control; Group 3: CMN + vitamin E control; Group 4: CCl₄ treated alone; Group 5: CCl₄ + CMN; Group 6: CCl₄ + CMN along with vitamin E; Group 7: CCl₄ + silymarin.

3. Results

3.1. Effect of curcumin and vitamin E on CCl₄ induced changes in the body weight, relative liver weight (KW) / 100 g body weight (BW).

Table-1 shows mean body weights and relative liver weights of rats in each group. It was observed that CCl₄ (group 4) induced rats showed significant decrease ($p < 0.05$) in the body weight whereas significant increase ($p < 0.05$) in the relative liver weight over normal control (group 1). Oral administration of CMN (group 5) and in combination with vitamin E (group 6) in rats treated with CCl₄ caused significantly ($p < 0.05$) increased the body weight and significantly decreased the relative liver weights.

3.2. Effect of Curcumin and Vitamin E on CCl₄ Induced Changes in the Liver Marker Enzymes of Different Treated Groups.

Aspartate transaminase (AST), alanine transaminase (ALT) and alkaline phosphatase (ALP) activities (Table-2) were significantly elevated in the CCl₄ treated alone ones (group 4) over normal control (group 1). Oral administration of CMN (group 5) and in combination with vitamin E (group 6) in rats treated with CCl₄ showed a significant ($p < 0.05$) reduction in the activities of serum AST, ALT and ALP.

3.3. Effect of Curcumin and Vitamin E on CCl₄ Induced Changes in the Serum Lipid Profile in Different Treated Groups

Serum total cholesterol (TC) and triglycerides (TGLs) levels were significantly increased in the CCl₄ treated

group (group 4) (Fig. 1 & 2) over normal control (group 1). Oral administration of CMN (group 5) and in combination with vitamin E (group 6) in rats treated with CCl₄ showed a significant ($p < 0.05$) reduction in the levels of serum TC and TGLs.

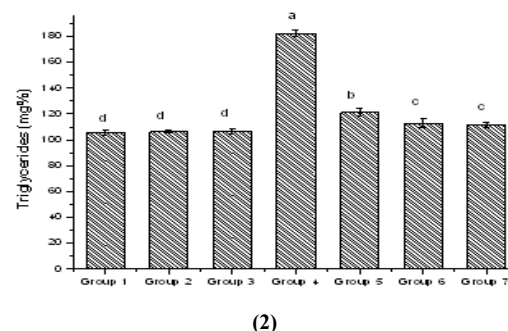
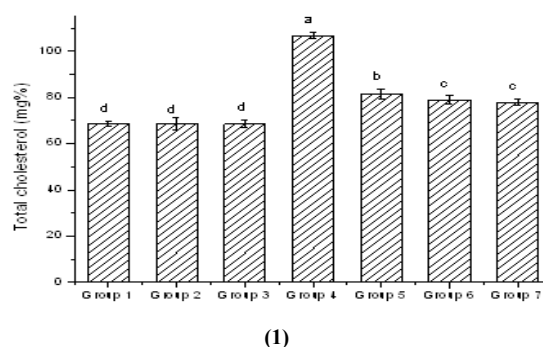


Fig. 1 & 2. Effect of curcumin and vitamin E on serum lipid profile (Fig. 1 TC and Fig. 2 TGLs) concentration of different treated groups. Each bar represents the mean \pm S.D (n=6). Bars with different alphabets differ significantly at $P < 0.05$ (Duncan's Multiple Range Test). Group I: Normal control; Group II: CMN control; Group III: CMN + vitamin E control; Group IV: CCl₄ treated alone; Group V: CCl₄ + CMN; Group VI: CCl₄ + CMN along with vitamin E; Group VII: CCl₄ + silymarin.

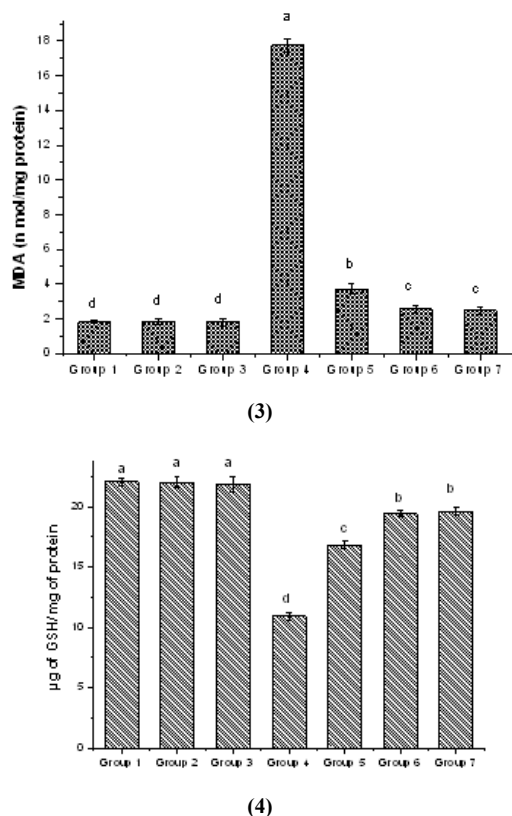


Fig. 3 & 4. Effect of curcumin and vitamin E on hepatic lipid peroxidation and glutathione (GSH) levels of different treated groups. Each bar represents the mean \pm S.D (n=6). Bars with different alphabets differ significantly at $P < 0.05$ (Duncan's Multiple Range Test). Group and treatment details are the same as described in Fig. 1 & 2.

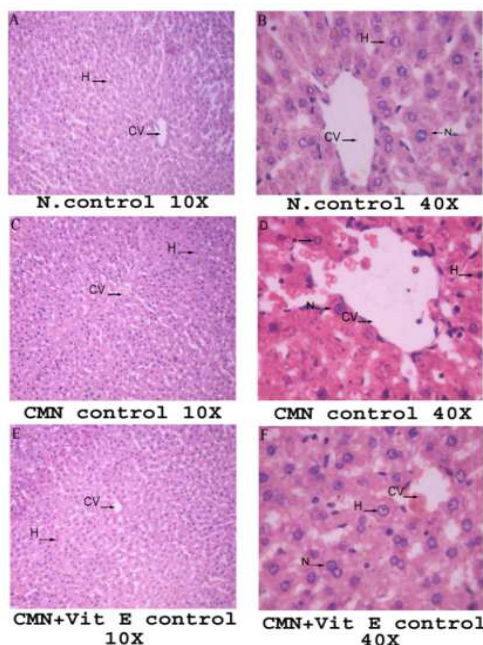


Figure 5: A (10 X) & B (40 X) Normal control (Group 1), C (10 X) & D (40 X) curcumin control (Group 2) and E (10 X) & F (40 X) curcumin and vitamin E control (Group 3) showing hepatocytes (H) with prominent nucleus (N) with central vein (CV).

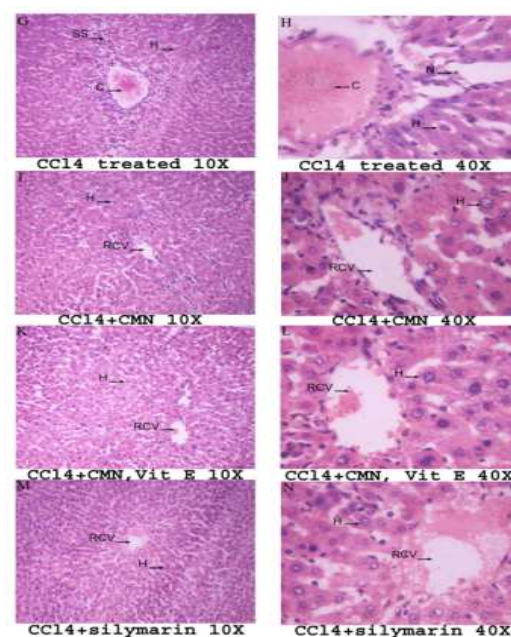


Figure 6: G (10 X) & H (40 X) CCl₄ treated (Group 4) showing hepatocytes (H) with necrotic condition and central vein with congestion (C), nucleus exfoliated condition. I (10 X) & J (40 X) CCl₄ + curcumin (Group 5) showing hepatocytes (H), nucleus still exfoliated condition. Regeneration of central vein (RCV). K (10 X) & L (40 X) CCl₄ + curcumin along with vitamin E (Group 6) showing hepatocytes (H), nucleus almost similar with control group. Regeneration of central vein (RCV). M (10 X) & N (40 X) CCl₄ + standard drug (silymarin) (Group 7) showing hepatocytes (H), nucleus almost similar with control group. Regeneration of central vein (RCV).

3.4. Effect of Curcumin and Vitamin E on CCl₄ Induced Changes in Hepatic Lipid Peroxidation in Different Treated Groups

Hepatic TBARS concentration significantly increased after 8 weeks of CCl₄ treatment (Fig. 3). Oral administration of CMN (group 5) and in combination with vitamin E (group 6) in rats treated with CCl₄ showed a significant ($p < 0.05$) reduction in the levels of hepatic TBARS concentration.

3.5. Effect of Curcumin and Vitamin E on CCl₄ Induced Changes in Hepatic GSH Content and Antioxidant Enzyme Activities (GPx, GR, GST, CAT and SOD)

Figure-3 and Table-3 had shown levels of GSH and activities of antioxidant enzymes in the liver of seven experimental groups respectively. Liver fibrosis induced by CCl₄ cause significantly decreased in the levels of hepatic GSH as well as antioxidant enzyme activities (GPx, GR, GST, CAT and SOD) as compared to normal control (group 1). Whereas, oral administration of CMN (group 5) and combination with vitamin E (group 6) in rats treated with CCl₄ showed recovery of the hepatic GSH content and activities of antioxidant enzymes.

3.6. Effect of Curcumin and Vitamin E on CCl₄ Induced Changes in Liver Histoarchitecture

The histology of the liver (Fig.5-A to F) from normal, CMN and in combination with vitamin E control animals showed normal hepatic cells with well-preserved cytoplasm, prominent nucleus, central vein and compact arrangement of hepatocytes. In contrast to this, liver sections from the rats treated with CCl₄ alone (Group 4) showed (Fig.6-G&H) massive changes throughout the lobules, with fatty accumulations, cellular vacuolization, and centrilobular necrosis. Congestion of the central vein with haemorrhagic condition. CMN (group 5) (Fig.6- I & J) treated animals showed mild central venous congestion and mild fatty vacuolation. The sections of liver taken from the animals treated with curcumin and vitamin E (group 6) (Fig. 6- K & L) showed the hepatic architecture, which was almost similar to that of normal control.

4. Discussion

The Present study was conducted to evaluate the combined effect of the CMN and vitamin E against CCl₄-induced hepatic disorders in rat. Chronic hepatic injury by carbon tetrachloride is a well-established animal model of liver fibrosis. Reactive oxygen species and oxidative stress have been shown to play an important role in the etiopathogenesis of the hepatic fibrotic changes, and antioxidant treatment *in vivo* seems to be effective in preventing or reducing chronic liver damage and fibrosis [46]. In our study, treatment with CCl₄ resulted in a significant decrease in body weight as well as significant increase in relative liver weight and these results were in agreement with those reported in the previous literature [47].

Serum hepatobiliary enzymes such as AST, ALT and ALP are present in high concentrations in the liver under normal conditions. When there is hepatocyte necrosis or membrane damage, these enzymes will be released into the circulation, as indicated by elevated serum enzyme levels [48]. In the present study, the elevated levels of all these marker enzymes observed in CCl₄-treated rats indicate liver damage induced by hepatotoxins. Treatment of CMN and with or without vitamin E to CCl₄-induced rats ameliorated the toxic effects of CCl₄ and the above markers restored towards the normal level. This effect may be free radical scavenging activity of CMN and results obtained in this study are in agreement with earlier findings [49-51].

In this study CCl₄ treated rats showed elevated levels of serum TC and TGLs. CCl₄ increases the synthesis of fatty acids and triglycerides from acetate. This could be due to the transport of acetate into the liver cell, resulting in increased substrate (acetate) availability. In CCl₄ toxicity, the synthesis of cholesterol is also increased [52]. The significant reduction in the concentration of TC and TGLs in the serum of CCl₄ + CMN with or without vitamin E administered rats. This could be due to CMN possesses hypocholesterolemic action and this could be due to a decrease in absorption of cholesterol or an increase in HDL

cholesterol [53]. This is also evidenced by recent studies [54].

Hepatic malondialdehyde(MDA) levels were significantly increased in CCl₄ treated group, showing an increased oxidative stress compared to control group. Increased oxidative stress has been attributed to the formation of reactive metabolites due to biotransformation by CYP2E1. Once formed, free radicals trigger a cascade of reactions that culminate in lipoperoxidation [55, 56]. The significant decline in the concentration of these constituents in the liver of CCl₄ + CMN with or without vitamin E administered rats indicates anti-lipid peroxidative effects. Recent studies suggest that curcumin inhibits CYP2E1 activity [57], thus limiting ROS production from microsomes, and activates NF-E2-related factor 2 (Nrf2) translocation to the nucleus, where it activates the expression of antioxidant enzymes [58, 59]. In this study it is also evidenced by CMN and vitamin E treatment significantly restoring the antioxidant enzymes (GPx, GST, GR, SOD and CAT) activities as well as non-enzymatic antioxidant GSH concentration in the liver. However, CMN along with vitamin E treatment showed significant protection than CMN alone.

Histopathological studies provided supportive evidence for biochemical analysis. In this study treatment with CCl₄ for 8 weeks showed marked disruption of the structure of hepatocytes. Therapy of CMN and with or without vitamin E showed marked regenerative hepatocytes, only slightly affected normal architecture of hepatocyte cords with a few areas of discontinuity. In contrary histological observations depicts that CMN along with vitamin E showed significant recovery over CMN alone treated ones.

In our studies combined supplementation of vitamin E and CMN to CCl₄-treated rats was found to ameliorate the hepatic toxicity. Therefore, it is assumed that administration of both vitamin E and curcumin co-operatively act on ROS induced by CCl₄, CMN alone also shown positive effect, however it is less effective compared with CMN plus vitamin E. No reports were available on combined effects of CMN and vitamin E on CCl₄ hepatotoxicity. However few reports are available to support of this view, our earlier findings suggested that CMN combination with vitamin E may be considered as potentially combating oxidative stress and nephrotoxicity induced by CCl₄ [42] and other study by Jena and Chainy(2011) has reported that CMN and vitamin E effectively ameliorates the L-Thyroxine(T₄) induced oxidative stress in renal cortex of male rats, whereas CMN alone unable to do so [60].

Conclusion: Our study suggests that combined administration of curcumin and vitamin E may be considered as potentially combating oxidative stress and liver toxicity induced by CCl₄.

Conflict of interest

The authors declare that we have no conflict of interest.

References

- [1] Pinzani M, Rombouts K. Liver fibrosis: from the bench to clinical targets. *Dig Liver Dis* 2004; 36: 231-242.
- [2] Wallace K, Burt AD, Wright MC. Liver fibrosis. *Biochem J* 2008; 411:1-18.
- [3] Milani S, Herbst H, Schuppan D, Grappone C, Heinrichs OE. Cellular sources of extracellular matrix proteins in normal and fibrotic liver. Studies of gene expression by *in situ* hybridization. *J Hepatol* 1995; 22: 71-76.
- [4] Bissell DM. Hepatic fibrosis as wound repair: a progress report. *J Gastroenterol* 1998; 33: 295-302.
- [5] Giannelli G, Quaranta V, Antonaci S. Tissue remodelling in liver diseases. *HistolHistopathol* 2003; 18: 1267-1274.
- [6] Bataller R, Brenner DA. Liver fibrosis. *J Clin Invest* 2005; 115: 209-218.
- [7] Tipoe GL, Leung TM, Liong EC, Lau TY, Fung ML, Nanji AA. Epigallocatechin-3- gallate (EGCG) reduces liver inflammation, oxidative stress and fibrosis in carbontetrachloride (CCl₄) induced liver injury in mice. *Toxicology* 2010; 273 (1-3): 45-52.
- [8] Loguercio C, Federico A. Oxidative stress in viral and alcoholic hepatitis. *Free RadicBiol Med* 2003; 34: 1-10.
- [9] Vitaglione P, Morisco F, Caporaso N, Fogliano V. Dietary antioxidant compounds and liver health. *Crit Rev Food SciNutr* 2004; 44: 575-586.
- [10] Kodavanti PR, Joshi UM, Young YA, Meydrech EF, Mehendale HM. Protection of hepatotoxic and lethal effects of CCl₄ by partial hepatectomy. *ToxicoloPatholo* 1989; 17: 494-505.
- [11] Demirdag K, Bakcecioglu IH, Ozercan IH, Ozden M, Yilmaz S, Kalkan A. Role of L-carnitine in the prevention of acute liver damage induced by carbon tetrachloride in rats. *J GastroenterolHepatol* 2004; 19: 333-338.
- [12] Sheweita SA, Abd EI-Gabar M, Bastawy M. Carbon tetrachloride-induced changes in the activity of phase II drug-metabolizing enzyme in the liver of male rats: Role of antioxidants. *Toxicology* 2001; 165: 217-224.
- [13] Srivastava A, Shivanandappa T. Differential cholinesterase inhibition in the rat brain regions by dichlorvos and protective effect of *Decalepishamiltonii* roots. *Neurotoxicology* 2011; 32(6): 931-934.
- [14] Shahani S. Evaluation of hepatoprotective efficacy of APCL-a polyherbal formulation *in vivo* in rats. *Indian Drugs* 1998; 36: 628-631.
- [15] Ozsoy N, Can A, Yanardag R, Akev N. Antioxidant activity of *Smilax excelsa* L. leaf extracts. *Food Chem* 2008; 110: 571-83.
- [16] Sundaram R, Mitra SK. Antioxidant activity of ethyl acetate soluble fraction of *Acacia arabica* bark in rats. *Indian J Pharmacol* 2007; 39: 33-38.
- [17] Buescher R, Yang L. Turmeric. In: Lauro GJ and Francis FJ editors. Natural food colorants. New York: Marcel Dekker; 2000, p. 205-226.
- [18] Venkatesan P, Rao MNA. Structure-activity relationships for the inhibition of lipid peroxidation and the scavenging of free radicals by synthetic symmetrical curcumin analogues. *J Pharm Pharmacol* 2000; 52: 1123-1128.
- [19] Naidu KA, Thippeswamy NB. Inhibition of human low density lipoprotein oxidation by active principle from spices. *Mol Cell Biochem* 2002; 229: 19-23.
- [20] Rukkumani R, Balasubashini MS, Viswanathan P, Menon VP. Comparative effects of curcumin and photo-irradiated curcumin on alcohol and polyunsaturated fatty acid-induced hyper lipidemia. *Pharmacol Res* 2002; 46(3): 257-264.
- [21] Priyadarsini KI, Maity DK, Naik GH, Kumar MS, Unnikrishnan MK, Satav JG, et al., Role of phenolic O-H and methylene hydrogen on the free radical reaction and antioxidant activity of curcumin. *Free RadicBiol Med* 2003; 35: 475-484.
- [22] Daniel S, Limson JL, Dairam A, Watkins GM, Daya S. Through metal binding, curcumin protects against lead and cadmium-induced lipid peroxidation in rat brain homogenates and against lead-induced tissue damage in rat brain. *J InorgBiochem* 2004; 98: 266-275.
- [23] Chainani-Wu N. Safety and anti-inflammatory activity of curcumin: a component of turmeric (*Curcumin longa*). *J Altern Complement Med* 2003; 9: 161-168.
- [24] Lin JK, Lin-Shia SY. Mechanisms of cancer chemoprevention by curcumin. Proceedings of the National Science Council, Republic of China: Part B. *Life Sciences* 2001; 25: 59-66.
- [25] Shukla Y, Aroro A, Taneja P. Antimutagenic potential of curcumin on chromosomal aberrations in Wistar rats. *Mutat Res* 2002; 515: 197-202.
- [26] Aqqarwal BB, Kumar A, Bharti AC. Anticancer potential of curcumin: preclinical and clinical studies. *Anticancer Res* 2003; 23: 363-398.
- [27] Mazumder A, Raghavan K, Weinstein J, Kohn KW, Pommier Y. Inhibition of human immunodeficiency virus type-1 integrase by curcumin. *BiochemPharmacol* 1995; 49: 1165-1170.
- [28] Arhoghro EM, Ekpo KE, Anosike EO, Ibeh GO. Effect of aqueous extract of bitter leaf (*Vernonia Amygdalina Del*) on carbon tetrachloride (CCl₄) induced liver damage in albino Wistar rats. *Eur J Sci Res* 2009; 26: 122-130.
- [29] KhadeerAhamed MB, Krishna V, Dandin CJ. *In vitro* antioxidant and *in vivo* prophylactic effects of two γ -lactones isolated from *Grewia tiliaefolia* against hepatotoxicity in carbon tetrachloride intoxicated rats. *Eur J Pharmacol* 2010; 631(1-3): 42-52.
- [30] Mc Lean EK, McLean AEM, Sutton PM. Improved method for producing liver cirrhosis of rats by stimulus administration of carbon tetrachloride and pontobarbitone. *Br J Exp Path* 1991; 57: 523.
- [31] Roy CK, Kamath JV, Asad M. Hepatoprotective activity of *Psidium guajava* Linn. leaf extract. *Indian J Exp Biol* 2006; 44(4): 305-311.
- [32] Sreepriya M, Bali G. Effects of Administration of embelin and curcumin on lipid peroxidation, hepatic glutathione antioxidant defense and hematopoietic system during N-

- nitrosodiethylamine/phenobarbital-induced hepato carcinogenesis in wistar rats. *Mol Cell Biochem* 2006; 284(1-2): 49-55.
- [33] Karima M, Moawad. Possible prophylactic effects of vitamin E or lycopene treatment on renal toxicity induced by CCl₄ administration in albino rats. *World Journal of Zoology* 2007; 2 (2): 19-28.
- [34] Utley HG, Berheim F, Hochstein P. Effect of sulphhydryl reagents on peroxidation of microsomes. *Arch BiochemBiophys* 1967; 118: 29 -32.
- [35] Ellman G. Tissue sulphhydryl. *Arch BiochemBiophys* 1959; 82: 70-77
- [36] Rotruck JT, Pope AL, Ganther HE, Swanson AB, Hafeman DC, Hoekstra WG. Selenium: biochemical roles as a component of glutathione peroxidase. *Science* 1973; 179 (4073): 588-590.
- [37] Pinto RE, Bartley. The effect of age and sex on glutathione reductase and glutathione peroxidase activities and on aerobic GSH oxidation in rat liver homogenates. *Biochem J* 1959; 112: 109-115.
- [38] Habig WH, Pabst MJ, Jakoby WB. Glutathione-S-transferases. The first enzymatic step in mercapturic acid formation. *J BiolChem* 1974; 246: 7130-7139.
- [39] Beer RF, Sizer IW. A spectrophotometric method for measuring the breakdown of hydrogen peroxide by catalase. *J BiolChem* 1952; 195: 133-140.
- [40] Marklund SL, Marklund G. Involvement of the superoxide anion radical in the autoxidation of pyrogallol and a convenient assay for superoxide dismutase. *Eur J Biochem* 1974; 47: 469-474.
- [41] Soon YY, Tan BK. Evaluation of the hypoglycemic and antioxidant activities of *Morinda officinalis* in streptozotocin-induced diabetic rats. *Singapore Med J* 2002; 43(2): 77-85.
- [42] Venkatanarayana G, Sudhakara G, Sivajyothi P, Indira P. Protective effects of curcumin and vitamin E on Carbon tetrachloride-induced nephrotoxicity in rats. *EXCLI Journal* 2012; 11: 641-650
- [43] Lowry OH, Rosenbrough NJ, Farr AL, Randall RJ. Protein measurement with the Folin Phenol Reagent. *J BiolChem* 1951; 193: 265-275.
- [44] Humason GL. Animal tissue techniques 1972 3rd ed. San Francisco, CA: Freeman
- [45] Duncan DB. Multiple range and multiple F tests. *Biometrics* 1955; 11:1-42.
- [46] Wang Y, Cheng M, Zhang B, Nie F, Jiang H. Dietary supplementation of blueberry juice enhances hepatic expression of metallothionein and attenuates liver fibrosis in rats. *PLoS One* 2013; 8[3]: e58659.
- [47] Soni B, Visavadiya NP, Madamwar D. Ameliorative action of cyanobacterial phycoerythrin on CCl₄-induced toxicity in rats. *Toxicology* 2008; 248(1): 59-65.
- [48] Drotman RB, Lawhorn GT. Serum enzymes as indicators of chemically induced liver damage. *Drug ChemToxicol* 1978; 1(2):163-171.
- [49] Parola M, Robino G. Oxidative stress-related molecules and liver fibrosis. *J Hepatol* 2001; 35(2): 297-306.
- [50] Acharya UR, Mishra M, Mishra I, Tripathy RR. Potential role of vitamins in chromium induced spermatogenesis in Swiss mice. *EnvironToxicolPharmacol* 2004; 15(2-3): 53-59.
- [51] Naik SR, Thakare VN, Patil SR. Protective effect of curcumin on experimentally induced inflammation, hepatotoxicity and cardiotoxicity in rats: Evidence of its antioxidant property. *ExpToxicolPathol* 2011; 63(5): 419-431.
- [52] Boll M, Weber LW, Becker E, Stampfl A. Hepatocyte damage induced by carbon tetrachloride: inhibited lipoprotein secretion and changed lipoprotein composition *Z Naturforsch C* 2001; 56(3-4): 283-290.
- [53] Kamalakkannan N, Rukkumani R, Varma PS, Viswanathan P, Rajasekharan KN, Menon VP. Comparative effects of curcumin and an analogue of curcumin in carbon tetrachloride-induced hepatotoxicity in rats. *Basic ClinPharmacolToxicol* 2005; 97(1): 15-21.
- [54] Shao W, Yu Z, Chiang Y, Yang Y, Chai T, et al. Curcumin prevents high fat diet induced insulin resistance and obesity via attenuating lipogenesis in liver and inflammatory pathway in adipocytes. *PLoS One* 2012; 7(1): e28784.
- [55] Pereira FG, Ferreira C, Schwengber A, Marroni C, Zettler C, Marroni N. Role of N-acetylcysteine on fibrosis and oxidative stress in cirrhotic rats. *ArqGastroenterol* 2008; 45 (2): 156-162.
- [56] Nissar AU, Farrukh MR, Kaiser PJ, Rafiq RA, Afnan Q, Bhushan S, Adil HS, Subhash BC, Tasduq SA. Effect of N-acetylcysteine (NAC), an organosulfur compound from *Allium* plants, on experimentally induced hepatic prefibrogenic events in wistar rat. *Phytomedicine* 2013 (Article in press).
- [57] Guangwei X, Rongzhu L, Wenrong X, Suhua W, Xiaowu Z, et al. Curcumin pretreatment protects against acute acrylonitrile-induced oxidative damage in rats. *Toxicology* 2010; 267 (1-3): 140-146.
- [58] Farombi EO, Shrotriya S, Na HK, Kim SH, Surh YJ. Curcumin attenuates dimethylnitrosamine-induced liver injury in rats through Nrf2-mediated induction of heme oxygenase-1. *Food ChemToxicol* 2008; 46(4) 1279-1287.
- [59] Charoensuk L, Pinlaor P, Prakobwong S, Hiraku Y, Laothong U et al., Curcumin induces a nuclear factor-erythroid 2-related factor 2-driven response against oxidative and nitrate stress after praziquantel treatment in liver fluke-infected hamsters. *Int J Parasitol* 2011; 41(6): 615-626.
- [60] Jena S, Chainy GB. Regulation of expression of antioxidant enzymes by vitamin E and curcumin in L-thyroxine-induced oxidative stress in rat renal cortex. *MolBiol Rep* 2011; 38(2):1047-54.