

# High Fat Diet Alters the Expression of M Cells and Claudin 4 in the Peyer's Patches of Rats

**Auni Aqilah Zainal Abidin, Effat Omar, Mohammed Nasimul Islam, Jesmine Khan**

Faculty of Medicine, Universiti Teknologi MARA (UiTM) Sungai Buloh Campus, Selangor, Malaysia

## Email address:

[auniaqilahzainalabidin@yahoo.com](mailto:auniaqilahzainalabidin@yahoo.com) (A. A. Z. Abidin), [effat2011.eo@gmail.com](mailto:effat2011.eo@gmail.com) (E. Omar), [nasimul@salam.uitm.edu.my](mailto:nasimul@salam.uitm.edu.my) (M. N. Islam), [jesminek@salam.uitm.edu.my](mailto:jesminek@salam.uitm.edu.my) (J. Khan)

## To cite this article:

Auni Aqilah Zainal Abidin, Effat Omar, Mohammed Nasimul Islam, Jesmine Khan. High Fat Diet Alters the Expression of M Cells and Claudin 4 in the Peyer's Patches of Rats. *American Journal of Clinical and Experimental Medicine*. Vol. 3, No. 5, 2015, pp. 283-287. doi: 10.11648/j.ajcem.20150305.25

---

**Abstract:** Prevalence of obesity is increasing worldwide. One of the major risk factors for obesity is consumption of high fat diet (HFD). Gastrointestinal tract (GIT) is the first organ where HFD comes in contact with the body. But, the effect of HFD on the GIT especially the GIT barrier is not investigated properly. M cells are present in the Follicle associated epithelium (FAE) of Peyer's patches (PP) of GIT and are important component of intestinal barrier. Healthy and adequate number of M cells is important for an effective intestinal barrier. Intestinal tight junction protein Claudin 4, situated in between the enterocytes of Peyer's patches (PP), regulates the permeability through the intestinal mucosa. Reduced Claudin 4 is responsible for increased paracellular transport of antigenic materials. Calprotectin is an inflammatory marker secreted by neutrophils during inflammation. Its level is considered specific for intestinal inflammation. The objectives of this study were to investigate the expressions of M cells and Claudin 4 in the PP and to determine the fecal calprotectin level (FCP) of male Wistar rats fed HFD. Four weeks old, twenty male Wistar rats were divided into chow (n=10) and HFD (n=10) groups. After 6 weeks of consuming the respective diets, stool and GIT segments containing PP were collected. After tissue processing, tissues were sectioned into 3 micrometer thickness and were taken on poly-L-lysine coated glass slides. Immunohistochemical staining was done by rat M cell specific CK-8 antibody and anti-Claudin 4 antibody. Scoring was done to calculate the average number of M cells and Claudin 4 in the PP of both groups under light microscope. FCP were measured using a commercial enzyme linked immunoassay (ELISA) kit. Statistical analysis was done by chi-square test and independent T-test. Data are presented as mean  $\pm$  SD. A p value  $<0.05$  was considered as significant. The number of M cells in the PP was significantly higher in HFD group as compared to the control (p = 0.004). The expression of Claudin 4 in the PP was significantly decreased in HFD group as compared to the control (p = 0.018). The fecal calprotectin level in HFD group was significantly higher compared to the control (p = 0.016). HFD consumption for 6 weeks leads to a higher number of M cell and reduced the expression of Claudin 4 in the intestinal Peyer's patches of male Wistar rats which might be due to GI inflammation.

**Keywords:** High Fat Diet, M Cells, Claudin 4, Intestinal Barrier, Peyer's Patches, Fecal Calprotectin

---

## 1. Introduction

Prevalence of obesity is on the rise worldwide. Consumption of high fat diet (HFD) is considered to be one of the important causes of obesity. Besides disrupting the metabolic activity of the body, HFD may cause alteration of the structure and function of various organs in the body [1, 2]. HFD is also reported to be the cause for many diseases such as arthritis, cancer, cardiovascular disease, diabetes, hypertension, stroke and other diseases [1, 3, 4].

Gastrointestinal tract (GIT) is the first organ, where the

HFD come into contact with the body. Before causing effects on other organs it might have local effects in the GIT first, which will ultimately cause dysfunction of other organs. Although many researches are conducted to observe the effect of HFD on different organs, but the effect of HFD on the GIT itself, has received minimum attention.

The main function of GI mucosa is digestion and absorption of food. In addition to food, GI lumen is being constantly exposed to various types of antigenic materials. GI mucosa functions as a crucial barrier to toxic and harmful antigenic materials present in the GI lumen and protects an

individual from various antigenic and inflammatory reactions.

Peyer's patches (PP), located in the lamina propria of the mucosa of the ileum. M cells, which are located within the follicle-associated epithelium (FAE) covering the PP and TJP of FAE which are situated in between the epithelium of FAE of PP are important component of intestinal barrier (IB). Disruption of any of the components of IB might have potential harmful effects on the body.

M cells are specialized epithelium cells which transport antigenic materials directly from the GI lumen and deliver it to the antigen-presenting cells which are located in unique pocket-like structure on their basolateral sides [5].

Intestinal tight junction proteins (TJP) such as claudins and occludin are situated in between the enterocytes of the villi and regulate the permeability through intestinal barrier. Disruptions of these TJP are thought to be associated with increased paracellular transport of antigenic materials [6,7,8]. Recently, in addition to M cells, FAE TJPs also regulate the entry of antigens in the PP. Unique profiles of claudin4 expression were noted in the tight junctions of the FAE. They are proposed to be the factors favoring the uptake of antigens by the FAE [9].

Calprotectin is a protein secreted by neutrophils, monocytes and macrophages during inflammatory processes. Fecal calprotectin level is considered specific for intestinal inflammation. Calprotectin may be detected in the stool in case of bowel inflammation. An increased Calprotectin concentration in stool is the direct consequence of neutrophil degranulation due to mucosal damage [10].

## 2. Materials and Methods

### 2.1. Animal Experiments

Four weeks old twenty male Wistar rats were obtained from Laboratory Animal Facility and Management (LAFAM), UiTM Puncak Alam. Rats were acclimatized for 7 days to the standard conditions in the laboratory as follows: room temperature 24°C; a 12 hour light and dark cycle and exchange of room air 12 times per day. After the acclimatization period, rats were divided into 2 groups, rat normal chow diet (n=10) and HFD (n=10) groups. HFD was purchased from Research Diets, USA. 45% of the calories of HFD derived from fat. All the rats were given free access to drinking water. Rats received their respective diets for 6 weeks.

### 2.2. Laparotomy and Tissue Preparation

Rats were fasted overnight at the end of 6 weeks. On the day of sacrifice, rats were anesthetized with intra muscular injection of phenobarbitol and laparotomy was performed. After collection of samples, rats were euthanized by exsanguination by cardiac puncture. Rat's stools were collected from each cage. Stools were kept in -80° until further analysis.

After laparotomy, small intestinal segments containing PP were aseptically collected in bottles containing 10% formalin

and were kept for 24 hours and then were processed in Tissue Processor. Tissue processing procedures were done using an open system automated tissue processor Tissue-Tek VIP. It took 24 hours to complete and the temperature was maintained around 60°C. The tissues were embedded in cassettes to produced tissue blocks, trimmed into 15 micrometer thickness and then sectioned into 3 micrometer thickness using microtome, fishing in water bath at 42°C before taken on Poly-L-lysine coated glass slides (Muto Co, Japan), air dried at room temperature (21-22°C) and were used for immunohistochemistry, observation and image analysis.

### 2.3. Immunohistochemistry

Immunohistochemical staining (IHC) for M cell was done using M cell specific Anti-Cytokeratin 8 antibody [M20] (Dako ARK Animal Research Kit, K3954/K3955. IHC staining for Claudin 4 was done using Dako Rabbit Envision Kit, K401011 and the antibody used was rabbit polyclonal Anti-Claudin 4 antibody from (abcam ab15104). Image analysis was done for IHC slides using light microscope under 10X and 40X magnification.

### 2.4. Immunohistochemical Grading

To determine the expression of the M cells and Claudin 4, grading technique was done using Sydney System based on previous studies by Dixon et al (1996) [11]. Macroscopic assessment of the grade was scored semi quantitatively according to a previously reported scoring system as absent (0), mild (1), moderate (2) or severe (3).

### 2.5. Fecal Calprotectin Level

Stool pellet samples obtained for FCP measurement were collected in disposable plastic containers and stored within 6 hours at -80°C until analysis. FCP were measured using a commercial enzyme linked immunoassay kit (ELISA) (S1008A8/S100A9 ELISA KIT, Immundiagnostik, Bensheim, Germany) following the manufacturer's instruction. The FCP results were expressed in mg of calprotectin per kilogram of wet feces and were plotted using 4 parameter algorithm. Any differences between the values of calprotectin in control and HFD rats were analyzed.

### 2.6. Statistical Analysis

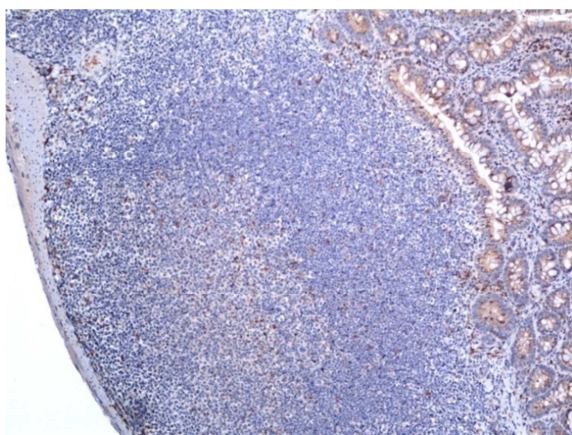
Statistical analysis was performed using Special Package of Social Sciences (SPSS) version 20.0 in order to analyze the data. Data were expressed as mean  $\pm$  SD. Statistical comparison was done by Student's independent t test. Differences were considered significant at a *p* value of <0.05. Chi-square test was used to analyze the categorical data and determine the expression of M cells and Claudin 4 in intestinal PPs of rats fed high fat diet.

## 3. Results

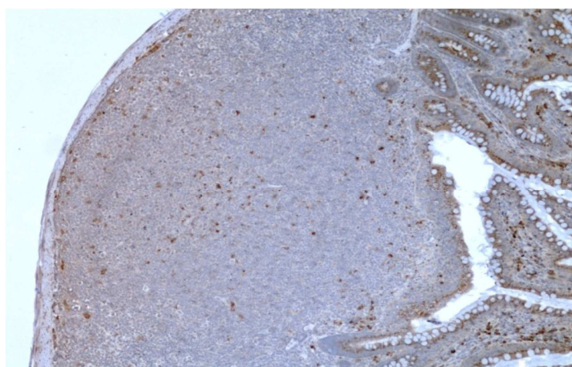
Scoring of the expression of M cells in the FAE of Peyer's patches was significantly higher in HFD group as compared

to the control group ( $2.3 \pm 0.67$  vs  $1.125 \pm 0.35$ ,  $p = 0.018$ ). Scoring of the expression of Claudin 4 in HFD group was significantly decreased as compared to the control group ( $1.6 \pm 0.67$  vs  $2.1 \pm 0.58$ ,  $p = 0.018$ ).

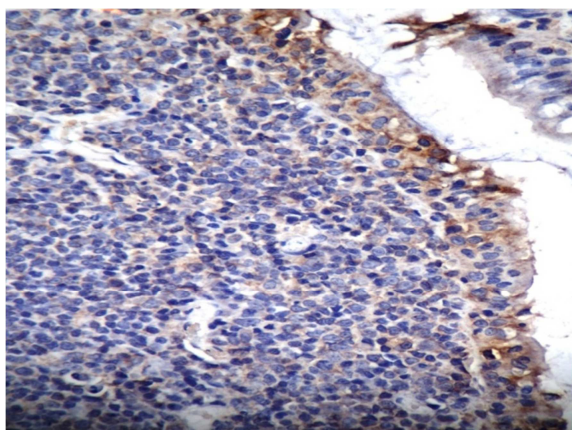
There was no sign of inflammation of the intestinal mucosa in naked eye. Stool consistency was normal throughout the experimental period. But Fecal calprotectin level, a marker of intestinal inflammation, was significantly higher in HFD group as compared to the control group ( $49.05 \pm 1.17$  ng/ml vs  $40.17 \pm 4.08$  ng/ml,  $p = 0.016$ ).



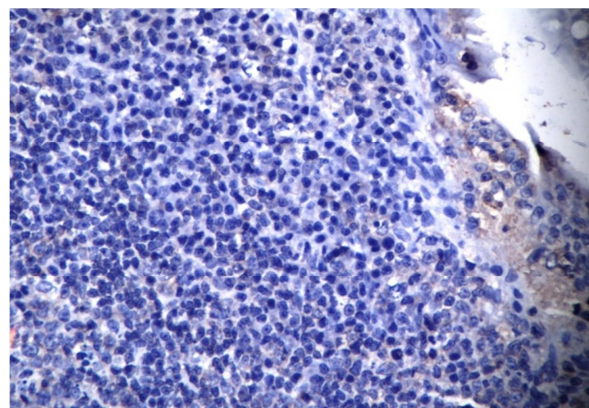
**Figure 1.** The expression of M cells in the PP stained with light brown color from the control rat under 10X magnification.



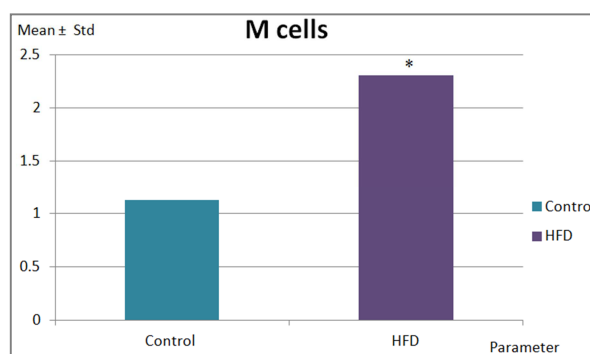
**Figure 2.** The expression of M cells in the PP stained with dark brown color from the HFD rat under 10X magnification.



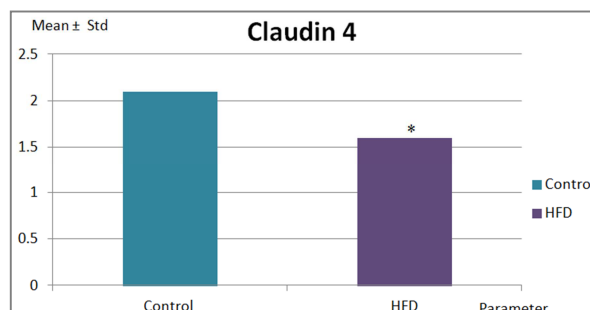
**Figure 3.** The expression of Claudin 4 in the PP stained with dark brown colour from the control rat under 40X magnification.



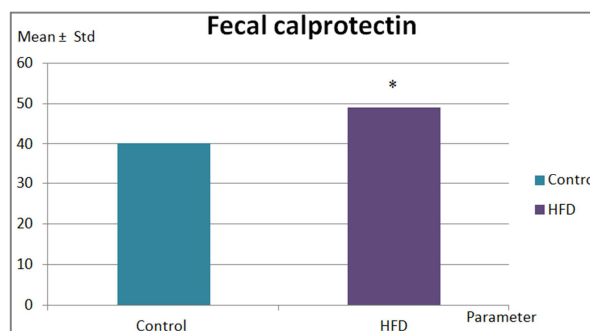
**Figure 4.** The expression of Claudin 4 in the PP stained with light brown colour from the HFD rat under 40X magnification.



**Figure 5.** The graph above shows the expressions of M cells in the peyer's patches of control and HFD rats. Scoring of the expression of M cells in the PP in HFD rats was significantly higher as compared to the control rats.



**Figure 6.** The graph above shows the expressions of Claudin 4 in the peyer's patches of control and HFD rats. Scoring for the expression of Claudin 4 in the PP in HFD rats was significantly lower as compared to the control rats.



**Figure 7.** The graph above shows the level of fecal calprotectin in both control and high fat diet rats. Fecal calprotectin in HFD rats was significantly higher as compared to the control rats.

## 4. Discussion

In our previous study, we observed significantly higher uptake of fluorescent particles by the PP of rats fed HFD for 6 weeks [12]. But the underlying mechanism of this finding is unknown. Hence, we proceeded with the present study to unearth the mechanism for our previous finding.

In the present study, rats fed HFD for 6 weeks resulted in increased M cell expression in the FAE of PP. M cells are special type of enterocytes in the PP, which has selective antigen uptake capacity. Previous study has reported that FAE of PP has the ability to form more M cells in adverse situations. Enterocytes can be converted to M cells as a response to local signal stimulations such as in contact with lymphocytes and chemokines or cytokines. Enterocytes in the presence of an immunological or inflammatory stimuli converts into M cells, changing their surfaces to allow adherence and phagocytosis of antigens. Another study has shown that co-culture of PP lymphocytes with Caco-2 cells induced the formation of M cells and alters the transport of microorganisms, which suggests the possibility of the presence of soluble mediators for conversion of enterocytes into M cells [13]. HFD intake has been reported to be associated with proinflammatory and inflammatory conditions [14]. One study has shown that inflammation in the rat ileum was associated with increase in the number of M cells [15].

In the present study, although there were no signs of inflammation macroscopically but fecal calprotectin level, a marker of intestinal inflammation was significantly elevated in HFD group. Our data suggests that there was subclinical inflammation in the GIT after HFD consumption for 6 weeks. This inflammation might be responsible for the changes of expression of M cells.

We also observed reduced expression of Claudin 4 in the FAE of PP of rats fed HFD. Changes in the expression and distribution of claudin lead to discontinuous TJP and barrier dysfunction [7]. Previous studies has reported HFD induced modulation of the expression of tight junction proteins such as Claudin 1 and occludin, in the enterocytes of villi but until now, no one has investigated the changes of the expression of TJP of PP, which is also an important gateway for the antigenic materials from the GI lumen [14,16]. Normal distribution and expression of TJPs are necessary to prevent higher IP and regulate different immunologic reactions in our body.

## 5. Conclusion

From our findings we conclude that HFD for 6 weeks caused higher expression of M cells and reduced expression of Claudin 4 in rats, which might be responsible for the higher uptake of particles by the PP. Underlying causes of these changes, might be due to intestinal inflammation.

Further research is warranted to find out the definitive measures to prevent the altered expression of M cell and Claudin 4 to overcome HFD induced intestinal and extra intestinal changes in the body.

## Acknowledgments

This research was funded by FRGS grant, Ministry of Higher Education (MOHE), Malaysia [600-RMI/FRGS 5 /3(111/2013)]. The authors also wish to thank Institute of Medical and Molecular Biotechnology (IMMB) for providing the laboratory facilities for our research. Ethical clearance was approved by the Animal Care and Use committee (ACUC), UiTM, Sungai Buloh Campus, Malaysia.

## References

- [1] Rindler PM, Plafker SM, Szweda LI, Kinter M. High dietary fat selectively increases catalase expression within cardiac mitochondria. *J Biol Chem*. 2012 Nov 30. [Epub ahead of print]
- [2] Ge, J., Wang, J., Xue, D., Zhu, Z., Chen, Z., Li, X., Su, D., and Du, J. (2013). Why does a high-fat diet induce preeclampsia-like symptoms in pregnant rats. *Neural Regen. Res.* 8, 1872–1880.
- [3] Namavar MR, Raminfar S, Jahromi ZV, Azari H. Effects of high-fat diet on the numerical density and number of neuronal cells and the volume of the mouse hypothalamus: a stereological study. *Anat Cell Biol*. 2012 Sep; 45(3): 178-84. doi: 10.5115/acb.2012.45.3.178. Epub 2012 Sep 30.
- [4] Luzzo KM, Wang Q, Purcell SH, Chi M, Jimenez PT, Grindler N, Schedl T, Moley KH. High fat diet induced developmental defects in the mouse: oocyte meiotic aneuploidy and fetal growth retardation/brain defects. *PLoSOne*. 2012; 7(11): e49217. doi: 10.1371/journal.pone.0049217. Epub 2012 Nov 12.
- [5] Miller, H., Zhang, J., KuoLee, R., Patel, G.B., and Chen, W. (2007b). Intestinal M cells: The fallible sentinels? *World J. Gastroenterol*. *WJG* 13, 1477–1486.
- [6] Franke, W.W. (2009). *Discovering the Molecular Components of Intercellular Junctions—A Historical View*. Cold Spring Harb. Perspect. Biol. 1.
- [7] Zeissig, S., Bürgel, N., Günzel, D., Richter, J., Mankertz, J., Wahnschaffe, U., Kroesen, A.J., Zeitz, M., Fromm, M., and Schulzke, J. (2007). Changes in expression and distribution of claudin 2, 5 and 8 lead to discontinuous tight junctions and barrier dysfunction in active Crohn's disease. *Gut* 56, 61–72.
- [8] Bischoff, S.C., Barbara, G., Buurman, W., Ockhuizen, T., Schulzke, J.-D., Serino, M., Tilg, H., Watson, A., and Wells, J.M. (2014). Intestinal permeability – a new target for disease prevention and therapy. *BMC Gastroenterol*. 14.
- [9] Tamagawa H, Takahashi I, Furuse M, Yoshitake-Kitano Y, Tsukita S, Ito T, Matsuda H, Kiyono H. Characteristics of claudin expression in follicle-associated epithelium of Peyer's patches: preferential localization of claudin-4 at the apex of the dome region. *Lab Invest*. 2003 Jul; 83(7): 1045-53.
- [10] Erbayrak, M., Turkay, C., Eraslan, E., Cetinkaya, H., Kasapoglu, B., and Bektas, M. (2009). The role of fecal calprotectin in investigating inflammatory bowel diseases. *Clin. São Paulo Braz*. 64, 421–425.
- [11] Dixon et al (1996). Classification and grading of gastritis. The updated Sydney System. International Workshop on the Histopathology of Gastritis, Houston 1994.

- [12] Jesmine Khan, Mariam Mohamad, Gabriele Ruth Anisah Froemming, Mohammed Nasimul Islam. High Fat Diet Increases Uptake of Particles by the Peyer's Patches of Ileum in Rats IMJ 20(4,) 232-234, 2013.
- [13] Ouzilou, L., Caliot, E., Pelletier, I., Prévost, M.-C., Pringault, E., and Colbère-Garapin, F. (2002). Poliovirus transcytosis through M-like cells. *J. Gen. Virol.* 83, 2177–2182.
- [14] de La Serre CB, Ellis CL, Lee J, Hartman AL, Rutledge JC, Raybould HE. Propensity to high-fat diet-induced obesity in rats is associated with changes in the gut microbiota and gut inflammation. *Am J Physiol Gastrointest Liver Physiol.* 2010 Aug; 299(2): G440-8. doi: 10.1152/ajpgi.00098.2010. Epub 2010 May 27.
- [15] Kucharzik T, Lügering A, Lügering N, Rautenberg K, Linnepe M, Cichon C, Reichelt R, Stoll R, Schmidt MA, Domschke W. Characterization of M cell development during indomethacin-induced ileitis in rats. *Aliment Pharmacol Ther* 2000, 14, 247-56.
- [16] Y Lee, C. (2013). The Effect of High-Fat Diet-Induced Pathophysiological Changes in the Gut on Obesity: What Should be the Ideal Treatment? *Clin. Transl. Gastroenterol.* 4, e39.